



## Case Report

# Rapid canine retraction in knife edge alveolar ridge by distraction of periodontal ligament in combination with alveolar ridge expansion- A case report

B.K. Rajkumar<sup>1,\*</sup>, S. Nagalakshmi<sup>1</sup>, K. Preethi<sup>1</sup>, A. Sasirekha<sup>1</sup>, S. Vinoth<sup>1</sup>

<sup>1</sup>Dept. of Orthodontics, Vivekanandha Dental College for Women, Elaiyampalayam, Tamil Nadu, India



## ARTICLE INFO

### Article history:

Received 02-03-2022

Accepted 31-03-2022

Available online 11-04-2022

### Keywords:

Rapid canine retraction; Piezocision

Periodontal ligament distraction

Regional acceleratory phenomenon

Knifeedge alveolar ridge

## ABSTRACT

This article describes a case report of a patient with knife edge alveolar ridge where orthodontic tooth movement was previously impossible into which rapid canine retraction for 8mm was done by use of a new technique of combining ridge split expansion with piezocision and thereby producing a regional acceleratory phenomenon and rapid canine retraction by custom made tooth borne distraction device.

This is an Open Access (OA) journal, and articles are distributed under the terms of the [Creative Commons Attribution-NonCommercial-ShareAlike 4.0 License](https://creativecommons.org/licenses/by-nc-sa/4.0/), which allows others to remix, tweak, and build upon the work non-commercially, as long as appropriate credit is given and the new creations are licensed under the identical terms.

For reprints contact: [reprint@ipinnovative.com](mailto:reprint@ipinnovative.com)

## 1. Introduction

In the late 1990's Wilcko brothers, developed the Accelerated Osteogenic Orthodontics (AOO) procedure and claimed that the orthodontic treatment time could be reduced by 75% in the majority of orthodontic cases by accelerating orthodontic tooth movement.<sup>1</sup> In 2009 Dibart<sup>2</sup> et al. described a new minimally invasive procedure Piezocision, which combines micro-incisions limited to the buccal gingiva that allow the use of a piezoelectric knife to give osseous cuts to the buccal cortex and initiate the regional acceleratory phenomenon (RAP).

Wilcko et al.<sup>3</sup>, claimed that accelerated tooth movement after corticotomy is a result of a physiological response of the bone, known as the regional acceleratory phenomenon, which is induced by bone damage. Sebaoun et al, suggested that alveolar decortication induces rapid and localized bone turnover and may be the main reason for accelerated tooth movement. Liou and Huang<sup>4</sup> suggested that rapid canine retraction could be achieved by distracting the periodontal ligament and undermining the

interseptal bone by bending the interseptal bone distal to the canine and move the canine into the first-premolar extraction site.

This article describes a patient treated with custom-made, rigid, segmental tooth-borne distraction device used to retract the canine by distraction of the periodontal ligament into premolar extracted site with knife edge alveolar ridge after ridge expansion with piezocision.

## 2. Diagnosis and Treatment Planning

A 25-year-old male presented with the complaint of crowded upper front teeth. On extra oral examination he exhibited a convex profile with prognathic maxilla (Figure 1). Intra oral examination revealed a class I canine relation, crowded upper and lower anterior teeth. There were missing teeth in relation to 24, 25, 26 region with a history of extraction before 3 years due to which there was a knife edge alveolar ridge in that region (Figure 1). Cephalometric analysis indicated that patient had a skeletal class II relationship with maxillary prognathism, low mandibular plane angle and proclination of the lower incisors (Table 1).

Treatment plan was to

\* Corresponding author.

E-mail address: [drbkrajumar2003@yahoo.co.in](mailto:drbkrajumar2003@yahoo.co.in) (B. K. Rajkumar).

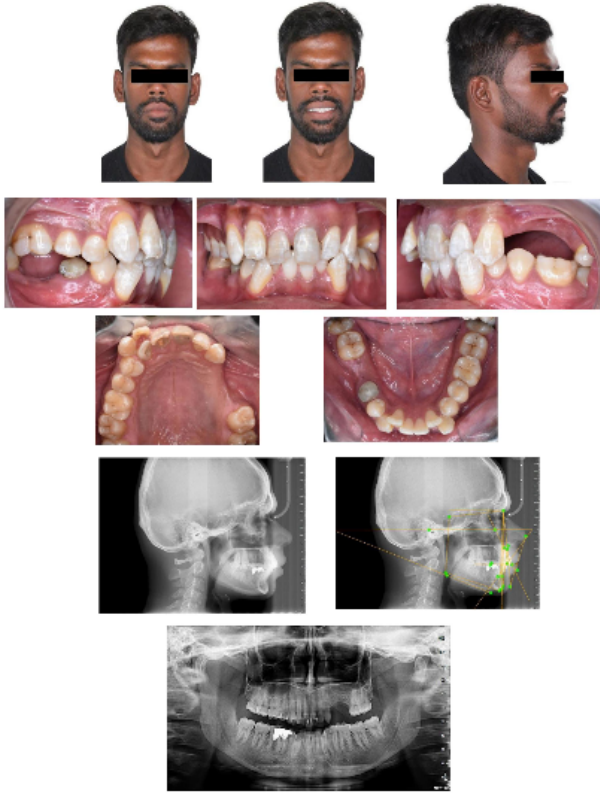


Fig. 1: Pretreatment record of patient

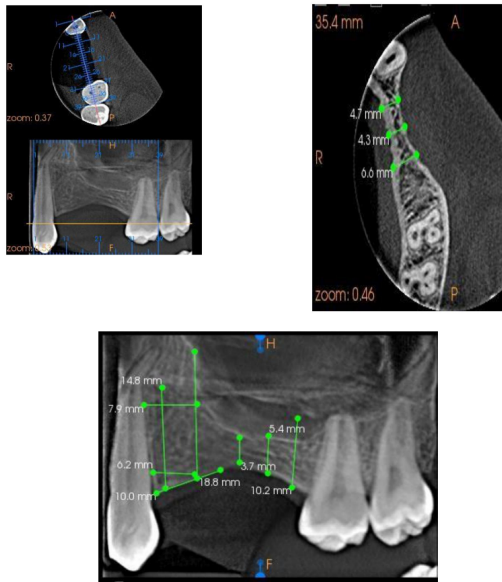


Fig. 2: Cone beam computed tomography (CBCT) images of patient

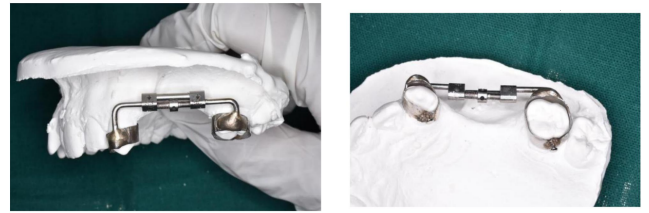


Fig. 3: Custom made distractor

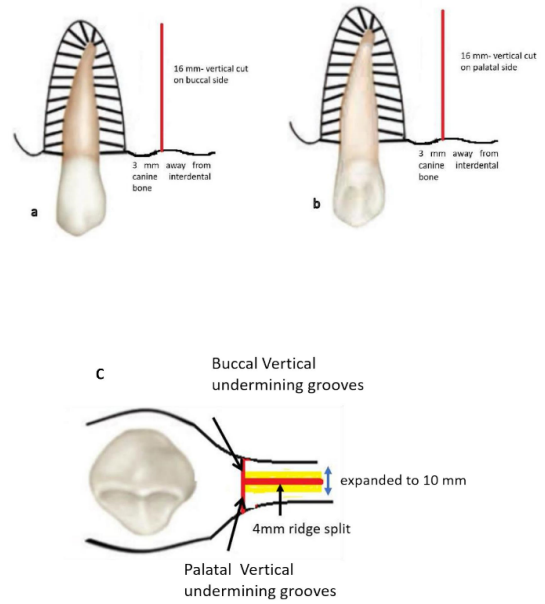


Fig. 4: a, b, c -Piezocision technique for undermining atrophic bone ridge distal to canine thick red lines represent cuts and yellow region shows expansion

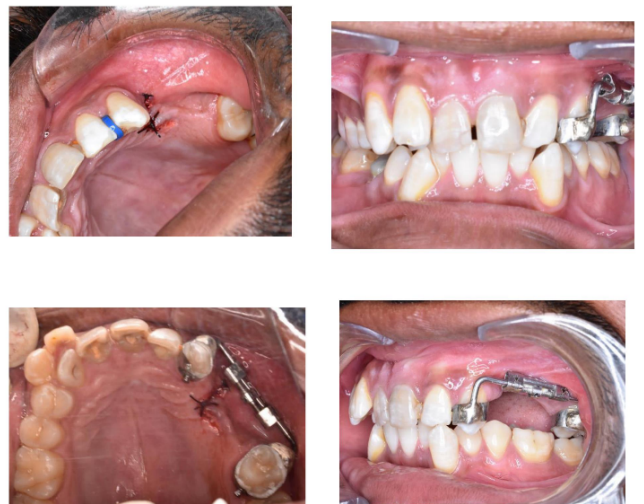
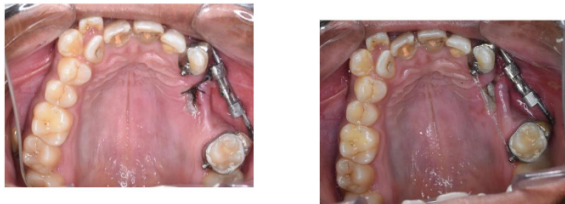
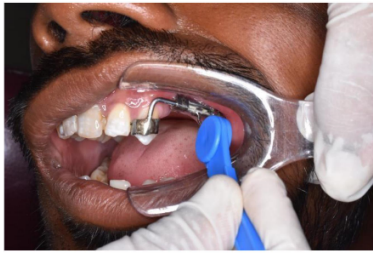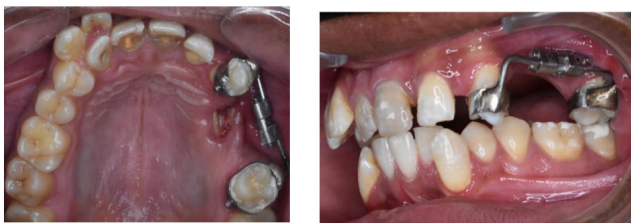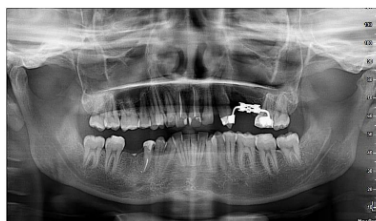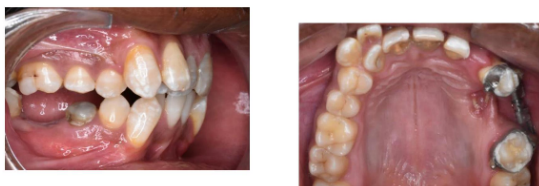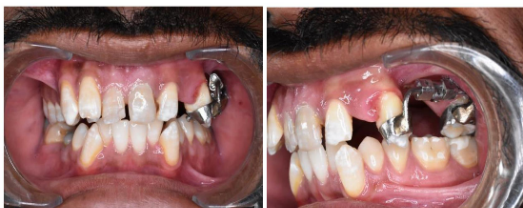Fig. 5: After ridge expansion and distractor



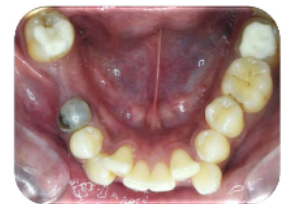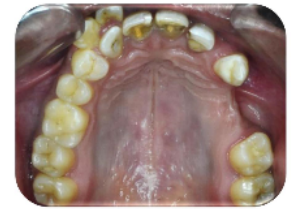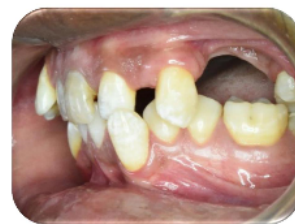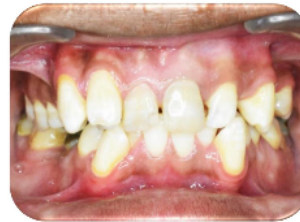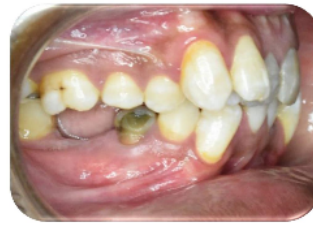**Fig. 6:** On the 3<sup>rd</sup> day during distraction device activation



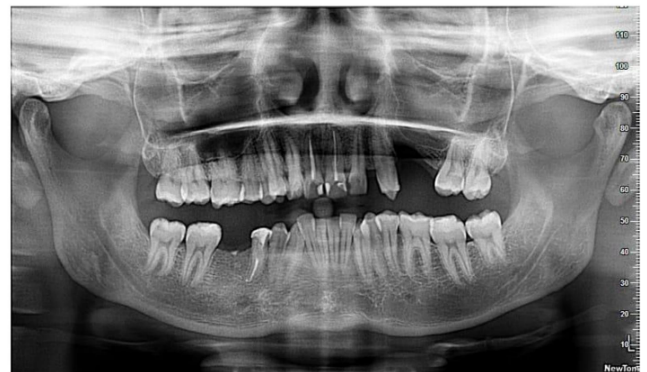**Fig. 7:** After 3 year weeks of distraction



**Fig. 8:** After 1 month distraction device activation



**Fig. 9:** Post-treatment intraoral photograph



**Fig. 10:** Post-distraction intraoral photograph Orthopantomograph

1. First retraction of 23 into 24 region
2. After, 23 retraction, extraction of other sides first premolars and start fixed appliance therapy to correct crowding.
3. Finally, after fixed appliance therapy, replacement of 25 and 26 was planned

Taking into consideration the anchorage demands, long span knife edge edentulous space in the second quadrant, we proposed the use of a distraction device to rapidly retract the left upper canine to the first premolar region after ridge expansion.

**Table 1:** Cephalometric variables

Parameters	Normal	Pre treatment
SNA	82+2 °	89.2°
	80+2 °	82.4
ANB	2 + 2 °	6.8°
Wits appraisal		6.7mm
U1-SN	70±5	109.1°
L1-MP	90±3	100.9°
U1-L1	135°	125.1°
PP-MP	25	19.5°
N-ANS	54 + 3mm	45.5mm
ANS-Gn	69 + 4mm	55.5 mm
Facial-height ratio	62-65%	70.1%
L1-APo	22±4°	22.9°
L1 to E-line	-2 to+2mm	2.8mm
FMA	25°	21.3°

### 2.1. Treatment progress

The tooth to be distracted was second quadrant canine and the second molar acts an anchor unit. The custom made distractor (Figure 3) was made according to design by Sukuricaet al.<sup>5</sup> and modified by soldering a 11mm expansion screw to bands on 23 and 27 on the buccal side and lingual buttons were welded on the lingual side for attachment of elastic chain to prevent unwanted rotation of canine and molar during distraction. Before placement of the distractor device we planned for ridge expansion of 10 mm in first premolar region due to reduced thickness of alveolar ridge in first premolar region which could not accommodate the canine. The protocol according to Mete Ozerfor implant placement was followed for ridge expansion.<sup>6</sup> Under Local Anaesthesia, crestal incision was performed from 23 to 26 region. Using piezoelectric device vertical osteotomy cuts were given 3mm distal to 23 to a planned height of 16mm grooving vertically along the buccal and lingual sides to facilitate distraction of canine. (Figure 4 a, b). Ridge split was carried out on the knife edge ridge for 4 mm and expansion was done for 10mm (Figure 4 c).

The expanded region was packed with osseomould bone graft to prevent approximation of expanded ridges. The graft was covered with a layer of plasma rich fibrin (PRF)<sup>7</sup> to increase the bone inductive and conductive activity. The custom-made distractor was fixed and left in place for 2 days (Figure 5). From third day the distractor device (Figures 6 and 7) was activated at the rate of 0.5mm per day (two quarter turns twice daily).<sup>4</sup> The distraction was carried out till canine was brought into the first premolar region (Figure 8), a total of 8 mm canine retraction was achieved. Elastic chain was attached between the lingual side of canine and second molar to prevent unwanted rotation of anchor tooth.

### 2.2. Treatment outcome

The canine was distracted and brought in to first premolar position, there were no visible color changes in the distracted as well as anchor teeth. The canine has tipped slightly after distraction. Although there was no bodily molar movement, there was slight tipping was seen (Figure 8). After 6 months the appliance was removed (Figure 9) and patient advised for further treatment with fixed appliance therapy. In post-treatment OPG parallelism of roots was almost achieved. (Figure 10)

### 3. Discussion

In this case, we have achieved rapid canine distraction through distraction of periodontal ligament along with ridge expansion. The lack of ridge preservation after extraction will lead to significant ridge atrophy, as such in our case. In this clinical case, there was an absence of both left maxillary premolars and the first permanent molar, which was utilized by moving the upper left canine to the interdental region between lower premolars. We have used piezoelectric surgical method for decortication because they are minimally invasive surgical techniques that offer less patient pain and acceptance.<sup>2</sup> This procedure is like intentional fracture which produces a regional acceleratory phenomenon that speeds up the bone remodelling process.<sup>8</sup> One animal study found that distraction of the periodontal ligament stimulated the expression of collagen I, collagen III, and matrix metalloproteinase-1 and thus promoted rebuilding of the ligament.<sup>9</sup> In our patient, the upper canine's periodontal ligaments were distracted by about 8mm in four weeks. Kharkar and colleagues preferred dentoalveolar distraction to periodontal distraction for rapid canine retraction because it avoided canine tipping.<sup>10</sup> In our patient the canine and molar tipping was avoided by placement of powerchain on the lingual side between canines and first molars. The distracted canines showed grade 1 mobility indicating tearing of periodontal ligament as demonstrated by Feng et al.<sup>11</sup>

### 4. Conclusion

This method of combining ridge expansion with use of distraction done was effective in moving the canine through atrophic ridges. Though the custom-made distractor was initially unesthetic and causes short term problems such as discomfort and chewing difficulty, the canine movement was rapid and effective. Hence, this technique can be effectively used in patients with knife-edge alveolar ridge who were difficult to treat previously with orthodontic treatment alone.

### 5. Source of Funding

None.

## 6. Conflict of Interest

None.

## References

- Mittal SK, Sharma R, Singla A. Piezocision assisted orthodontics: a new approach to accelerated orthodontic tooth movement. *J Innov Dent.* 2011;144(6):879–89. doi:10.1016/j.ajodo.2012.12.014.
- Dibart S, Sebaoun J, Surmenian J. Piezocision: A minimally invasive, periodontally accelerated orthodontic tooth movement procedure. *Compend Cont Ed Dent.* 2009;30(6):348–50.
- Wilcko MT, Wilcko WM, Bissada NF. An evidence- based analysis of periodontally accelerated orthodontic and osteogenic techniques: a synthesis of scientific perspectives. *Seminars Orthod.* 2008;14(4):305–21. doi:10.1053/j.sodo.2008.07.007.
- Eric JW. Rapid canine retraction through distraction of the periodontal ligament. *Am J Orthod Dentofac Orthop.* 1998;114(4):372–82. doi:10.1016/s0889-5406(98)70181-7.
- Sukurica Y, Karaman A, Gürel HG, Dolanmaz D. Rapid canine distalization through segmental alveolar distraction osteogenesis. *Angle Orthod.* 2007;77(2):226–62. doi:10.2319/0003-3219(2007)077[0226:RCDTSA]2.0.CO;2.
- Ozer M, Akdeniz BS, Sumer M. Alveolar ridge expansion-assisted orthodontic space closure in the mandibular posterior region. *Korean J Orthod.* 2013;43(6):302–10. doi:10.4041/kjod.2013.43.6.302.
- Choukrounj. PRF: An opportunity in perio-implantology” *Implantodontie*42; 2000. p. 55–62.
- Frost HM. The biology of fracture healing: An overview for clinicians, Part I. *Clin Orthop Relat Res.* 1989;248(5):283–93.
- Chen X, Li N, Yang L, Liu J, Chen J, Liu H. Expression of collagen I, collagen III and MMP-1 on the tension side of distracted-tooth using periodontal ligament distraction osteogenesis in beagle dogs. *Arch Oral Biol.* 2014;59(11):1217–25. doi:10.1016/j.archoralbio.2014.07.011.
- Kharkar VR, Kotrashetti SM, Kulkarni P. Comparative evaluation of dento-alveolar distraction and periodontal distraction assisted rapid retraction of the maxillary canine: A pilot study. *Int J Oral Maxillofac Surg.* 2010;39(11):1074–9. doi:10.1016/j.ijom.2010.06.012.
- Xiao XF. Rapid Canine Retraction by Distraction of the Periodontal Ligament. *JCO.* 2016;50(3):179–88.

## Author biography

**B.K. Rajkumar**, Professor  <https://orcid.org/0000-0003-4110-3201>

**S. Nagalakshmi**, Professor and Head

**K. Preethi**, Senior Lecturer

**A. Sasirekha**, Private Practitioner

**S. Vinoth**, Reader

**Cite this article:** Rajkumar BK, Nagalakshmi S, Preethi K, Sasirekha A, Vinoth S. Rapid canine retraction in knife edge alveolar ridge by distraction of periodontal ligament in combination with alveolar ridge expansion- A case report. *J Contemp Orthod* 2022;6(1):29-33.