

Long term comparison of dentoskeletal stability of Class II patients treated with functional appliances and mandibular advancement surgery: A cephalometric study.

To cite: Jasleen Kaur, Shравan Kumar, K. Sadashiva Shetty, Chandan Kumar

Long term comparison of dentoskeletal stability of Class II patients treated with functional appliances and mandibular advancement surgery: A cephalometric study.

J Contemp Orthod 2021;5(2): 39-45.

Received on: 14-07-2021

Accepted on: 12-08-2021

Source of Support: Nil

Conflict of Interest: None

¹Jasleen Kaur, ²Shравan Kumar, ³K. Sadashiva Shetty, ⁴Chandan Kumar

¹Associate Professor, Department of Orthodontics, Himachal Institute of Dental Sciences, Paonta Sahib, Distt.- Sirmaur, H.P.

²Registrar Orthodontics, Q8 Dental center, Farwaniya, Kuwait.

³Head of Department, Department of Orthodontics, Bapuji Dental College and Hospital, Davangere, Karnataka.

⁴Consultant Orthodontist, Sitamarhi, Bihar.

ABSTRACT

Objective: The aim of this study was to compare the stability of dentoskeletal parameters of Class II patients treated with either functional appliances or mandibular advancement surgery.

Materials and Methods: The study consisted of two groups: Group I - 10 growing patients treated with removable functional appliances and Group II - 10 non growing patients treated with surgical mandibular advancement. Dentoskeletal changes that occurred were compared on lateral cephalograms taken at three points of time: Pre treatment (T1), post treatment (T2) and long term post treatment (T3).

Results: Both functional appliances and surgical patients showed stable results over time. Small amount of relapse was observed in surgical patients from post surgical (T2) to long term post surgical (T3) which was statistically insignificant. **Conclusion:** Both functional appliances and mandibular advancement surgery can be used successfully for the correction of Class II malocclusion.

Keywords: Functional appliances, mandibular advancement surgery, mandibular retrognathism, stability..

INTRODUCTION

Skeletal Class II malocclusion due to mandibular retrognathism is one of the most common type of malocclusion. There are various treatment approaches for correction of mandibular retrognathism like growth modification in growing patients and orthognathic surgeries in adult patients. Functional appliances attempt to correct the sagittal abnormality by posturing the mandible forwards. The primary objective is to eliminate the deforming neuromuscular activity which has a retrusive effect on the mandible.^{1, 2} Some authors have described a long-term statistically significant increase in mandibular length in patients treated with functional appliances³ while others have reported a lack of significant changes of treated Class II subjects in the long term.⁴

In 1955, Obswegeser and Trauner described a surgical procedure involving a sagittal split osteotomy through the ramus of mandible. Despite its popularity, however, one factor still remains a major concern: its potential for relapse. Various reports indicate that the relapse seen after mandibular

advancement surgery is the result of paramandibular connective tissue tension, lack of control of the proximal segment during surgery, condylar distraction, inadequate fixation, magnitude of advancement, unfavorable growth post surgically, and preexisting internal derangement of the temporomandibular joints.⁵⁻⁸

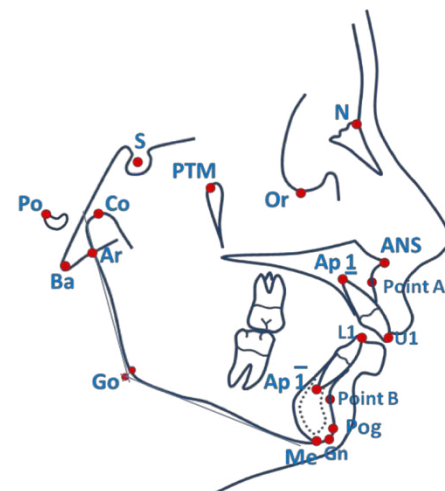


Figure 1. Cephalometric landmarks used in study

The long term effects of both of these interventions, however, remain controversial and open to question. Therefore, the aim of the present study was to evaluate the long term comparison

treatment duration for wearing of functional appliances was 1 year 8 months. Lateral cephalograms were taken at following three points of time: Pretreatment – T1, Post Functional – T2,

Table I. Comparison of Angular Parameters – Removable Functional Appliances

Functional Appliances	T1		T2		T3		ANOVA
Angular Parameters (degrees)	Mean	SD	Mean	SD	Mean	SD	P value
SNA	81.2	2.5	80.2	2.7	79.8	2.7	0.48, NS
SNB	74.3	2.5	76.7	2.5	77.3	2.6	0.03, S
ANB	6.9	0.7	3.5	1.0	2.5	1.2	< 0.001, HS
Mandibular plane angle	30.0	4.4	29.3	4.1	28.7	3.8	0.78, NS
Angle of convexity	12.1	2.7	7.6	3.2	5.9	2.4	< 0.001, HS
Facial axis angle	-2.3	3.3	-1.3	3.5	-1.0	3.5	0.68, NS
Upper incisor to SN plane angle	112.7	5.6	109.5	5.5	111.2	3.6	0.37, NS
Lower incisor to Mand plane angle	101.9	3.6	104.3	2.9	107.0	2.8	0.004, S
Repeated Measures ANOVA	P =/ < 0.05, S (Significant)		P =/ < 0.001, HS (Highly significant)		P =/ > 0.05, NS (Not significant)		

of dentoskeletal stability of Class II patients treated with removable functional appliances and bilateral sagittal split ramus osteotomy with mandibular advancement.

MATERIALS AND METHODS

Pre treatment, post treatment and long term post treatment lateral cephalograms of patients with skeletal Class II malocclusion due to mandibular retrognathism treated with removable functional appliances (twin block or frankel II appliance) and surgical mandibular advancement were collected from the record section of the Department of Orthodontics and Dentofacial Orthopedics, Bapuji Dental College and Hospital, Davangere. Sample size consisted of 20 skeletal Class II malocclusion patients. Inclusion criteria used: Skeletal Class II malocclusion due to mandibular retrognathism, ANB more than 4°, overjet greater than 5mm, no history of previous orthodontic treatment.

Sample was divided into two groups-

Group I - 10 growing patients (5 boys, 5 girls) with mean age of 11 years (range 8 to 14 years) treated with twin block or frankel II appliance. In patients treated with frankel appliance stepwise advancement of the mandible was done. Average

Long term Post Functional – T3 (Taken at least 15 months after post functional phase which also included the period of fixed line of treatment).

Group II - 10 non-growing patients (4 males, 6 females) with mean age of 24 years (range 21 to 27 years) treated with bilateral sagittal split osteotomy with mandibular advancement. All patients in this group were having low mandibular plane angle with reduced lower anterior facial height at the beginning. No genioplasty or any adjunctive surgery had been performed. Stabilization was done with internal rigid fixation for all the patients. Lateral cephalograms were taken at following three point of time: Pretreatment – T1, Post Surgical – T2, Long term Post Surgical – T3 (Taken at least 15 months after surgery).

All 20 patients were treated with non extraction fixed appliance therapy with 0.022" MBT prescription. In functional appliance group, after the completion of Phase I therapy, fixed line of treatment was started. Average total time duration from pre treatment to long term post treatment was 49 months and 47 months in Group I and Group II respectively.

Lateral cephalograms were taken with teeth in occlusion and relaxed lips under standardized conditions with a cephalostat.

Lateral cephalograms were standardized for magnification and manually traced by one author (J.K.) and checked by second author (S.K.) to ensure consistency of cephalometric landmarks (Figure1). Eight angular parameters and ten linear parameters were used in the study.

of the appliances from T2 to T3. There was statistically significant increase in N perp to pogonion, lower anterior facial height, length of mandibular body, length of mandibular ramus, SNB value and lower incisor proclination from T1 to T3.

Group II – Angular and linear parameters of surgical group at

Table II. Comparison of Linear Parameters – Removable Functional Appliances

Functional Appliances	T1		T2		T3		ANOVA
	Mean	SD	Mean	SD	Mean	SD	P value
N perp to Point A	-0.8	2.3	-1.3	2.4	-1.6	2.4	0.75, NS
N perp to Pogonion	-11.9	4.3	-7.9	4.0	-6.5	4.7	0.03, S
Effective maxillary length	85.3	3.3	86.2	3.4	87.2	3.4	0.46, NS
Effective mandibular length	101.0	4.4	107.2	5.4	110.4	5.2	0.001, S
Lower anterior facial height	57.8	4.2	60.6	4.1	62.9	4.5	0.04, S
Length of mandibular body	67.5	4.8	71.6	4.6	74.1	4.4	0.01, S
Length of mandibular ramus	42.3	3.3	45.1	4.0	46.7	4.3	0.05, S
Overjet	8.9	1.4	4.5	1.4	2.8	0.6	< 0.001, HS
Overbite	4.8	0.4	3.0	0.5	2.2	0.4	< 0.001, HS
Jarabak's ratio (%)	66.9	2.9	68.2	3.2	69.2	3.4	0.28, NS
Repeated Measures ANOVA	P ≤ 0.05, S (Significant)		P < 0.001, HS (Highly significant)		P > 0.05, NS (Not significant)		

Statistical analysis - Intragroup comparison was done by using Repeated Measures ANOVA. Intergroup comparison was done using unpaired t-test. A 'P' value of 0.05 or less was considered for the differences to be statistically significant. A 'P' value of less than 0.001 was considered for the differences to be highly significant.

RESULTS

Group I – Angular and linear parameters of functional appliance group at T1, T2 and T3 are shown in Tables I and II. Cephalometric values before (T1) and after functional appliance treatment (T2) showed statistically significant improvement in sagittal jaw relationship. This was evident from the following results: angle of convexity reduced from 12.1° to 7.6°, increase in effective mandibular length from 101.0mm to 107.2mm. Highly significant decrease in ANB angle, overjet and overbite was also observed from T1 to T2 which continue to decrease from T2 to T3. Mandible continue to grow in a favourable manner even after the discontinuation

T1, T2 and T3 are shown in Tables III and IV. There was a statistically significant increase in the mean values of SNB from 77.7° to 82.0°, N perp to pogonion from -7.4mm to -2.0mm, effective mandibular length from 115.6mm to 121.2mm from T1 to T2. Angle of convexity and upper incisor to SN plane angle decreased significantly from 5.7° to 0.2° and 121.3° to 113.7° respectively from T1 to T2. Highly significant decrease in ANB angle, overjet and overbite was also observed from T1 to T2. Mandibular plane angle increased significantly from 20.8° to 25.3° and Jarabak's ratio decreased significantly from 75.9 percent to 71.3 percent from T1 to T3. Small amount of relapse was observed in surgical patients from post surgical to long term post surgical which was not statistically significant.

Inter group comparison

Most of the pretreatment linear values were larger in the surgical group than functional appliance group as all non growing patients had been included in surgical group. Mean SNA value decreased slightly in group I whereas no effect in group II. Length of mandibular ramus increased significantly in group I

unlike in group II where this value decreased slightly. Mandibular plane angle increased and Jarabak's ratio decreased significantly in group II. Lower incisors were significantly proclined in group I whereas in group II showed

This study also showed increased mandibular growth even after the cessation of phase I treatment. A similar trend was noted by other studies.^{9,17,18} Faltin et al reported that significant long term changes in the occlusal relationships and mandibular growth can

Table III. Comparison of Angular Parameters – Mandibular Advancement Surgery

Mand. Advancement Surgery	T1		T2		T3		ANOVA
Angular Parameters (degrees)	Mean	SD	Mean	SD	Mean	SD	P value
SNA	83.3	3.3	83.3	3.3	83.3	3.3	1.00, NS
SNB	77.7	3.1	82.0	2.9	81.7	2.9	0.005, S
ANB	5.6	0.7	1.3	1.2	1.6	1.2	<0.001, HS
Mandibular plane angle	20.8	4.3	24.6	4.1	25.3	4.4	0.05, S
Angle of convexity	5.7	3.5	0.2	4.0	0.8	3.8	0.005, S
Facial axis angle	2.2	3.4	1.8	3.1	1.9	3.1	0.96, NS
Upper incisor to SN plane angle	121.3	5.1	113.7	4.9	114.3	5.1	0.003, S
Lower incisor to Mand plane angle	106.6	7.0	103.4	7.2	101.4	5.2	0.31, NS
Repeated Measures ANOVA	P ≤ 0.05, S (Significant)		P < 0.001, HS (Highly significant)		P > 0.05, NS (Not significant)		

retroclination although not significantly. Changes in group II occurred solely due to treatment, whereas in group I the changes were due to growth also. Mild relapse had been observed in dental and skeletal parameters from T2 to T3 in group II which was not statistically significant. In functional appliance group, the mandible continued to grow in a favourable manner even after the cessation of phase I treatment (from T2 to T3).

DISCUSSION

Changes in the functional appliance group (Group I)- Statistically significant increase in effective mandibular length, length of mandibular body, forward movement of pogonion point and increase in SNB value was noted. These results are supported by other studies.⁹⁻¹² In contrast, some investigations reported that mandibular condylar growth is not influenced by functional appliance therapy.¹³⁻¹⁶ Harvold indicated that therapeutic changes were due to maxillary growth inhibition rather than mandibular growth stimulation.¹³ Weislander found that effect of treatment was usually of dentoalveolar origin with a major favourable change in the position of upper incisors and orthopedic effect with functional appliance was limited.¹⁴

be achieved only when functional treatment includes pubertal growth spurt.¹⁷ Johnston et al reported that mandibular effects do not “evaporate” when FR -2 is used and the results are supported by postfunctional orthodontics.¹⁸ Patients in the present study underwent second phase of treatment with fixed mechanotherapy designed to refine the occlusion. These supplemental treatments may well be responsible for the apparent stability of results along with correct treatment timing of functional appliances involving pubertal growth spurts and finally most important patient compliance.

Patients in this group experienced a mild inhibition of forward maxillary growth as evidenced by the backward movement of Point A and reduction seen in SNA angle. This indicates little maxillary growth restraint or minimal “headgear like” effect of functional appliances. This phenomenon was described by Owen.¹⁹ There was significant reduction noted in ANB angle and angle of convexity. This reduction was due to forward growth of the mandible and mild restraining effect on maxilla. These values continued to decrease from T2 to T3.

The vertical dimension increased as the mandible continued to grow downward and forward as noted by increase in lower anterior facial height. This result was

probably related to posterior bite opening that occurs when the mandible was brought forwards and the molars were

region. This allowed a greater vertical increase in lower posterior teeth and helped in correcting the overbite. Mild proclination of

Table IV. Comparison of Linear Parameters – Mandibular Advancement Surgery

Mand. Advancement Surgery	T1		T2		T3		ANOVA
Linear Parameters (mm)	Mean	SD	Mean	SD	Mean	SD	P value
N perp to Point A	-1.4	2.1	-1.4	2.1	-1.4	2.1	1.00, NS
N perp to Pogonion	-7.4	3.1	-2.0	3.9	-2.2	4.1	0.004, S
Effective maxillary length	93.0	5.0	93.3	5.0	93.3	5.0	0.99, NS
Effective mandibular length	115.6	4.9	121.2	5.1	121.2	5.1	0.03, S
Lower anterior facial height	61.6	4.1	65.4	4.2	65.2	4.3	0.10, NS
Length of mandibular body	79.1	4.9	83.6	5.3	83.5	5.2	0.10, NS
Length of mandibular ramus	53.5	5.5	52.4	5.6	51.6	5.7	0.75, NS
Overjet	9.6	2.3	2.2	1.1	2.4	0.7	<0.001, HS
Overbite	5.9	1.3	1.6	1.1	2.3	0.8	<0.001, HS
Jarabak's ratio (%)	75.9	4.4	72.1	4.2	71.3	4.2	0.05, S
Repeated Measures ANOVA	P ≤ 0.05, S (Significant)		P < 0.001, HS (Highly significant)		P > 0.05, NS (Not significant)		

encouraged to erupt. Toth and McNamara pointed that, “every millimetre of increased lower anterior facial height camouflages a millimetre of mandibular length increase causing the chin to rotate downward and backward”.²⁰ But in the present study although increase in lower anterior facial height was observed, there was slight reduction in mandibular plane angle and closing of facial axis angle. This may be due to equal increase in posterior facial height due to ramal growth. As a result of the observed interplay of both the anterior and posterior facial heights, the mandibular plane angle was not affected and the tendency for the mandible to rotate downwards and backwards was not seen. Similar findings were reported in studies by Mills and McCulloch²¹, Almeida et al²².

Overjet was reduced by combination of mild maxillary incisor retroclination, mandibular incisor proclination, forward movement of mandible and mild maxillary growth restraint. Pancherz found that more than 50% of the overjet correction was produced by upper incisor tipping.¹⁶ Advancement of the mandible also contributed to opening of bite in posterior

upper incisors was noted from T2 to T3. This could be due to the effect of comprehensive fixed mechanotherapy. Lower incisors proclination was observed in the study. This effect was due to the resultant mesial force on the lower incisors induced by the protrusion of mandible.

Changes in the surgical group (Group II) - As all the patients in this group were nongrowing, the changes recorded were solely due to treatment. Statistically significant increase in effective mandibular length, SNB value and forward movement of pogonion point was noted.

Mild relapse has been observed in this study in mandibular skeletal parameters from postsurgical to long term post surgical (T2 to T3) period which could be due to post operative occlusal settling. According to Lake et al surgical lengthening of the mandible was primarily achieved by an anteroinferior advancement of the distal mandibular segment and the concomitant anterosuperior rotation of the proximal segment. As the magnitude of advancement increased, the net amount of relapse tended to increase.⁷ According to Joss and Thuer the

relapse was most likely due to incomplete setting of condyles in the fossa before fixation of the proximal segment. The manipulation of these segments is difficult, especially in large advancements where the soft tissues become considerably stretched.²³ In contrast to this, studies by Pangrazio-Kulbersh et al²⁴, Kierl et al⁸ do not support long term stability of surgical mandibular advancement.

There was significant reduction noted in ANB angle and angle of convexity. This reduction was only due to forward movement of the mandible as surgery had not caused any change on maxilla. Mild relapse was noted in these parameters from T2 to T3.

The vertical dimension increased as noted by the increase in lower anterior facial height and mandibular plane angle. This could be explained by the fact that the sample for the present study consisted of low to average mandibular plane angle with deep bite and decreased lower face height. Mild relapse has been observed in this study in lower anterior facial height from postsurgical to long term post surgical (T2 to T3) period. According to Gomes et al the decrease of anterior facial height may be the result of remodeling of the inferior mandibular border and a counterclockwise rotation of distal segment.²⁶

Statistically significant decrease in overjet and overbite from T1 to T2 is noted. A similar trend was noted by Lake et al⁷, Dolce et al²⁷, Berger et al⁹. In a study done by Berger et al, initially the overjet was increased before surgery as the decompensation of the incisors was being performed.⁹ But in the present study all the cases were treated with nonextraction treatment modality without decompensation of incisors and overjet was maintained before surgery. As the mandible has been advanced forwards and downwards, a significant reduction in overjet and overbite was noted. Mild relapse has been observed in this study in overjet and overbite from postsurgical to long term post surgical (T2 to T3) period.

CONCLUSIONS

1. Both functional appliances and mandibular advancement surgery can be used successfully for the correction of Class II malocclusion.
2. Significant amount of skeletal and dental changes were noticed in both treatment groups.
3. In functional appliance patients it was observed that mandible continued to grow in a favorable direction even after cessation of phase I treatment.
4. Both functional appliance and surgical patients showed stable results over time. Small amount of relapse was observed in surgical patients from post surgical to long term post surgical which was not statistically significant.

REFERENCES

1. Graber TM, Rakosi T, Petrovic AG, 1st ed. Dentofacial Orthopedics with functional appliances. St. Louis : Mosby, 1985.
2. Cozza P , De Toffol L, Colagrossi S. Dentoskeletal effects and facial profile changes during activator therapy. Eur J Orthod 2004; 26: 293-302.
3. Freeman DC, McNamara JA Jr, Baccetti T, Franchi L, Frankel C. Long-term treatment effects of the FR-2 appliance of Frankel. Am J Orthod Dentofacial Orthop 2009; 135: 570.e1-6.
4. Hansen K, Pancherz H. Long-term effects of Herbst treatment in relation to normal growth development: a cephalometric study. Eur J Orthod 1992; 14: 285-295.
5. Will LA, West RA. Factors influencing the stability of the sagittal split osteotomy for mandibular advancement. J Oral Maxillofac Surg 1989; 47: 813-818.
6. Douma E, Kuflinec MM, Moshiri F. A comparative study of stability after mandibular advancement surgery. Am J Orthod Dentofacial Orthop. 1991; 100: 141- 155.
7. Lake SL, McNeill RW, Little RM, West RA. Surgical mandibular advancement: a cephalometric analysis of treatment response. Am J Orthod 1981; 80: 376-394.
8. Kierl MJ, Nanda RS, Currier GF. A 3-year evaluation of skeletal stability of mandibular advancement with rigid fixation. J Oral Maxillofac Surgery. 1990; 48: 587-592.
9. Berger JL, Pangrazio-Kulbersh V, George C, Kaczynski R. Long-term treatment outcome and stability of class II patients treated with functional appliances versus bilateral sagittal split ramus osteotomy. Am J Orthod Dentofacial Orthop. 2005; 127:451- 464.
10. Lund DL, Sandler PJ. The effects of twin blocks: A prospective study. Am J Orthod Dentofacial Orthop. 1998; 113:104 -110.
11. Franchi L, Pavoni C, Faltin K Jr, McNamara JA Jr, Cozza P. Long-term skeletal and dental effects and treatment timing for functional appliances in Class II malocclusion. Angle Orthod. 2013; 83: 334-340.
12. McNamara JA Jr, Bookstein FL, Shaughnessy TG. Skeletal and dental changes following functional regulator therapy on class II patients. Am J Orthod. 1985;88: 91-110.
13. Harvold EP and Vargervik. Morphogenetic response to activator treatment. Am J Orthod. 1971; 60: 478- 490.
14. Weislander L and Lagerstrom L. The effect of activator treatment on Class II malocclusions. Am J Orthod. 1979; 75:20- 26.

15. Gianelly AA, Brosnan P, Martignoni M, L Bernstein. Mandibular growth, condyle position and Frankel Appliance therapy. *Angle Orthod.* 1983; 53: 131–142.
16. Pancherz H. A cephalometric analysis of skeletal and dental changes contributing to Class II correction in activator treatment. *Am J Orthod.* 1984; 85:125- 133.
17. Faltin K Jr, Faltin RM, Baccetti T, Franchi L, Ghiozzi B, McNamara JA Jr. Long-term Effectiveness and Treatment Timing for Bionator Therapy. *Angle Orthod* 2003; 73: 221–230.
18. Perillo L, Johnston LE Jr, Ferro A. Permanence of skeletal changes after function regulator (FR-2) treatment of patients with retrusive Class II malocclusions. *Am J Orthod Dentofacial Orthop.* 1996; 109: 132-139.
19. Owen AH. Morphologic changes in the sagittal dimension using the Frankel appliance. *Am J Orthod.* 1981; 80: 573- 603.
20. Toth LR, McNamara JA Jr. Treatment effects produced by the twin-block appliance and the FR-2 appliance of Frankel compared with an untreated Class II sample. *Am J Orthod Dentofacial Orthop.* 1999; 116: 597- 609.
21. Mills CM, McCulloch KJ. Treatment effects of the twin block appliance: A cephalometric study. *Am J Orthod Dentofacial Orthop.* 1998; 114: 15-24.
22. De Almeida MR, Henriques JF, Ursi W. Comparative study of the Frankel (FR-2) and bionator appliances in the treatment of Class II malocclusion. *Am J Orthod Dentofacial Orthop.* 2002; 121: 458- 466.
23. Joss CU, Thuer VW. Stability of the hard and soft tissue profile after mandibular advancement in sagittal split osteotomies: a longitudinal and long-term follow-up study. *Eur J Orthod.* 2008; 30: 16–23.
24. Berger JL, Pangrazio-Kulbersh V, Bacchus SN, Kaczynski R. Stability of bilateral sagittal split ramus osteotomy: rigid fixation versus transosseous wiring. *Am J Orthod Dentofacial Orthop* 2000; 118:397- 403.
25. De Coul FO, Oosterkamp BC, Jansma J, Bierman MW, Pruijm GJ, Sandham A. Maintenance of a deep bite prior to surgical mandibular advancement. *Eur J Orthod.* 2010; 3: 342-345.
26. Gomes MA, Wisth PJ, Tornes K, Boe OE. Skeletofacial changes by mandibular advancement using sagittal split osteotomies. *Int J Adult Orthodon Orthognath Surg.* 1993; 8: 87-94.
27. Dolce C, Hatch JP, Van Sickels JE, Rugh JD. Rigid versus wire fixation for mandibular advancement: Skeletal and dental changes after 5 years. *Am J Orthod Dentofacial Orthop.* 2002; 121: 610 - 619.