



## Original Research Article

## Effect of systemic administration of recombinant growth hormone on rotator cuff repair a rat model study

Dheeraj Makkar<sup>1</sup>, Sangh Hoon Lee<sup>2,\*</sup><sup>1</sup>Dept. of Orthopedic, NC Medical Collage, Panipat, Haryana, India<sup>2</sup>Dept. of Orthopedic, Konkuk University, Seoul, South Korea

## ARTICLE INFO

## Article history:

Received 04-03-2022

Accepted 05-03-2022

Available online 16-03-2022

## Keywords:

Rotator Cuff

Recombinant

Growth Hormone

Collagen 1 and 3

## ABSTRACT

**Introduction:** Shoulder rotator cuff injuries are prevalent among the elderly. Rotator cuff tears, like osteoarthritis, are an inevitable aspect of aging. The only difference is that soft tissue rather than cartilage is involved in the degenerative process.

We hypothesized that exogenous systemic administration of recombinant growth hormone would increase the concentration of various growth factors involved in rotator cuff healing,

**Material and Methods:** Forty-eight Sprague-Dawley rats (Charles River, male, 400–450 g) were subjected to unilateral detachment repair of the supraspinatus and infraspinatus tendons at Konkuk University per Institutional Animal Care Committee recommendations.

The rats were divided in two groups one were injected with recombinant GH and controls. Initially an artificial rotator cuff tear was created and later repaired with vicryl 4-0. The animals were sacrificed at 1, 3, 6, and 12 weeks. The rotator cuff was removed enmasse. Both groups were compared histologically and immunologically for collagen 1 and 3. Statistical analysis between both the groups was done using SPSS software.

**Conclusion:** The recombinant GH helped in early healing of rotator cuff tears if injected systemically. More clinical trials need to be done before the exact dose can be determined for humans.

This is an Open Access (OA) journal, and articles are distributed under the terms of the [Creative Commons Attribution-NonCommercial-ShareAlike 4.0 License](https://creativecommons.org/licenses/by-nc-sa/4.0/), which allows others to remix, tweak, and build upon the work non-commercially, as long as appropriate credit is given and the new creations are licensed under the identical terms.

For reprints contact: [reprint@ipinnovative.com](mailto:reprint@ipinnovative.com)

## 1. Introduction

Rotator cuff tears in the shoulder are common among the elderly.<sup>1</sup> Rotator cuff tears, like osteoarthritis, are a natural part of the aging process. The only distinction is that soft tissue is involved in the degenerative process rather than cartilage. The treatment modalities for rotator cuff tears have evolved, with arthroscopic repair currently being the gold standard. Despite breakthroughs in repair technique, material selection, and a greater understanding of bone and soft tissue physiology, the failure rate for the large rotator cuff and tissues with poor quality restoration remains significantly higher.<sup>2</sup> The formation of fibrous scar

tissue in healthy regenerating tissue is the most plausible explanation for the high failure rate. Because fibrous scar tissue has inferior mechanical and physiological properties to normal tissue, the repaired tissue tends to re-tear despite the successful biomechanical restoration.<sup>2–5</sup> The presence of growth factors in the blood promotes tendon repair. Each growth factor contributes something unique to the healing process. Thus, by increasing the local availability of numerous growth agents, the quality of the restored tissue can be considerably improved.<sup>6–8</sup> Therefore, biologic therapy can significantly reduce the risk of rotator cuff re-tear by inhibiting the creation of fibrous scar tissue at the repair site and favoring the regeneration of normal scar tissue.<sup>9</sup> Prior research has concentrated on the topical

\* Corresponding author.

E-mail address: [makkardheeraj@gmail.com](mailto:makkardheeraj@gmail.com) (S. H. Lee).

delivery of growth factors at the repair site. Systemic growth factors may be a more effective technique of boosting healing rates by reducing drug waste during distribution and limiting loss owing to poor absorption. Numerous animals have been investigated to develop an appropriate experimental model that is simple to maintain, affordable, and similar to humans. Previous studies have demonstrated that the rat is an acceptable model for rotator cuff research since the rat shoulder's bony architecture possesses a coracoacromial arch, which makes it equivalent to the human shoulder among all other available experimental animals.<sup>10,11</sup>

We hypothesized that exogenous systemic administration of recombinant growth hormone would increase the concentration of various growth factors involved in rotator cuff healing, resulting in faster restoration to normal integrity and improved biochemical and histological characteristics of the repaired supraspinatus and infraspinatus tendons in the rat model.

As a result, the goal of this study was to use this well-established rat model to investigate the effect of systemic growth hormone injection on the repair of rotator cuff tears.

## 2. Materials and Methods


Forty-eight Sprague-Dawley rats (Charles River, male, 400-450 g) underwent unilateral detachment repair of the supraspinatus and infraspinatus tendons Konkuk University as per guidelines of the Institutional Animal Care Committee. Rats underwent general anesthesia with 2% isoflurane with oxygen.

### 2.1. Detachment technique

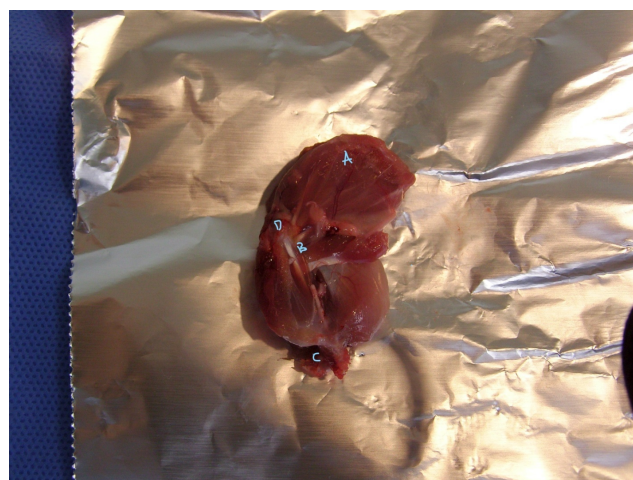
This study did not use randomization from left to right sides because rats, being quadrupeds, do not preferentially use their left or right forelimbs during daily activities. After delivering general anesthesia, a no.15 scalpel was used to make a 1.5cm longitudinal incision on the anterolateral portion of the shoulder(Figure 1). The deltoid was first divided bluntly and then severed from the acromial attachment to expose the supraspinatus and infraspinatus tendons(Figure 2). A 4-0 nylon suture was placed through each of the tendons to aid in reattaching them to bone. The supraspinatus and infraspinatus tendons were then severed on the greater tuberosity from their insertions. The underlying greater tuberosity was decorticated in the same manner as open transosseous repair is performed in humans.

### 2.2. Repair technique

Simple sutures were placed into the supraspinatus and infraspinatus tendons using No. 4-0 Vicryl (Ethicon, Somerville, NJ), similar to those used in the transosseous repair. Bone tunnels were made with a 22-gauge needle



**Fig. 1:** General anesthesia set up for rats.



**Fig. 2:** a) Deltoid with clavicle and acromion process b) biceps c) humerus d) rotator cuff.

at the corresponding locations of the tendons' imprints, 2 mm from the articular surface, and tag sutures removed. Sutures were then threaded through the tunnels and secured over a bone bridge on the lateral cortex of the humerus. The wound was stitched together in layers. Postoperatively, weight-bearing exercises were permitted ad libitum. At 1, 3, 6, and 12 weeks, twenty-four animals in each group were sacrificed.

### 2.3. Post-op regime

Pre-operatively, animals were randomized to either the experimental group, which received injections of the experimental drug, recombinant growth hormone (rGH), or the control group, which underwent detachment and repair only. Twenty-four animals received recombinant growth hormone subcutaneously at a 1 mg/kg/week dose. Based on previous studies, the first dose was given the day after

surgery (postoperative day 1 based on previous studies. The rGH injections were administered every week till the animal was sacrificed.

#### 2.4. Muscle harvest

In this investigation, animals were sacrificed at 1, 3, 6, and 12 weeks of age for analysis. Following inhalational carbon dioxide euthanasia, all animals underwent en masse dissection of the humerus and scapula specimens, leaving the reconstructed rotator cuff tendons intact.

#### 2.5. Histology

For specimens undergoing histologic investigation, the dissected humerus supraspinatus and infraspinatus tendons were preserved in 10% neutral-buffered formalin, decalcified with Immunocal (Decal) Congers, NY), and embedded in paraffin. In the coronal plane, five-micrometer-thick sections were cut through the repaired supraspinatus, infraspinatus, and greater tuberosity tendons. After that, the slides were alternately stained with H&E. A Leico light microscope was used to investigate the greater tuberosity, repaired tendon-bone insertion site, and midsubstance of the supraspinatus and infraspinatus tendons under light microscopy. Photographs were taken on digital media. We performed semi-quantitative analysis on new cartilage using computerized image analysis (Figure 1).

#### 2.6. Analysis of histology slides

Collagen fiber organization, fiber structure, nuclei rounding, regional cellularity changes, and fibrocartilage development at the tendon-bone junction were studied after slide preparation. All specimens had their light intensities measured under identical illumination circumstances and during the same session. Because natural rotator cuff insertions have a fibrocartilaginous transition zone, the amount of new cartilage generated at the insertion site was also determined. All histomorphometric analyses were conducted by a single physician with over ten years of experience examining the histology of rat rotator cuff repair. The evaluator was blinded to the time of death and whether the specimen was in the experimental or control group during the assessment.

Four specimens were immunohistochemically stained for BMP-2 and GDF 7 at each time point. For immunohistochemical staining, hydrated serial slices were treated with 3 percent hydrogen peroxide to inhibit endogenous peroxidase activity, and nonspecific antibody binding was inhibited with 5% goat serum. BMP-2 and GDF 7 were localized using goat anti-rat monoclonal antibodies at the repair site. The production of collagen 1 and 3 at the healing tendon-bone contact was determined using rabbit monoclonal antibodies against collagen 1 and 3.

All specimens received 30 minutes of primary antibody treatment on separate serial sections.

Bound antibodies were observed at room temperature using a goat avidin-biotin-peroxidase system with a chromogen of 3, 3'-diaminobenzidine (DAB; Dako, Carpinteria, CA). The blindfolded observer determined staining subjectively. The scale ran from 0 to 3, with 0 being undetectable, 1 being sparse, 2 being moderate, and 3 being high. The results were then compared statistically.

### 3. Results

*H&E staining:* Collagen fiber expression was enhanced, as was the number of fibroblasts and chondrocytes. In the 1-week growth hormone group, collagen fibers were observed running parallel to one another. The control group exhibited identical collagen fiber and chondrocyte alignment to the one-week growth hormone group three weeks after treatment. At three weeks, the number of chondrocytes and fibroblasts grew dramatically in the growth hormone group, but the pattern was uneven. The highest concentration of chondrocytes was seen in the transition zone between cartilage and tendon tissue in the growth hormone group. Compared to the control group, there was no discernible demarcation of this zone in the growth hormone group. At 12 weeks, there was no difference in chondrocyte expression or fiber pattern between the two groups. The growth hormone group exhibited no spaces between the collagen fibers, but the control group exhibited irregularly ordered collagen fibers, as shown by the intervening voids.

#### 3.1. Immunohistology

*Collagen 1 and 3:* The immunohistology showed high collagen expression three by the first week in the growth hormone group compared to the control group, which showed scant expression. At three weeks, there was high expression of collagen 1 in the growth hormone group. The difference in collagen types 1 and three expressions was negligible in both the groups at 12 weeks.

#### 3.2. BMP12 or GDF 7

There was high expression of BMP 12 antibodies only at three weeks compared to the control group.

#### 3.3. Statistical analysis

We compared the observation of control and GH groups using paired t-test. The comparisons were made for H&E staining, and immunohistology slides at 1, 3, 6, 12 weeks. SPSS software was used to conduct the statistical analysis.

### 4. Discussion

Numerous growth factors are essential in rotator cuff healing.<sup>12</sup> The basic fibroblast growth factor (bFGF), bone



morphogenetic protein 12 (BMP-12), BMP-13, and BMP-14, cartilage oligomeric matrix protein (COMP), connective tissue growth factor (CTGF), platelet-derived growth factor-beta (PDGF-B), and transforming growth factor-beta 1 (TGF- $\beta$ 1) are stimulated during the typical recovery period of a rotator cuff tears.<sup>6, 13–17</sup>

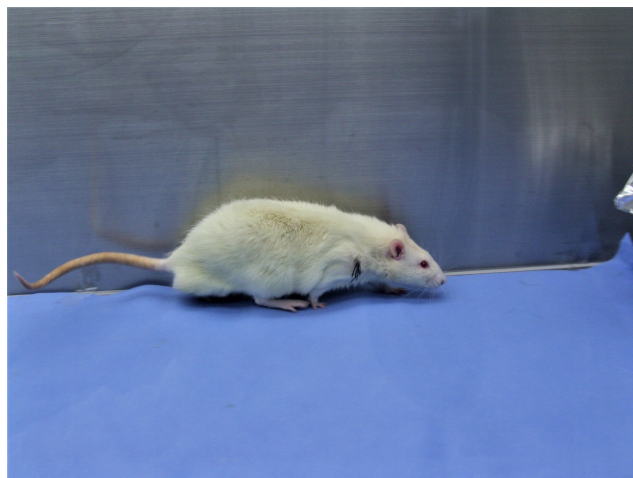
GH has been found in several studies to enhance VEGF levels in healing tissue. VEGF promotes angiogenesis, the formation of new blood vessels. Angiogenesis is a vital phase in the healing process because it results in an increase in the delivery of nutrients, growth factors, and inflammatory cells to the site of injury. Increased VEGF levels in the restored rotator cuff will facilitate tendon tissue integration into the bone by stimulating angiogenesis between the bleeding bone bed produced during the rotator cuff repair and the tendon tissue. This results in accelerated healing and the formation of high-quality granulation tissue. Due to the presence of these factors during the rotator cuff's natural repair process, increased local concentration of these factors can aid in the healing process.

Different methods have been attempted to increase the concentration of growth factors in the rotator cuff healing site or at the bone tendon junction.<sup>18</sup> Various approaches are available, including stem cells, gene therapy, coated sutures, direct delivery using a gel-based solution, and PRP treatment.<sup>18–22</sup> Specific therapies, such as gene therapy, which inserts the genes necessary for the production of growth factors into the native tissue, have demonstrated significant promise. Nonetheless, laboratory success could not be repeated in clinical trials. Topical administration methods may raise the concentration of growth factors in the immediate area. Nevertheless, increasing the local concentration of growth factors does not guarantee that they will be absorbed and employed for tissue healing. On the other hand, systemic injection of growth hormone ensures its absorption into the bloodstream, which increases the local concentration of growth factors, making it more effective than previously used approaches.

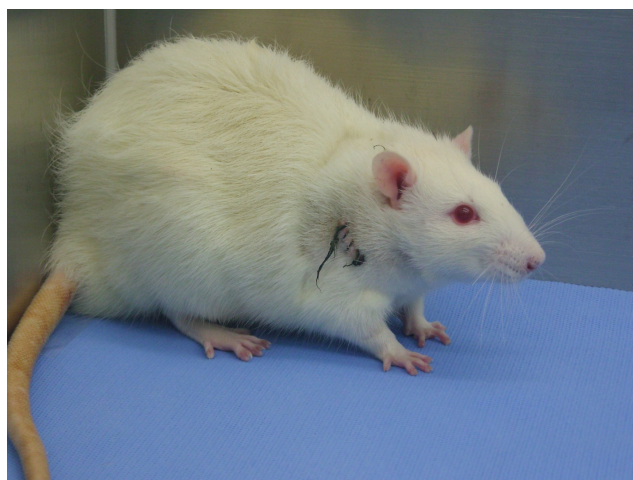
The particular mechanism by which the clinical result improved is uncertain. One element that may have influenced recovery is the anabolic effects of growth hormone on the local level, which would have accelerated the production of new cells. Enhanced GH levels may have increased IGF-1 expression in tendon tissue.<sup>23,24</sup> There could have been a rise in systemic IGF-1 levels due to enhanced liver production. Numerous human studies have established that increasing GH levels induce IGF-1 synthesis. Increased IGF-1 levels in humans enhance bone development, protein synthesis, muscle glucose uptake, neuron survival, and myelin production.

Additionally, IGF-I reverses a negative nitrogen balance during food deprivation and slows muscle protein breakdown. IGF-I promotes osteoblastic lineage cell replication, increases osteoblastic collagen synthesis

and matrix apposition rates, and inhibits collagen breakdown.<sup>25–27</sup> These effects were reported in rats given rGH in our study. The animals healed far faster than the control group (Figure 3 and Figure 4) After 12 days, rats given rGH could carry full weight on the surgical leg, but rats in the control group required more than 21 days to bear full weight on the operated limb.



**Fig. 3:** Rat with rGH administration showing increased hair growth and movement.



**Fig. 4:** Control group less hair growth at the incision site and less activity.

Interestingly, the injected animals grew hair faster and gained more weight than their control group peers. Apart from enhancing previously proven healing potential in humans, the systemic benefits make it an even more attractive choice for augmenting rotator cuff restoration.

Doessing et al. have demonstrated an increase in collagen formation in the human quadriceps tendon after 14 days of administration of GH. Our results show an increased collagen one concentration after three weeks compared

to the control group. Longobardi and Powrie et al. have reported an increase in the concentration of procollagen III, a marker of collagen synthesis after GH supplementation in human beings. Choy et al. have shown a beneficial healing potential of recombinant growth hormone on the Achilles tendon of the pig.

Systemic administration of rhGH increased collagen I and III in both the tendons in our study. The collagen one was raised in the growth hormone samples after 3 weeks (3 weeks, 6 weeks, 12 weeks), while collagen three levels were increased compared to control in the 1-week sample but decreased in the later samples. This is evident in H&E staining as well as immunohistology. The slides on H&E staining showed an increased number of chondrocytes and increased multiplication of fibroblasts, seen as spindle-shaped cells with hyperchromatic nuclei. The cartilage cells are embedded in the collagen fibers, which arise from the humeral head in a parallel manner at one week in the growth hormone group. The collagen fibers are not seen incorporating into the bone in the control group. The improved clinical outcome of the repaired rotator cuff tendons with systemic administration of rGH maybe because the rGH administration increased the expression of collagen types 1 and 3 at the repair site. Many studies support the view that GH stimulates collagen synthesis and are compatible with our observations of increased collagen synthesis, Types 1 and 3 after GH administration.<sup>28,29</sup> Faster healing of rotator cuff tears via systemic administration of rGH makes it a more accessible, cheaper, and clinically feasible way to achieve normal healing tissue in rotator cuff tear repair. We chose BMP12 over other growth factors because it has incorporated the tendon into the bone during healing.<sup>9</sup> In our study, an increased expression of BMP12 was detected by immune-histology at three weeks. The precise reason for an enhanced expression of BMP12 is not known. Systemic administration could not be directly upregulated because antibody complexes in high numbers were detected only three weeks. High levels of BMP12 can most likely explain this observation at 3 weeks were in response to increased collagen 1. High BMP12 levels might have been required to integrate collagen tissue in the tendon to the bone.

GH has multiple systemic effects. The systemic impact of GH gives an additional but essential advantage for patients suffering from rotator cuff tears, especially in the old age group. Growth hormone prevents osteoporosis; this makes it substantially valuable for patients of the older age group. Improvement in the bone quality due to increased bone turnover will result in decreased incidence of rotator cuff failure because of anchor loosening and pull out.

One of the study's limitations was that the quality of tendon tissue was good. The tendons were repaired immediately after their detachment, unlike the clinical scenario where the quality of tendon tissue is relatively poor because of the degenerative changes. Another drawback of

our study was that the increased level of growth factors could only be sustained for 12 weeks, while the normal healing response to an injury lasts for many months. There is one additional limitation of the present study. Because rGH is known to raise the amount of blood glucose hormone, extra caution may be required in individuals with diabetes to control hyperglycemia.

## 5. Conclusion

Our research of systemic rGH treatment in a rat model of rotator cuff repair yielded extremely positive findings. We could not pinpoint the precise pathway or mechanism responsible for the improved functional outcome after rotator cuff restoration. While additional research is necessary for this area, it is unclear whether injecting a single growth factor at the local site is ideal for reducing re-tear. Perhaps, GH administration is regulated at precise points during healing will bring the best results. Suppose the current study's effectiveness can be applied to the clinical setting through more research. In that case, it will mark a watershed moment to improve the outcome of rotator cuff injuries.

## 6. Abbreviation

rGH: recombinant Growth Hormone.

## 7. Source of Funding

None.

## 8. Conflict of Interest

The author declares that there is no conflict of interest.

## References

1. Yamaguchi K, Ditsios K, Middleton WD, Hildebolt CF, Galatz LM, Teefey SA, et al. The demographic and morphological features of rotator cuff disease. A comparison of asymptomatic and symptomatic shoulders. *J Bone Joint Surg Am.* 2006;88(8):1699–704. doi:10.2106/JBJS.E.00835.
2. Lafosse L, Brozka R, Toussaint B, Gobezie R. The outcome and structural integrity of arthroscopic rotator cuff repair with use of the double-row suture anchor technique. *J Bone Joint Surg Am.* 2007;89(7):1533–41. doi:10.2106/JBJS.F.00305.
3. Gulotta LV, Kovacevic D, Cordasco F, Rodeo SA. Evaluation of tumor necrosis factor alpha blockade on early tendon-to-bone healing in a rat rotator cuff repair model. *Arthrosc.* 2011;27(10):1351–7. doi:10.1016/j.arthro.2011.03.076.
4. Hays PL, Kawamura S, Deng XH, Dagher E, Mithoefer K, Ying L, et al. The role of macrophages in early healing of a tendon graft in a bone tunnel. *J Bone Joint Surg Am.* 2008;90(3):565–79. doi:10.2106/JBJS.F.00531.
5. Kawamura S, Ying L, Kim HJ, Dynybil C, Rodeo SA. Macrophages accumulate in the early phase of tendon-bone healing. *J Orthop Res.* 2005;23(6):1425–32. doi:10.1016/j.orthres.2005.01.014.1100230627.
6. Dahlgren LA, Mohammed HO, Nixon AJ. Temporal expression of growth factors and matrix molecules in healing tendon lesions. *J Orthop Res.* 2005;23(1):84–92. doi:10.1016/j.orthres.2004.05.007.

7. Costa MA, Wu C, Pham BV, Chong AK, Pham HM, Chang J, et al. Tissue engineering of flexor tendons: optimization of tenocyte proliferation using growth factor supplementation. *Tissue Eng.* 2006;12(7):1937–43. doi:10.1089/ten.2006.12.1937.
8. Gulotta LV, Rodeo SA. Growth factors for rotator cuff repair. *Clin Sports Med.* 2009;28(1):13–23. doi:10.1016/j.csm.2008.09.002.
9. Kovacevic D, Rodeo SA. Biological augmentation of rotator cuff tendon repair. *Clin Orthop Relat Res.* 2008;466(3):622–33. doi:10.1007/s11999-007-0112-4.
10. Soslowky LJ, Carpenter JE, DeBano CM, Banerji I, Moalli MR. Development and use of an animal model for investigations on rotator cuff disease. *J Shoulder Elbow Surg.* 1996;5(5):383–92. doi:10.1016/s1058-2746(96)80070-x.
11. Liu X, Manzano G, Kim HT, Feeley BT. A rat model of massive rotator cuff tears. *J Orthop Res.* 2011;29(4):588–95. doi:10.1002/jor.21266.
12. Wurgler-Hauri CC, Dourte LM, Baradet TC, Williams GR, Soslowky LJ. Temporal expression of 8 growth factors in tendon-to-bone healing in a rat supraspinatus model. *J Shoulder Elbow Surg.* 2007;16(5 Suppl):S198–203. doi:10.1016/j.jse.2007.04.003.
13. Galatz LM, Sandell LJ, Rothermich SY, Das R, Mastny A, Havlioglu N, et al. Characteristics of the rat supraspinatus tendon during tendon-to-bone healing after acute injury. *J Orthop Res.* 2006;24(3):541–50. doi:10.1002/jor.20067.
14. Duncan MR, Frazier KS, Abramson S, Williams S, Klapper H, Huang X, et al. Connective tissue growth factor mediates transforming growth factor beta-induced collagen synthesis: down-regulation by cAMP. *FASEB J.* 1999;13(13):1774–86.
15. Thomopoulos S, Harwood FL, Silva MJ, Amiel D, Gelberman RH. Effect of several growth factors on canine flexor tendon fibroblast proliferation and collagen synthesis in vitro. *J Hand Surg Am.* 2005;30(3):441–448.
16. Smith RK, Gerard M, Dowling B, Dart AJ, Birch HL, Goodship AE, et al. Correlation of cartilage oligomeric matrix protein (COMP) levels in equine tendon with mechanical properties: a proposed role for COMP in determining function-specific mechanical characteristics of locomotor tendons. *Equine Vet J Suppl.* 2002;(34):241–4. doi:10.1111/j.2042-3306.2002.tb05426.x.
17. R J, G K, G B, B CA. Tendon: biology, biomechanics, repair, growth factors, and evolving treatment options. *J Hand Surg Am.* 2008;33(1):102–12. doi:10.1016/j.jhsa.2007.09.007.
18. Dines JS, Weber L, Razzano P, Prajapati R, Timmer M, Bowman S, et al. The effect of growth differentiation factor-5-coated sutures on tendon repair in a rat model. *J Shoulder Elbow Surg.* 2007;16(5 Suppl):S215–21. doi:10.1016/j.jse.2007.03.001.
19. Montgomery SR, Petrigliano FA, Gamradt SC. Biologic augmentation of rotator cuff repair. *Curr Rev Musculoskelet Med.* 2008;4(4):221–30. doi:10.1007/s12178-011-9095-6.
20. Theisen C, Fuchs-Winkelmann S, Knappstein K, Efe T, Schmitt J, Paletta JR, et al. Influence of nanofibers on growth and gene expression of human tendon derived fibroblast. *Biomed Eng Online.* 2010;9(9).
21. Manning CN, Kim HM, Sakiyama-Elbert S, Galatz LM, Havlioglu N, Thomopoulos S, et al. Sustained delivery of transforming growth factor beta three enhances tendon-to-bone healing in a rat model. *J Orthop Res.* 2011;29(7):1099–105. doi:10.1002/jor.21301.
22. Gulotta LV, Kovacevic D, Montgomery S, Ehteshami JR, Packer JD, Rodeo SA, et al. Stem cells genetically modified with the developmental gene MT1-MMP improve regeneration of the supraspinatus tendon-to-bone insertion site. *Am J Sports Med.* 2007;35(7):1429–37. doi:10.1177/0363546510361235.
23. S W, P H, M B, A M, P K, G Z, et al. Systemic response of the GH/IGF-I axis in timely versus delayed fracture healing. *Growth Horm IGF Res.* 2008;18(3):205–15. doi:10.1016/j.ghir.2007.09.002.
24. Holzenberger M. The GH/IGF-I axis and longevity. *Eur J Endocrinol.* 2004;151(1):S23–7. doi:10.1530/eje.0.151s023.
25. Kurtz CA, Loebig TG, Anderson DD, Demeo PJ, Campbell PG. Insulin-like growth factor I accelerates functional recovery from Achilles tendon injury in a rat model. *Am J Sports Med.* 1999;27(3):363–9. doi:10.1177/03635465990270031701.
26. Ueland T, Fougner SL, Godang K, Schreiner T, Bollerslev J. Serum GH and IGF-I are significant determinants of bone turnover but not bone mineral density in active acromegaly: a prospective study of more than 70 consecutive patients. *Eur J Endocrinol.* 2006;155(5):709–15. doi:10.1530/eje.1.02285.
27. Gonc EN, Kandemir N. Long-term effects of growth hormone (GH) on bone mineral status and bone turnover markers in patients with isolated GH deficiency and multiple pituitary hormone deficiency. *Clin Endocrinol (Oxf).* 2007;66(5):672–7. doi:10.1111/j.1365-2265.2007.02799.x.
28. Dall R, Longobardi S, Ehrborg C, Keay N, Rosen T, Jorgensen JO, et al. The effect of four weeks of supraphysiological growth hormone administration on the insulin-like growth factor axis in women and men. GH-2000 Study Group. *J Clin Endocrinol Metab.* 2000;85(11):4193–200. doi:10.1210/jcem.85.11.6964.
29. Powrie JK, Bassett EE, Rosen T, Jorgensen JO, Napoli R, Sacca L, et al. Detection of growth hormone abuse in sport. *Growth Horm IGF Res.* 2007;17(3):220–6. doi:10.1016/j.ghir.2007.01.011.

## Author biography

**Dheeraj Makkar**, Assistant Professor

**Sangh Hoon Lee**, Professor

**Cite this article:** Makkar D, Lee SH. Effect of systemic administration of recombinant growth hormone on rotator cuff repair a rat model study. *IP J Surg Allied Sci* 2022;4(1):19-24.