

Content available at: <https://www.ipinnovative.com/open-access-journals>

IP Journal of Surgery and Allied Sciences

Journal homepage: <https://www.jsas.co.in/>

## Original Research Article

## A study of duplex ultrasound examination in peripheral vascular malformations

Nirmala C Chudasama<sup>1</sup>, Dhrupal B Dodia<sup>1,\*</sup>, Ankit D Moradiya<sup>1</sup>, Samir H Santoki<sup>1</sup><sup>1</sup>Dept. of Radiology, C.U. Shah Medical College and Hospital, Gujarat, India

## ARTICLE INFO

## Article history:

Received 04-09-2022

Accepted 14-09-2022

Available online 17-10-2022

## Keywords:

Hypoechoic

Phleboliths

Hypervascular

## ABSTRACT

**Aims & Objectives:** Vascular malformations belong to wide spectrum of disease involving all vascular segments- arteries, veins as well as lymphatics. Being Ultrasound as the primary diagnostic modality, all peripheral vascular malformation diagnosis can be made by clinical examination and duplex ultrasound examination.

**Materials and Methods:** A study of 50 patients was carried over a period of 1 year from 1<sup>st</sup> May 2021 to 1<sup>st</sup> May 2022 on the patient who came with complain of slow growing, superficial swelling which is painless in nature. The machine used is Affinity Philips 70 G.

**Results:** With help of duplex ultrasound, various types of vascular malformations were diagnosed with incidence such as Slow Flow Venous malformation (60%- 30 patients), High flow Arterio-venous malformations (16%- 8 patients), Capillary malformations (12%- 6 patients) and Lymphatic malformations (12%- 6 patients).

**Discussions:** Vascular malformations have been classified into venous, arterial, capillary, combined and lymphatic malformations types. Besides age presentations, detailed history and clinical examination, ultrasound imaging plays an important role in correct diagnosis and classification of vascular malformations. It assesses exact flow dynamics in order to differentiate between Slow flow v/s High flow vascular malformations. MRI is most valuable diagnostic tool for comprehensive assessment of vascular malformations

**Conclusion:** Ultrasound are first imaging modality in peripheral vascular malformations. It has plays crucial role in proper treatment planning of the lesion as it describes the extent, type, flow pattern within the lesion.

This is an Open Access (OA) journal, and articles are distributed under the terms of the [Creative Commons Attribution-NonCommercial-ShareAlike 4.0 License](https://creativecommons.org/licenses/by-nc-sa/4.0/), which allows others to remix, tweak, and build upon the work non-commercially, as long as appropriate credit is given and the new creations are licensed under the identical terms.

For reprints contact: [reprint@ipinnovative.com](mailto:reprint@ipinnovative.com)

## 1. Introduction

1. Peripheral vascular malformations has a wide spectrum of lesions which can be found incidentally or symptomatically as slow growing painless swelling or painful if it has intra-articular or intra-osseous extension.
2. It involves all the vascular trees that includes arteries, veins, capillaries as well as lymphatics.

3. Ultrasound being primary modality of choice along with detailed clinical history and examination play a crucial role in diagnosing the type of lesion and its extent.<sup>1-3</sup>

## 1.1. Classifications

It can be classified based on flow dynamics into:

1. Slow flow vascular malformations.
2. High flow vascular malformations.
3. Complex/Mixed vascular malformations.<sup>4</sup>

\* Corresponding author.

E-mail address: [dhrupaldodia2@gmail.com](mailto:dhrupaldodia2@gmail.com) (D. B. Dodia).

## 2. Aims and Objectives

The purpose of this study is to perform duplex ultrasonographic examination as primary modality of choice in patients presenting with complaints of slow growing painless swelling in peripheral regions that leads to diagnosing various types of vascular malformation primarily, with its extent and various types.

## 3. Materials and Methods

1. A study of 50 patients was carried over a period of 1 year from 1<sup>st</sup> May 2021 to
2. 1<sup>st</sup> May 2022 on the patient who came with complain of slow growing, superficial swelling which is painless in nature. The machine used is Affinity Philips 70 G.

**Table 1:**

Slow flow vascular malformations	High flow vascular malformations	Complex/Mixed Vascular malformations
Capillary malformations	Arterial malformations	Capillary-venous malformations
Venous malformations	Arterio-venous malformations	Capillary-lymphatics malformations
Lymphatics malformation	Arterio-venous fistula	Lymphatic-venous malformations
		Capillary-arteriovenous malformations

### 3.1. Soft tissue venous malformations

#### 3.1.1. Age presentations

Paediatric population with female predominance, However can present in adult population.

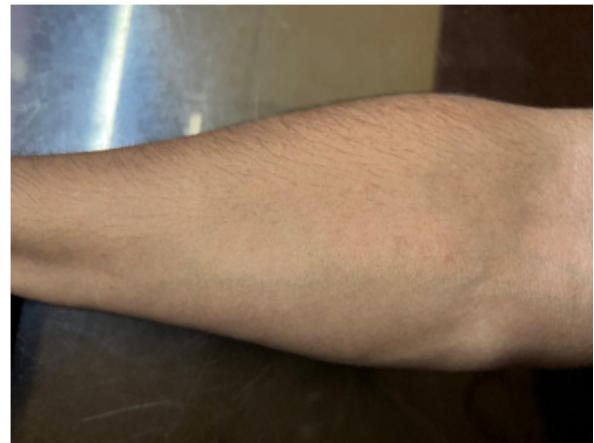Most common among all vascular malformations.

### 3.2. Characteristics

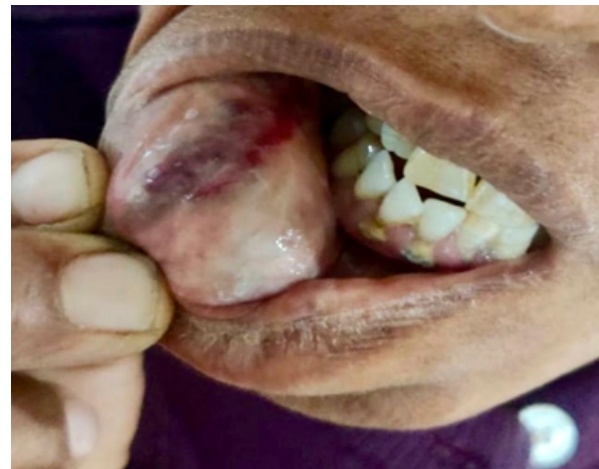1. Light to dark blue
2. Empty by light compression If superficial
3. No thrill/bruit, No warmth
4. Painless on palpation unless thrombosis
5. Can arise from any tissue including bone<sup>5</sup>

### 3.3. Ultrasound findings

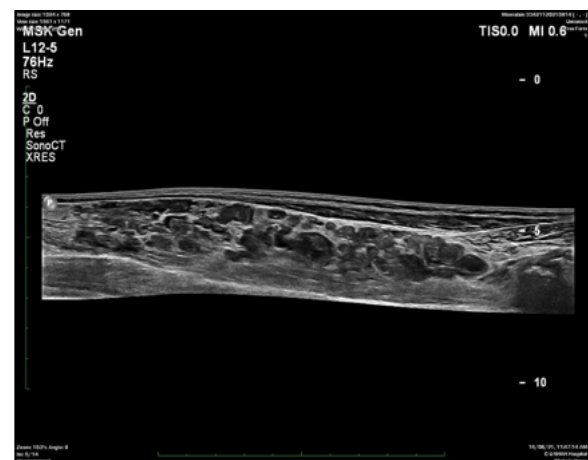
USG images shows ill-defined heterogeneously hypochoic mass lesion with multiple cystic spaces within intramuscular plane on flexor aspect of forearm. There is evidence of multiple phleboliths within it. On color doppler study, weak signal venous flow is noted within the lesion. There in no communication noted between the lesion and the arterial supply.



**Fig. 1:** Shows hard swelling over flexoraspect of forearm.



**Fig. 2:** Shows swelling with light to dark blue discoloration of inner aspect of right cheek



**Fig. 3:** Shows ill-defined heterogeneously hypochoic mass lesion with multiple cystic spaces within intramuscular plane on flexor aspect of forearm.

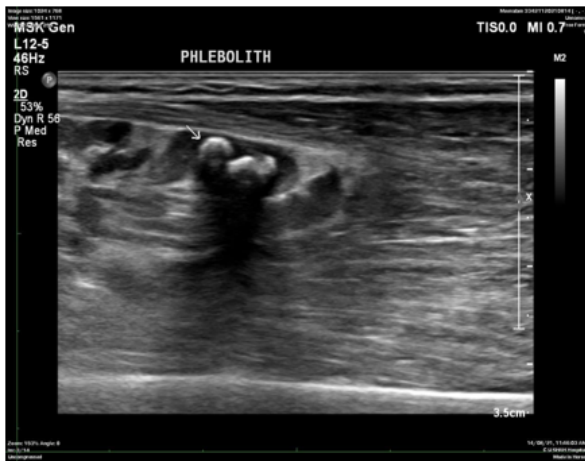

Fig. 4: Shows multiple phlebolith within mass lesion

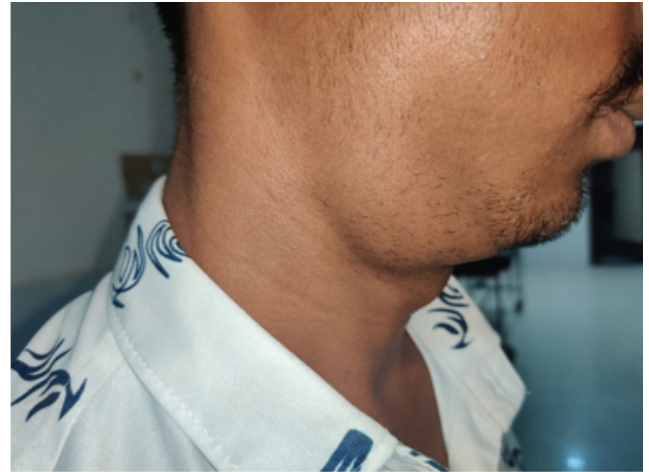

Fig. 7: Shows soft supple mass seen over right neck extending to nap of neck region in young adult

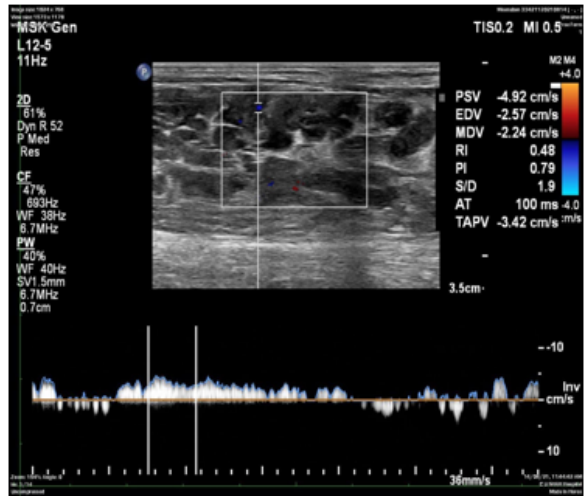


Fig. 5: Shows weak signal venous flow is noted within the lesion.

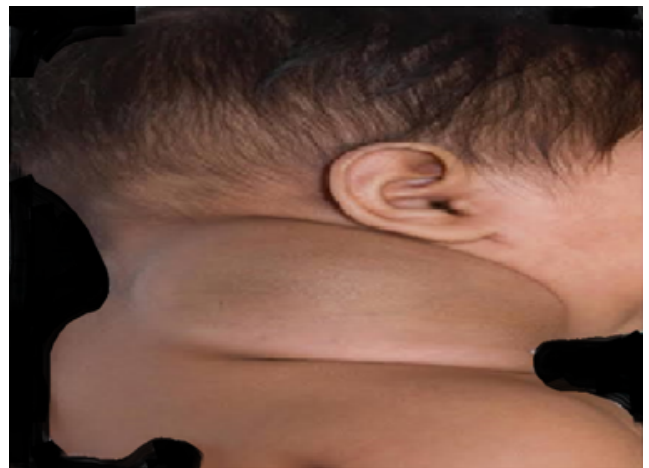

Fig. 8: Shows soft supple mass seen over right neck extending to nap of neck region in infant

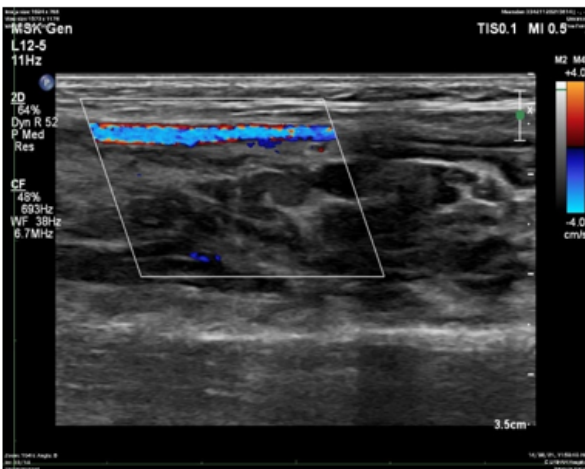


Fig. 6: Shows no arterial communication.

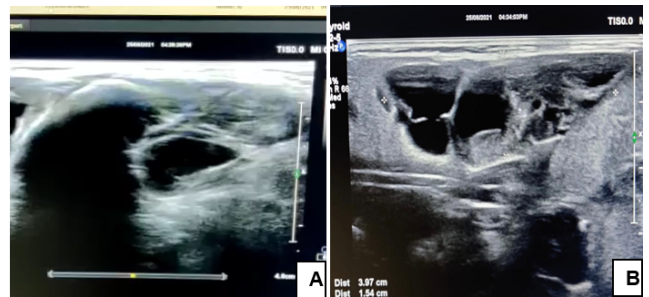


Fig. 9: A: & B: Shows multiloculated cystic mass lesion with thick internal septation.

**Table 2:**

Type of Vascular malformation	Number of Patients (Total = 50)
Venous malformations	30 (60%)
Lymphatic malformations	6 (12%)
Arterio-venous malformations	8 (16%)
Capillary malformations	6 (12%)

### 3.4. Lymphatic malformations

1. Age presentation
2. By age of 2 years

### 3.5. Cystic / Nuchal Hygroma

In adulthood

1. Renal lymphangioma
2. Retroperitoneal lymphatic malformation
3. Splenic /hepatic /pancreatic lymphangioma

### 3.6. Characteristics

1. Supple mass
2. Trans-illuminate
3. No bruit, No warmth
4. May change in size
5. Intact skin

### 3.7. Ultrasound findings

USG images showed a multiloculated cystic mass lesion with thick internal septations. On colour doppler images, the septa show minimal vascularity within it. Facial vessels appear to be traversing through the lesion.<sup>6,7</sup>

## 4. Arterio-Venous Malformations

### 4.1. Age presentation

1. Typically congenital,
2. Grows with age and may not manifest until adolescence or adulthood.

### 4.2. Characteristics

1. No discrete mass lesion
2. Area of local discoloration.
3. Local warmth to touch
4. Associated thrill or murmur
5. Frequent late diagnosis.<sup>8,9</sup>

### 4.3. Ultrasound findings

USG images shows mixed echogenicity lesion which is hypervascular. On colour doppler, Feeding artery shows increased diastolic flow and arterialized draining veins with pulsatile flow.

## 5. Incidence of Various Vascular Malformations

In our study of 50 patients within limited period of 1 year, various types of vascular malformation have been diagnosed with incidence rate as described.

## 6. Conclusion & Discussion

From our study, we conclude that Ultrasound acts as primary modality of choice in diagnosing various types of malformations and its extent. We conclude that with detailed history, clinical examination and ultrasound Examination:

Slow flow venous malformation remained as more frequently encountered vascular malformations. Its characteristic ultrasound features are cystic spaces within the soft tissue mass lesion, presence of phlebolith which being characteristic feature.<sup>10</sup> Lymphatic malformations have its typical location, with characteristic sonographic features as anechoic cystic lesion with thick septations and may encase the adjacent structures. On colour doppler, the septations may or may not show internal vascularity.<sup>11</sup>

Arterio-venous malformations mainly present in adulthood or adolescence period with high flow velocity and low resistance vascular malformation,<sup>12</sup> however no discrete mass lesion seen. Capillary malformations also known as portwine stain are based on clinical diagnosis

Ultrasound imaging has no role in diagnosing it. MRI plays important role to rule out its association with various syndrome such as Sturge-weber syndrome, Klippel-Trenaunay Syndrome etc.<sup>3</sup>

The study of flow dynamics can be made by contrast based MRI which remain as Preferred modality of choice as it gives detailed extent of the lesion with its characteristics. Graph is plotted with variables as arterial lesion time, maximum enhancement time and slope provides significant information to differentiate between slow flow vs high flow malformations.<sup>13,14</sup>

## 7. Source of Funding

None.

## 8. Conflicts of Interest

None.

## References

1. Greene AK, Liu AS, Mulliken JB, Chalache K, Fishman SJ. Imaging of vascular malformations. *Radiol Clin N Am.* 2011;58(4):815–30.
2. Marler JJ, Mulliken JB. Vascular anomalies: classification, diagnosis, and natural history. *Facial Plast Surg Clin North Am.* 2001;9(4):495–504.
3. Hussein A, Malguria N. Imaging of vascular malformations. *Radiol Clin N Am.* 2020;58(4):815–30.
4. Enjolras O. Classification and management of the various superficial vascular anomalies: hemangiomas and vascular malformations. *J Dermatol.* 1997;24(11):701–11.

5. Olivieri B, White CL, Restrepo R, Mckeon B, Karakas SP, Lee EY. Low-Flow Vascular Malformation Pitfalls: From Clinical Examination to Practical Imaging Evaluation–Part 2, Venous Malformation Mimickers. *AJR Am J Roentgenol.* 2016;206(5):952–62.
6. Johnson AB, Richter GT. Vascular anomalies. *Clin Perinatol.* 2018;45(4):737–49.
7. Fevurly RD, Fishman SJ. Vascular anomalies in pediatrics. *Surg Clin North Am.* 2012;92(3):769–800.
8. de Miguel R, López-Gutierrez JC. Arteriovenous Malformations: A Diagnostic and Therapeutic Challenge Malformaciones arteriovenosas: un reto diagnóstico y terapéutico. *Actas Dermosifiliogr.* 2014;105(4):347–58.
9. Greene AK, Orbach DB. Management of arteriovenous malformations. *Clin Plast Surg.* 2011;38(1):95–106.
10. Cavezzi A, Parsi K. Complications of foam sclerotherapy. *Phlebology.* 2012;27(1):46–51.
11. Johnson CM, Navarro OM. Clinical and sonographic features of pediatric soft-tissue vascular anomalies part 2: vascular malformations. *Pediatr Radiol.* 2017;47(9):1196–208.
12. Noshier JL, Murillo PG, Liszewski M, Gendel V, Gribbin CE. Vascular anomalies: a pictorial review of nomenclature, diagnosis and treatment. *World J Radiol.* 2014;6(9):677–92.
13. Mulliken JB, Glowacki J. Hemangiomas and vascular malformations in infants and children: a classification based on endothelial characteristics. *Plast Reconstr Surg.* 1982;69(3):412–34.
14. Ernemann U, Kramer U, Miller S, Bisdas S, Rebmann H, Breuninger H. Current concepts in the classification, diagnosis and treatment of vascular anomalies. *Eur J Radiol.* 2010;75(2):2–11.

### Author biography

**Nirmala C Chudasama, HOD**

**Dhrupal B Dodia, Resident Doctor**

**Ankit D Moradiya, Resident Doctor**

**Samir H Santoki, Resident Doctor**

**Cite this article:** Chudasama NC, Dodia DB, Moradiya AD, Santoki SH. A study of duplex ultrasound examination in peripheral vascular malformations. *IP J Surg Allied Sci* 2022;4(3):101-105.