



Original Research Article

Evaluation of histopathological spectrum of hepatic lesions in liver biopsies in a tertiary care hospital

Vidhi P. Patel^{1,*}, Sadhana L. Kothari¹, Anupama I. Dayal¹, Naimish A. Patel², Sushil D. Akruwala³¹Dept. of Pathology, GCS Medical College Hospital and Research Centre, Ahmedabad, Gujarat, India²Dept. of Medicine, GCS Medical College Hospital and Research Centre, Ahmedabad, Gujarat, India³Dept. of Surgery, GCS Medical College Hospital and Research Centre, Ahmedabad, Gujarat, India

ARTICLE INFO

Article history:

Received 07-09-2021

Accepted 20-11-2021

Available online 28-11-2022

Keywords:

Histopathological spectrum

hepatic lesions

liver biopsy

ABSTRACT

Background: Liver is vulnerable to a wide variety of metabolic, toxic, circulatory insults and is affected by a wide spectrum of various primary and secondary diseases. Liver biopsy contributes greatly to the understanding of liver diseases & is considered gold standard for evaluating liver disorders, providing information regarding diagnosis, disease progression and response to therapy. Being an invasive procedure with certain unavoidable risks, with proper procedural precautions and careful selection of patients, complications and risks can be greatly minimized.

Objectives: To study histopathological features of liver biopsies in patients with liver disease. To document the pattern of various hepatic lesions. To document various types of lesions predominant in different age groups.

Materials and Methods: A prospective study was conducted in Department of Pathology of tertiary care hospital of Ahmedabad over a period of two years which included 74 liver biopsies. Clinical, demographic and pathologic data was collected and analysed for each case.

Results: Out of total 74 liver biopsy specimen, 47.29% cases were males, 52.70% were females. Malignant lesions were most common finding (52/74), out of which 37(50%) were metastatic adenocarcinoma, 10 (13.51%) were hepatocellular carcinoma and 5 (6.75%) were cholangiocarcinoma. Non neoplastic lesions included 10 cases which were of hepatitis, cirrhosis, hemangioma, biliary atresia and hydatid cyst formation. In 12 cases (16.21%), there were no significant findings.

Conclusion: The histopathological study of liver biopsy forms the cornerstone in the diagnosis and management of various hepatic diseases. Microscopic examination of liver biopsy yields range of pathological findings and helps in specific management.

This is an Open Access (OA) journal, and articles are distributed under the terms of the [Creative Commons Attribution-NonCommercial-ShareAlike 4.0 License](#), which allows others to remix, tweak, and build upon the work non-commercially, as long as appropriate credit is given and the new creations are licensed under the identical terms.

For reprints contact: reprint@ipinnovative.com

1. Introduction

Erlich performed the first liver aspiration in 1883 and subsequently in 1923 first percutaneous liver biopsy was reported for diagnostic purposes.¹ Liver is the main site for various metabolic activities of the body. Liver biopsy becomes essential investigation especially in abnormal liver

tests, not explained by other methods, in evaluation and staging of chronic liver diseases, in diagnosing various lesions of liver. Histopathological study of liver biopsies continues to be most important procedure in the diagnosis and assessment of severity in various liver disorders. Hence this study was undertaken to analyze the histopathological features of liver biopsies received in Pathology Department of a tertiary care hospital.

* Corresponding author.

E-mail address: vidhipatel9622@gmail.com (V. P. Patel).

2. Materials and Methods

This study was conducted on 74 liver biopsies received for histopathological examination in the department of Pathology of a tertiary care hospital over a period of two years (June 2019 to June 2021). The study was conducted after Institutional Ethics Committee (IEC) approval (GCSMC/EC/Proj/Approve/2020/190). After processing in an automated tissue processor, paraffin embedded blocks were made. The blocks were then cut into sections of 2-5 micrometre thickness using a microtome & were stained by Hematoxylin & Eosin. Special stains like Reticulin and Periodic Acid Schiff (PAS) were used whenever necessary. Sections were studied under light microscope and diagnosis was reached correlating the history, biochemical and radiological investigations. Immunohistochemistry panel consisting of Heppar-1, CEA, CK 7, CK 19, CK 20, EMA were done whenever necessary which aided in reaching the diagnosis. In case of suspected metastasis, IHC was advised depending on the most likely primary site of metastasis.

3. Results

Total of 74 liver biopsy specimens were analysed as per age, gender and histology.

In this study, age ranged from 2 years to 85 years. Mean age was 42.5 years. Majority of patients belonged to the 6th and 7th decade of life. Neoplastic lesions were common in 6th and 7th decades while non neoplastic lesions were common in 3rd and 4th decade. Out of 74 cases, 47.29% were males and 52.70% were females. The male to female ratio was 0.8 (Table 1).

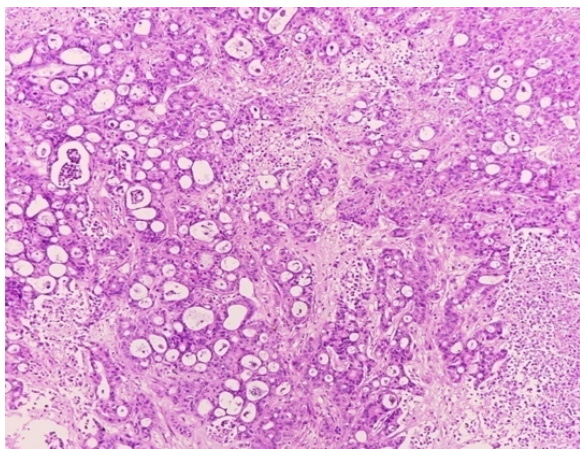


Fig. 1: Photomicrograph showing the metastatic adenocarcinoma deposits in liver (H & E, 10X)

All were tru-cut biopsies, so no gross images to provide.

The most frequently encountered lesion was malignancy in 52 cases (70.27%) (Table 2). Of these, 37 cases (71.15%) were metastatic tumors comprising of adenocarcinomas and 15 cases (28.84%) were primary tumours. Table 2 shows

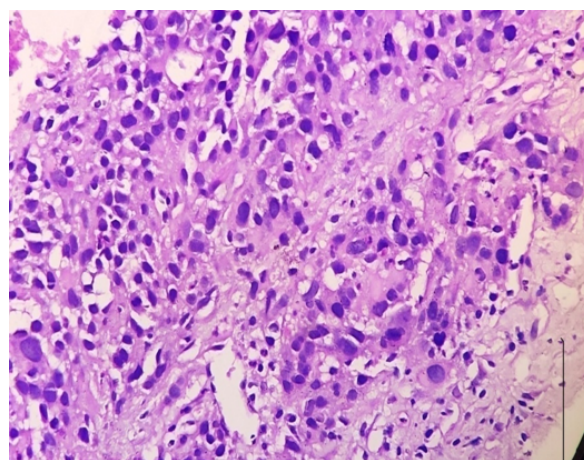


Fig. 2: Photomicrograph showing Hepatocellular carcinoma (H & E, 40X)

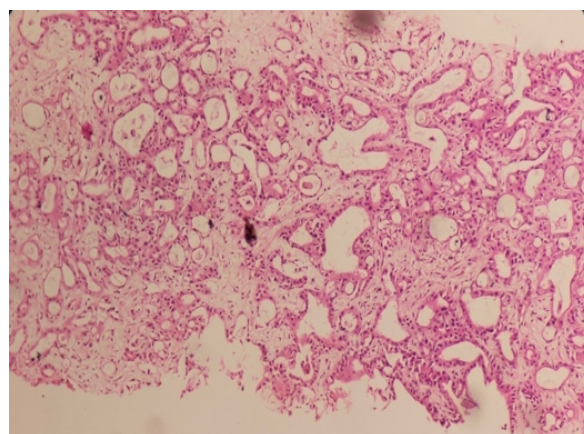


Fig. 3: Photomicrograph showing cholangiocarcinoma (H & E, 40X)

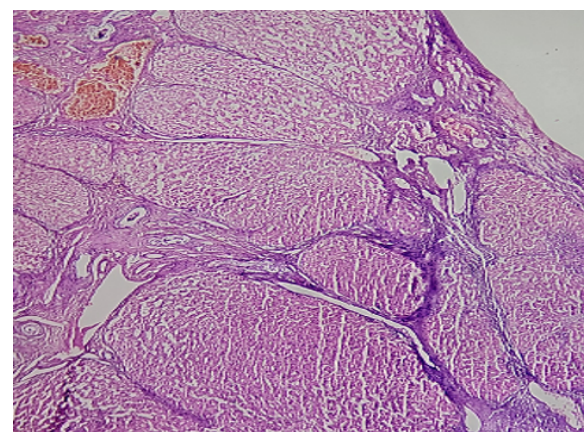


Fig. 4: Photomicrograph of cirrhosis showing the nodules of variable sizes with thin fibrous septa (H & E, 10X).

Table 1: Age and sex wise distribution of various hepatic lesions.

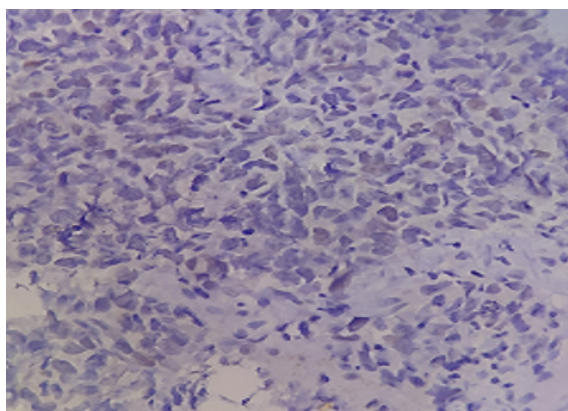
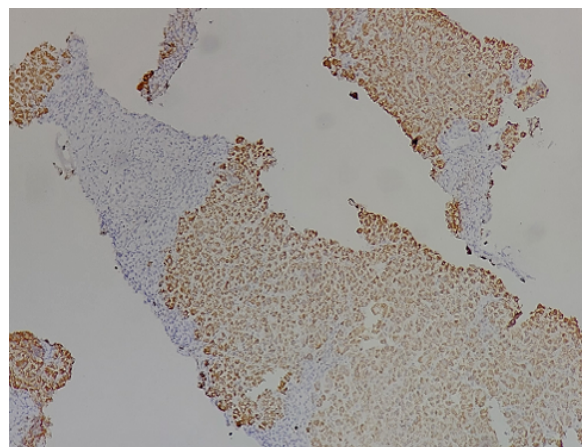
Age Group	Male	Female	No. of cases	Percentage of total cases (%)
0-10	01	01	02	2.70
11-20	00	00	00	00
21-30	00	02	02	00
31-40	02	03	05	6.75
41-50	06	09	15	20.27
51-60	08	13	21	28.37
61-70	14	07	21	28.37
71-80	04	03	07	9.45
>80	00	01	01	1.35
Total cases	35(47.29%)	39(52.70%)	74	100

Table 2: Sex distribution of liver diseases

Diagnosis	Sex		Total (%)
	Male	Female	
Metastatic tumour	13	24	37(50.00)
Hepatocellular carcinoma	09	01	10(13.51)
Cholangiocarcinoma	04	01	05(6.75)
Hepatitis	01	02	03(4.05)
Cirrhosis	00	02	02(2.70)
Congenital	02	01	03(4.05)
Hydatid Cyst	00	01	01(1.35)
Hemangioma	00	01	01(1.35)
No specific lesion	06	06	12(16.21)
Total	35(47.29%)	39(52.70%)	74(100)

Table 3: Comparison with other studies

	Total cases	Tumours	Metastatic malignancy	Primary hepatic malignancy (HCC + Cholangiocarcinoma)
Chawla et al ²	65	17	03	14
Zahir ST et al ³	164	164	115	09
Agrawal et al ⁴	65	34	26	-
Shivani Gandhi et al ⁵	72	24	05	19
Present study	74	52	37	15

**Fig. 5:** Photomicrograph of IHC – ER in case of metastatic adenocarcinoma in known case of breast carcinoma (H & E, 40X)**Fig. 6:** Photomicrograph of IHC- Hep par – 1 in case of hepatocellular carcinoma (H & E, 10X)

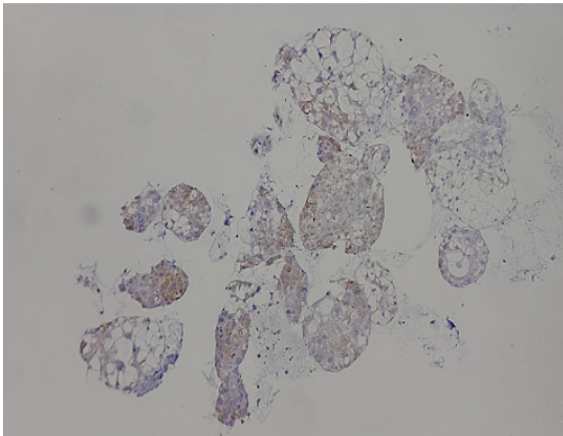


Fig. 7: Photomicrograph of IHC – Glypican 3 in case of hepatocellular carcinoma (H & E, 10X)

gender wise distribution of hepatic lesions. Metastatic tumours showed female preponderance. While primary hepatic tumours including hepatocellular carcinoma and cholangiocarcinoma were common in males. In 6 cases, primary site was suggested based on IHC findings or radiological investigations done. The most common primary site was lung and breast. In 31 cases, the primary was unknown because the patient was lost to follow up for IHC or tissue was insufficient for IHC. Out of 15 cases of primary hepatic tumours, 10 cases were of hepatocellular carcinoma (HCC) and 5 cases were of cholangiocarcinoma. 7 cases of hepatocellular carcinoma and 4 cases of cholangiocarcinoma were confirmed by IHC.

Non neoplastic lesions included 03 cases of hepatitis, 02 cases of cirrhosis, 01 case of cavernous hemangioma. A single case of extrahepatic biliary atresia was seen in an infant with biliary atresia. Various other lesions diagnosed were adult polycystic liver disease, congenital cholestatic liver disease and cystic hydatid disease of liver. Our study showed increased incidence of neoplastic hepatic lesions as compared to infective or metabolic causes. Of the neoplastic lesions, metastasis from primary malignancies has become more common than primary hepatic neoplasms.

4. Discussion

Liver is affected by various primary and secondary diseases and so requires an accurate diagnosis for patient management. Rich porto-systemic blood supply makes liver a favourable site for metastasis.⁶ Therefore, liver histopathology has become a most important diagnostic tool.⁷

The spectrum of hepatic lesions included male and female patients of all age groups. In our study, most common age group affected was 50-70 years (Table 1). In females, commonest age group was 51-60 years and in males, commonest age group was 61-70 years. This finding

was consistent with Shivani Gandhi et al,⁵ Agrawal et al⁴ & Medha Pradeep Kulkarni et al.⁶ This finding was discrepant with Chawla et al² in which 41-50 years was the commonest age group. This could be because the predominant lesions were non-neoplastic (32/65) like cirrhosis, fatty liver and viral hepatitis which are more prevalent in the 4 – 5th decade.

In our study, slight female preponderance was noted. (Table 2) In female, breast carcinoma remains an important site for liver metastasis. As IHC was not done in 31 cases of metastatic adenocarcinoma, underlying primary breast neoplastic etiology may be a reason for slight female preponderance in this study. This finding was consistent with finding of Agrawal et al⁴ in which 57% cases were female however studies done by Shivani Gandhi et al,⁵ Chawla et al,² Murgod PS et al,¹ Medha Pradeep Kulkarni et al⁶ found male preponderance.

Malignancy was the most common finding (70%) (Table 2). This was consistent with findings of Shivani Gandhi et al,⁵ Chawla et al,² Agrawal et al,⁴ who all found malignancy as the commonest finding. The present institute being a tertiary care centre providing oncology hence malignant cases were more likely encountered.

Amongst the malignant lesions hepatic secondaries 50% (n=37) were the commonest histopathological finding and were commonly seen among adult females. Most of the patients were belonging to age group of 50 – 70 years. 2/3rd of patients with hepatic metastases presented with clinical manifestations like ascites, jaundice, anorexia, loss of appetite and weight loss. This was in concordance with Agrawal et al⁴ and Medha Pradeep Kulkarni et al⁶ who found metastatic hepatic involvement as the most common finding. This was discrepant with the findings of Chawla et al,² who reviewed and found hepatocellular carcinoma as the most common hepatic lesion with male predominance. Metastatic involvement of liver is more common than the primary hepatic tumours.⁸ Hepatic metastasis can be seen either by direct spread or due to the dual nature of blood supply of liver from portal and systemic circulation. The common sites of primary tumours that frequently metastasizes to liver include lung, breast, gall bladder, stomach, pancreas, and large intestine.⁹ In our study, metastatic adenocarcinoma with the primary malignancy in lung and breast were noted. Microscopic features are dependent on primary site of malignancy and degree of differentiation. [Figure 1]

Hepatocellular carcinoma was the most common primary hepatic malignancy encountered in our study seen in 13.5% (n=10) cases. Most of the patients were elderly males with male to female ratio of 9:1. Most of the cases belonged to age group of 60-75 years. Chawla et al² noted occurrence of Hepatocellular carcinoma in 21% cases. Hepatitis B & hepatitis C virus infection and alcoholic liver disease plays a role in pathogenesis of hepatocellular carcinoma.⁸

Nonalcoholic fatty liver disease also increases the risk of HCC even in the absence of cirrhosis.⁸ Microscopically, the tumour cells were arranged in trabecular and solid growth patterns. The tumour cells were pleomorphic, large polygonal cells with abundant granular oncocytic cytoplasm (due to abundant mitochondria), vesicular nuclei with prominent nucleoli and parallel bands of dense collagen bundles. More poorly differentiated cases showed marked cytologic atypia. Sinusoidal vessels were seen surrounding the tumour cells. [Figure 2]

The second most common primary hepatic malignancy was cholangiocarcinoma 6.75% (n=5) with male preponderance during their fifth and sixth decade of life. Chronic liver disease such as hepatitis B, hepatitis C and nonalcoholic fatty liver disease increase the risk of intrahepatic cholangiocarcinoma. Microscopically there are clearly defined glandular or tubular structures lined by malignant epithelial cells embedded in abundant fibrous stroma. Cribriform pattern may also be observed. [Figure 3]

Hepatitis was observed in 3 patients out of which 2 were autoimmune hepatitis and 1 of chronic hepatitis. Agrawal et al⁵ found incidence of hepatitis to be 16.9%. Biopsy assessment in chronic viral hepatitis provides the extent of fibrosis which can determine the therapeutic course of disease. Both the cases of autoimmune hepatitis were observed in female. Autoimmune hepatitis is a chronic progressive hepatitis associated with genetic predisposition, autoantibodies and therapeutic response to immunosuppression with a female preponderance. The patients presented with jaundice, hepatomegaly and abnormal LFT.

2 cases of cirrhosis were observed (2.7%) and both were females. Shivani Gandhi et al⁵ found cirrhosis as the second most common hepatic lesion (30%). Cirrhosis was the third most common hepatic lesion (12.3%) in study of Agrawal et al.⁴ Gall et al has found the incidence of cirrhosis to be 6%.¹⁰ The incidence is increasing in women probably due to increased alcohol intake among females.¹¹ Microscopically, there is diffuse disruption in architecture of entire liver with bridging fibrous septa and rounded parenchymal nodules of regenerating hepatocytes. Biopsy histology showed multiple nodules of varying size with underlying fibrous scarring. [Figure 4]

In present study, one case of extrahepatic biliary atresia was observed in 2 year old female patient who presented with persistent jaundice. Extrahepatic biliary atresia is characterized by complete or partial obstruction of the extrahepatic biliary tree within the first 3 months of life. Liver biopsy showed cholestasis with periportal fibrosis and inflammatory destruction of bile ducts. Inflammation and fibrosis of the hepatic or common bile ducts is the hallmark of this disease.⁸

A 56 year old female patient was diagnosed with liver hydatidosis which showed cystic structures with laminating fibrous wall. Hydatid disease is a parasitic infestation caused

by *Echinococcus granulosus* and liver is the commonest infected organ in the body. The cysts are usually localized in liver and are filled with clear fluid.⁹

One case of hemangioma was noted in the study. Patient was 40 year old female. It is most common benign liver tumour.¹² Patients are usually asymptomatic and diagnosed incidentally by imaging. Biopsy showed variable sized channels lined by benign endothelial cells containing red blood cells.

A 71-year old male patient was diagnosed with Adult Polycystic Kidney/Liver disease. Liver cysts are the most common extrarenal manifestations of autosomal dominant polycystic kidney disease. Incidence increases with increasing age.¹³

Immunohistochemistry was done in 17 cases which helped in reaching the diagnosis. IHC was done in 6 cases of metastatic adenocarcinoma, 7 cases of hepatocellular carcinoma and 4 cases of cholangiocarcinoma. Out of 6 cases of metastatic adenocarcinoma, breast was primary site of metastasis in 3 cases and lung was primary site of metastasis in 3 cases. IHC panel as advised depending on the type of lesion. In cases of suspected metastasis from breast, ER, PR, and Her2neu was done. In cases of suspected metastasis from lung, CK5/6, TTF-1 was done. In cases of primary hepatic malignancy, IHC panel comprising of HepPar-1, CEA, CK 7, CK 19, CK 20, EMA was done. IHC was advised in all the cases of malignancy but out of 52 cases, it was done in only 17 cases. In some cases, tissue was insufficient for IHC, while in some cases patients were not willing for the tests or the patients lost to follow up.

5. Conclusion

Liver biopsy is an essential, safe, reliable and most important investigation in reaching accurate diagnosis, detecting cause & severity of liver diseases, follow up and in providing better treatment options. Microscopic examination of liver biopsy yields a diverse range of pathological findings. Considering the value and safety of liver biopsy procedure, and the current limitations of noninvasive tests, liver biopsy will continue to remain as the cornerstone and the gold standard test in the assessment of liver diseases.

6. Source of Funding

None.

7. Conflicts of Interest

There is no conflict of interest.

References

1. Murgod PS, Doshi PR, Dombale VD. Spectrum of hepatic lesions- A histopathological study of liver biopsies. *J Diagn Pathol Oncol.* 2019;4(3):200–3.

2. Chawla N, Sunila S. Spectrum of histopathological findings in liver biopsy. *Indian Med Gaz.* 2014;67(5):292–6.
3. Zahir ST, Aalipour E, Vakili M, Gane MD. Clinicopathological features of liver tumours: A Ten-year Study. *J Ayub Med Coll Abbottabad.* 2015;27(4):775–9.
4. Agrawal NS, Iqbal MB, Patil AA, Karia KM, Kumar H. Study to Evaluate the Histopathological Spectrum of Hepatic Lesions in Liver Biopsies in a Tertiary Care Hospital. *Ann Pathol Lab Med.* 2018;5(3):228–33. doi:10.21276/APALM.1667.
5. SGandhi, Khajuria A, Goswami KC. Histomorphological Spectrum of Hepatic Lesions in Liver Biopsies – A Prospective Hospital Based Study. *JMSCR.* 2018;6(7):322–5. doi:10.18535/jmscr/v6i7.54.
6. Kulkarni MP, Sulhyan KR, Yadav DH, Anantwar SH. Dr Deepika Hanumanprasad Yadav, Dr Snehal Hanmantrao Anantwar. Histopathological Analysis of Liver Lesions in 80. *JMSCR.* 2018;6(6):883–90. doi:10.18535/jmscr/v6i6.148.
7. Parekh PJ, Majithia R, Diehl DL, Baron TH. Endoscopic ultrasound-guided liver biopsy. *Endosc Ultrasound.* 2015;4(2):85–91.
8. Kumar V, Abbas AK, Aster JC. Robbins & Cotran Pathologic Basis of Disease. vol. 2020. Elsevier;. p. 856–66.
9. Desmet VJ, Liver JR. Rosai and Ackerman's surgical pathology. Milan: Elsevier; 2012. p. 857–65.
10. Gall EA. Posthepatic, post necrotic and nutritional cirrhosis: A Pathologic analysis. *Am J Pathol.* 1960;36(3):241–71.
11. Macsween RNM, Scott AR. Hepatic cirrhosis: A Clinicopathological review of 520 cases. *J Clin Pathol.* 1973;26(12):936–42. doi:10.1136/jcp.26.12.936.
12. Hamilton S, Aaltonen L. World Health Organisation Classification of Tumours. Pathology and Genetics of Tumours of the Digestive system. Lyon: IARC Press; 2000.
13. Henriques MSM, Li EX. The Liver and Polycystic Kidney Disease. In: Li X, editor. Polycystic Kidney Disease. Brisbane (AU). Codon Publications; 2015.

Author biography

Vidhi P. Patel, 3rd Year Post Graduate Resident

Sadhana L. Kothari, Associate Professor

Anupama I. Dayal, Associate Professor

Naimish A. Patel, Professor

Sushil D. Akruwala, Professor

Cite this article: Patel VP, Kothari SL, Dayal AI, Patel NA, Akruwala SD. Evaluation of histopathological spectrum of hepatic lesions in liver biopsies in a tertiary care hospital. *Panacea J Med Sci* 2022;12(3):690-695.