



Original Research Article

Clinical presentation of orbital mucormycosis in North –West Rajasthan: An observational study

Rashmi Joshi¹, Dinesh Kumar Yadav¹, Lakshita Maherda¹, Poonam Bhargava^{1,*}, Gargi Sharma¹, Shilpa Jangir¹

¹Dept. of Ophthalmology, Sardar Patel Medical College, Bikaner, Rajasthan, India



ARTICLE INFO

Article history:

Received 09-07-2021

Accepted 05-10-2021

Available online 17-08-2022

Keywords:

Mucormycosis

Covid 19

Immunosuppression

Ocular manifestation

ABSTRACT

Introduction: India has witnessed severe complications after the second wave of global covid 19 pandemic. The new covid virus variant is so much lethal that it causes severe immunodepression in the covid survivors, and makes them prone to the opportunistic and rare mucormycosis infection.

Objective: To see the spectrum of ocular manifestations in the patients of post Covid 19 mucormycosis.

Materials and Methods: This was an observational study, carried out at tertiary care centre in North - West Rajasthan. Patients of mucormycosis during second wave of covid 19 pandemic in the month of April and May were included in the study. covid was diagnosed either by reverse transcriptase polymerase chain reaction (RT-PCR) / high resolution computed tomography HRCT. Routine blood investigation, contrast enhanced magnetic resonance imaging (CEMRI) of paranasal sinuses, orbit and brain was done. Pottassium hydroxide (KOH) mount of nasal swab/biopsy was done for confirmation. Thorough ocular examination was done according to the preformed proforma.

Result: Out of 61 patients of mucormycosis, 47 patients had ocular involvement varying from common symptoms like lid edema, chemosis, proptosis to sight threatening central retinal artery occlusion (CRAO), Orbital Apex Syndrome and Panophthalmitis. A rare presentation of corneal ulcer and corneal eschar was also seen.

Conclusion: Rhino orbital cerebral mucormycosis is a vision and life threatening opportunistic infection. A high index of clinical suspicion and early diagnosis with multi-disciplinary approach for the treatment can save the life of the patient.

This is an Open Access (OA) journal, and articles are distributed under the terms of the [Creative Commons Attribution-NonCommercial-ShareAlike 4.0 License](https://creativecommons.org/licenses/by/4.0/), which allows others to remix, tweak, and build upon the work non-commercially, as long as appropriate credit is given and the new creations are licensed under the identical terms.

For reprints contact: reprint@ipinnovative.com

1. Introduction

Mucormycosis is one of the rare, opportunistic and life threatening disease.¹ Higher incidence of morbidity and mortality can be attributed to it's angio-invasive property.² Fungi which are responsible for disease in humans are saprophytes in nature, causing infection when airborne spores reach the lungs or paranasal sinuses or when hyphae or spores are inoculated directly into the skin or cornea.³ Mucor, rhizopus, Rhizomucor, Absidia are responsible for

infection. It is evident that mucormycosis occurrence is more prevalent in patients who have history of diabetes/diabetic ketoacidosis, prolonged immunosuppression, organ transplantation, haematologic malignancies, long term receiver of desferoxamine, and chronic debilitating disease.⁴ Covid -19 which is a known global pandemic, had led to the severe immunosuppression and causes loss of β islet cells, makes a patient prone either to frank diabetes or uncontrolled blood sugar levels and with the injudicious use of steroids and oxygenation, the number of rhino orbital mucormycosis are roaring, and still the count is on in India.⁵ Since mucor involves primarily paranasal sinuses.⁶

* Corresponding author.

E-mail address: pbrc1306@gmail.com (P. Bhargava).

and eyes being the nearest neighbor has to suffer the most. In our study we had studied the epidemiological profile and ocular involvement in the patients of mucormycosis during second wave of the covid 19 pandemic admitted in special mucor ward at our college. There is a bouquet of ocular involvement in mucormycosis varying from mild lid edema, to the severe vision threatening central retinal artery occlusion.⁷⁻⁹

2. Materials and Methods

This was an observational study, carried out at tertiary care centre in North - West Rajasthan. Patients of mucormycosis during second wave of covid 19 pandemic in the month of April and May were included in the study. Diagnosis of covid was made by either positive RT-PCR or HR CT findings classical of covid 19. On the day of the admission detailed eye examination was done including the visual status, pupillary reaction, fundus examination and extra ocular movements. Detailed history of any prolonged systemic illness, immunosuppressive drug use, treatment given during covid period, oxygenation, covid vaccination status and Occupational history were recorded in a preformed proforma. Complete blood count (CBC), fasting blood sugar (FBS), HbA1c, renal function test, liver function test were done. Nasal swab/ biopsy for KOH mount and contrast enhanced MRI (CEMRI) was done for paranasal sinuses, orbit and brain. Fundus photography was also done in the ambulatory patients who had posterior segment involvement. Moxifloxacin 0.5% eye drop and carboxy methyl cellulose 0.5% were started in all patients. Treatment with iv liposomal amphotericin B was started after the confirmation of mucormycosis, and necessary intervention like functional endoscopic sinus surgery (FESS) for sinus debridement and exenteration was also done to decrease the fungal load and to save the life of the patients. Written consent was taken from all patients and relatives. The study was approved by Institutional Ethics and Research committee. The chi square test was done for statistical analysis.

3. Result

Sixty one patients of mucormycosis were included in our study. The disease was predominantly present in males (44 out of 61; 72.13%), with predominant age group of 31-40 year (29.54%). Occupation wise 35 patients were involved in outdoor activities with highest number of farmers (24 out of 35). (Table 1). Diabetes mellitus itself was an important factor for the predisposition of mucormycosis, 36 (59.01%) patients had diabetes, out of them 23(63.88%) patients had ocular manifestations. (p value <0.05). (Table 2). Three (4.91%) patients had history of coronary artery disease. Thirteen patients had immunocompromised diseases other than diabetes mellitus (Table 3).

Table 1: Distribution of mucormycosis patients according to their occupation

S.No.	Outdoor worker	No. of patients	Indoor worker	No. of patients
1.	Farmer	24 (39.34%)	Housewife	17 (27.86%)
2.	Labourer	6 (9.83%)	Student	3 (4.91%)
3.	Driver	1 (1.63%)	Non-working	3 (4.91%)
4.	Guard	1 (1.63%)	Retired	2 (3.27%)
5.	Sales executive	1 (1.63%)	Shop keeper	1 (1.63%)
6.	CA	1 (1.63%)		
7.	Tehsildar	1 (1.63%)		
8.	-	-		
Total	35		26	

Table 2: Diabetes in mucormycosis and ocular involvement

S.No.	H/o of diabetes		Ocular involvement		X ² value	P value
			Present	Absent		
1.	Present	36	23	13	2.3657	Significant <0.05
2.	Absent	25	18	17		

Table 3: Ocular involvement in immunocompromised (excluding diabetes) patients of mucormycosis

S.No.	Immunocompromised status	No of patients	Ocular involvement
1.	Acute lymphoblastic leukemia (ALL)	1	0
2.	Diffuse large Bcell lymphoma (DLBL)	1	0
3.	Tuberculosis	4	4
4.	Chronic kidney disease on dialysis	2	2
5.	thyrotoxicosis	1	0
6.	Severe anemia	1	1
7.	Renal transplant	1	1
8.	Hepatitis C positive	2	2
	Total	13	11

No significant relationship is present between ocular involvement in mucormycosis and steroid use during covid treatment (12 out of 23; p value >0.05). History of oxygen use during covid treatment was present in 20(32.78%) patients and out of them 13(65%) patients had ocular involvement, this was also statistically non-significant (p value >0.05). Out of 61 patients of mucormycosis only three patients were fully vaccinated for Covid and presented with only cutaneous involvement. Covid vaccination status of patients are detailed in. Microscopically, on KOH mounting of the sample taken from nasal mucosa, aseptate branched

hyphae were seen in majority of patients (57) while in four patients yeast cells were seen.

Unilateral eye involvement was seen in 39 patients, while eight patients had bilateral involvement. Ocular involvement was absent in 14 patients at the time of presentation. Out of 47 patients, 8 (17.02 %) patients had lid edema and seven (14.89%) patients had orbital cellulitis, six (12.76%) had optic neuritis. Five patients (10.63%) each were of central retinal artery occlusion (CRAO) and ischemic optic atrophy. Four patients (8.51%) had orbital apex syndrome, three patients (6.38%) had unilateral ophthalmoplegia, while panophthalmitis and lateral rectus palsy was seen in two patients (4.25%) each. One patient (2.12%) each had corneal ulcer, corneal eschar and exposure keratopathy. Whereas conjunctival chemosis was present in two patients.(Figure 1). Three patients presented with facial paralysis and three with palatal eschar.

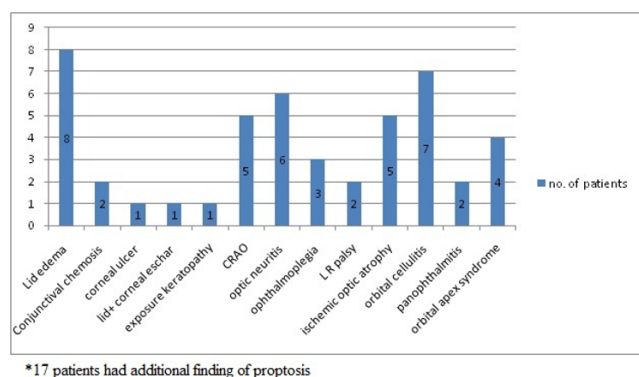


Fig. 1: Ocular manifestations in patients of mucormycosis.

According to the visual status of the involved eye 27(44.26%) patients had visual acuity of range 6/60 – 6/24, 17 (27.86 %) patients had absent perception of light (PL)at the time of presentation, 14 patients (22.95%) had vision between 6/18-6/6 and three (4.91%) had visual status of PL present - <6/60 (Table 4). Amongst 17 patients who had absent PL, only seven patients gave consent for exenteration of orbit, remaining patients were managed by retrobulbar injection of Amphotericin B 3.5mg/ml for five-seven days with FESS and sinus irrigation of the same by ENT surgeon. Four patients presented with cavernous sinus involvement eventually deteriorated and died.

Table 4: Visual status in patients of mucormycosis

S.No.	Visual status in the involved eye	No of patients
1	PL Absent	17 (27.86%)
2	PL+ - <6/60	3 (4.91%)
3	6/60- 6/24	27 (44.26%)
4	6/18- 6/6	14 (22.95%)

4. Discussion

Mucormycosis is a fulminant, rare, fungal infection caused by molds of order mucorales.¹⁰⁻¹³ It causes an inflammation of the nasal and paranasal sinuses,that spreads to the neighbouring structures and causes a condition known as Rhino Orbital Cerebral Mucormycosis (ROCM).¹⁰⁻¹² ROCM is the third most common fungal infection after Candida and Aspergillus affecting mainly immunocompromised person.¹² Cutaneous, pulmonary, gastrointestinal, disseminated and isolated renal are the other forms of mucormycosis.¹⁴

Predominantly males and person involved in outdoor activities like farmers were affected in our study. The fungus is ubiquitous in nature and found in soil and on decaying vegetation; so persons involved in agricultural activities are more involved by inhalation of spores through nose and mouth.¹⁵

The commonest predisposing factor for mucormycosis is uncontrolled Diabetes Mellitus (DM),accounting for 36% of total infection, with clinical presentation observed in 60-80% patients of Diabetic Ketoacidosis.^{16,17} In our study out of 61 patients 36 had h/o uncontrolled DM. Ocular involvement was found in 23 patients. Similar results were also seen in a study conducted by Yohai et al, Ferry AP et al.^{18,19} Fungal colonies are nourished by hyperglycemic status and metabolic acidosis by interfering neutrophilic phagocytosis and increasing unbound iron.¹²

Thirteen patients in our study had history of immunocompromised diseases other than DM out of them 11 had ocular manifestations. Another proposed mechanism for development of ROCM other than immunocompromised state and steroid use is unhygienic delivery of oxygen (O₂) to the Covid patients. However in our study we have found no significant relation between oxygen therapy and ROCM.

In ROCM infection starts in maxillary sinus and invades, the orbit through ethmoid formina or naso lacrimal duct or via dehiscence of the lamina papyracea.^{10,11,20} After invasion fungus can affect optic nerve,medial rectus muscle and orbital apex structures causing ocular discomfort and conjunctival chemosis leading to proptosis, ophthalmoplegia and vision loss{orbital apex syndrome – OAS}.^{10-13,21,22} In our study four patients had features of OAS. Invasion of superior orbital fissure just anterior to orbital apex can cause ophthalmoplegia without visual loss, it was observed clinically in three patients of our study. Decreased vision was observed in 47 patients of ROCM in our study, 17 patients had proptosis in combination with various other manifestations.

In our study we observed two rare presentations of mucormycosis fungal corneal ulcer and corneal eschar formation. Fungal corneal ulcer is very common in immunocompromised persons and after steroid use.²³ The patient was on steroid therapy at the time of presentation and found KOH positive for aseptate hyphae in nasal swab

and corneal scraping. The patient had invasive ROCM with right cavernous sinus thrombosis with frontal lobe abscess on CEMRI. To the best of our knowledge only one case of mucormycosis ulcer have been reported so far.²⁴

The other rare presentation was lid and corneal eschar formation seen in one patient. The mucor has a property of soft tissue and angio- invasion. A devastating effect on local tissue is created by these two processes. It invades the lumen of blood vessel, proliferating aseptate hyphae block the lumen, interrupt the perfusion and cause thrombosis. Various released mycotoxins, fungal proteases, lipases cause infarction and tissue necrosis forming a black necrotic eschar, commonly found on nasal turbinate, hard palate.^{10,11,13,21} Our patient had left lower lid eschar formation along with the involvement of the cornea (Figure 2). Lid edema, proptosis, chemosis and orbital cellulitis were the associated findings in this patient causing vision loss.

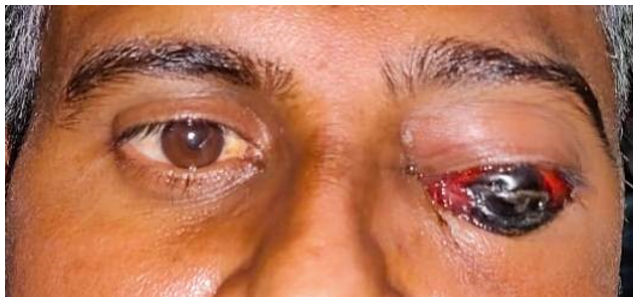

Fig. 2: Lid and corneal eschar

Central Retinal Artery Occlusion (CRAO) is a rare manifestation of orbital mucormycosis with an incidence of 16-20%. It is caused by direct infiltration of central retinal artery by angio- invasive fungal infection.¹² In our study we had five patients of CRAO, all of them presented with sudden visual loss. Vascular invasion of hyphae, results in thrombosing vasculitis which causes vascular obstruction and resultant tissue necrosis (Figure 3). Besides CRAO thrombosis of posterior ciliary arteries, infarction of intra orbital part of optic nerve can cause sudden loss of vision,¹⁶ which was seen as ischemic optic atrophy in five patients of our study.

Orbital infiltration of mucor can lead to varying features like lid edema, chemosis, optic neuritis, orbital cellulitis and panophthalmitis. Optic Neuritis was seen in six patients. Panophthalmitis was seen in two patients in our study which is also a rare presentation (Figure 4). The infection can spread from orbit to brain via cribriform plate or orbital apex.²⁵ (Figure 5) Involvement of cavernous sinus and cavernous part of carotid artery causes carotid occlusion, cerebral infarction, meningitis, mycotic abscess formation and death.²⁶ Four patients died due to cerebral involvement during the course of our study.

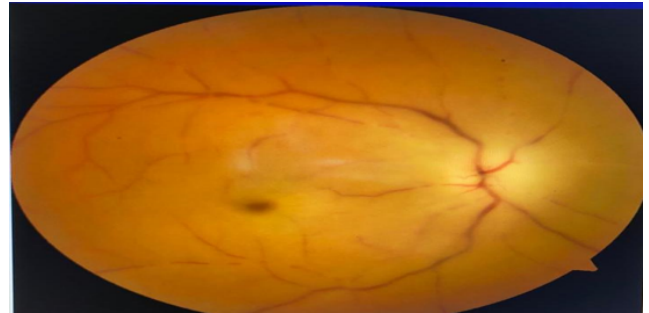


Fig. 3: Fundus photograph of CRAO

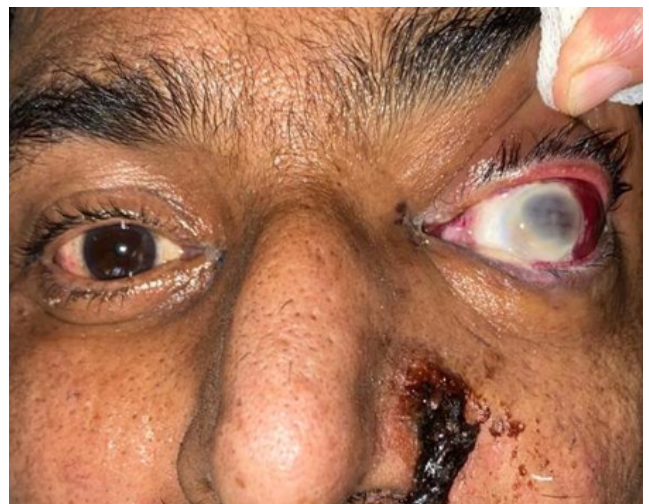

Fig. 4: Panophthalmitis in patient of mucormycosis

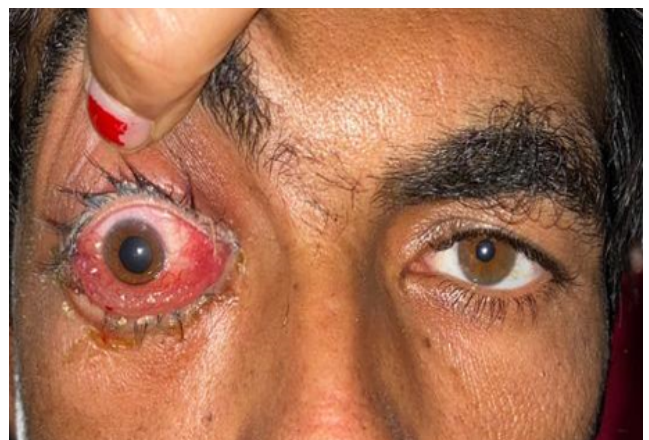

Fig. 5: Clinical presentation of OAS

Forty three affected by mucormycosis had not received vaccination for covid, while 15 patients received single dose. Interestingly three fully vaccinated patients had only cutaneous mucormycosis probably suggesting protective role of vaccination against ROCM.

5. Conclusion

Mucormycosis / ROCM is a potentially life threatening fungal infection emerging as an epidemic in the Covid 19 pandemic adding to it's death toll. It typically affects patients recovering from covid who are immunocompromised due to covid or by the use of steroid and / concomitant Diabetes. The common presenting symptoms of mucormycosis are nasal discharge, facial palsy, facial hypoesthesia and ocular manifestations varying from mild lid edema, chemosis, proptosis to OAS, CRAO and sudden vision loss at the time of presentation. It is extremely important to have a high rate of suspicion for ROCM among post Covid patient regarding these symptoms. Prompt diagnosis and early surgical debridement along with management of systemic pre disposing factors are critical to arrest the intra cranial spread of this fatal disease.

6. Conflicts of Interest

No potential conflict of interest relevant to this article was reported.

7. Source of Funding

None.

References

1. Rootman J. Inflammatory diseases. In: Diseases of the Orbit. 2nd Edn. Philadelphia: Lippincott Williams & Wilkins; 2003.
2. Mititelu R, Bourassa-Blanchette S, Sharma K, Roth V. Angioinvasive mucormycosis and paradoxical stroke: a case report. *JMM Case Rep.* 2016;3(4):e005048. doi:10.1099/jmmcr.0.005048.
3. Bennet JE. Diagnosis and treatment of fungal infections. In: Kasper DL, Braunwald E, Fauci AS, Hauser SL, Longo DL, Jameson JL, et al., editors. Harrison's Principles of Internal Medicine. 16th Edn. New York: Mc Graw Hill; 2005. p. 1176–9.
4. Waness A, Dawsari A, Jahdali HA. The Rise of an Opportunistic Infection called "Invasive Zygomycosis. *J Glob Infect Dis.* 2009;1(2):131–8.
5. Tian W, Zhang N, Jin R, Feng Y, Wang S, Gao S, et al. Shuaixin Gao et al. Immune suppression in the early stage of COVID-19 disease. *Nat Commun.* 2020;11(1):5859. doi:10.1038/s41467-020-19706-9.
6. Ruoppi P, Dietz A, Nikanne E, Seppä J, Markkanen H, Nuutinen J, et al. Paranasal Sinus Mucormycosis: A Report of Two Cases. *Acta Oto Laryngologica.* 2001;121(8):948–52.
7. Prakash M, Kumar PA, Umamaheswari TG, Harivanzan V. The clinical pattern of orbital mucormycosis in a tertiary eye care hospital. *TNOA J Ophthalmic Sci Res.* 2020;58(1):14–6. doi:10.4103/tjosr.tjosr_102_19.
8. Veisi A, Bagheri A, Eshaghi M, Rikhtehgar MH, Kanavi MR, Farjad R, et al. Rhino-orbital mucormycosis during steroid therapy in COVID-19 patients: A case report. *Eur J Ophthalmol.* 2020;32(4):NP11–6. doi:10.1177/11206721211009450.
9. Honavar, Santosh G. Guidelines for the Diagnosis, Staging and Management of Rhino-Orbital-Cerebral Mucormycosis in the Setting of COVID-19. *Indian J Ophthalmol.* 2021;69(6):1361–5. doi:10.4103/ijo.IJO_1165_21.
10. Martin-Moro JG, Calleja JML, Garcia MB. Rhino-orbitocerebral mucormycosis: A case report and literature review. *Med Oral Patol Oral Cir Bucal.* 2008;13(12):792–5.
11. Anders U, Taylor E, Martel J, Martel J. Acute orbital apex syndrome and rhino-orbital-cerebral mucormycosis. *Int Med Case Rep J.* 2015;8:93–6. doi:10.2147/IMCRJ.S83036.
12. Eucker J, Sezer O, Graf B, Possinger K. Mucormycoses. *Mycoses.* 2001;44(7-8):253–60.
13. Bhansali A, Bhadada S, Sharma A, Suresh V, Gupta A, Singh P, et al. Presentation and outcome of rhino-orbital-cerebral mucormycosis in patients with diabetes. *Postgrad Med.* 2004;80(949):670–4. doi:10.1136/pgmj.2003.016030.
14. Kauh CY, Nelson CC. Diagnosis and Management of Orbital Mucormycosis. *EyeNet Magazine.* 2014; Available from: <https://www.aaopt.org/eyenet/article/diagnosis-management-of-orbital-mucormycosis>.
15. Mukherjee B, Raichura ND, Alam S. Fungal infections of the orbit. *Indian J Ophthalmol.* 2016;64(5):337–45.
16. Roden MM, Theoklis E, Zaoutis WL, Buchanan TA, Knudsen TA, Sarkisova RL, et al. Epidemiology and outcome of zygomycosis: A review of 929 reported cases. *Clin Infect.* 2005;41(5):634–53.
17. Yohai RA, Bullock JD, Aziz AA. Survival factors in rhino - orbital - cerebral mucormycosis; major review. *Surv Ophthalmol.* 1994;39(1):3–22. doi:10.1016/s0039-6257(05)80041-4.
18. Ferry AP, Abedi S. Diagnosis and management of rhino-orbitocerebral mucormycosis (phycomycosis): a report of 16 personally observed cases. *Ophthalmology.* 1983;90(9):1096–104. doi:10.1016/s0161-6420(83)80052-9.
19. Sravani T, Uppin SG, Uppin MS, Sundaram C. Challa Sundaram Rhinocerebral mucormycosis: Pathology revisited with emphasis on perineural spread; Neurol India. *Neurol India.* 2014;62(4):383–6. doi:10.4103/0028-3886.141252.
20. Shatriah I, Mohd-Amin N, Tn TJ. Rhino-orbital-cerebral mucormycosis in an immunocompetent patient: case report and review of literature. *Middle East Afr J Ophthalmol.* 2012;19(2):258–61.
21. Gamaletsou MN, Sipsas NV, Roilides E, Walsh TJ. Rhino-orbital-cerebral mucormycosis. *Current Infect Dis Rep.* 2012;14(4):423–34.
22. Srinivasan M. Fungal keratitis. *Curr Opin Ophthalmol.* 2004;15(4):321–7.
23. Maria DL, Deshpande SP, Kamble BS. Keratomycosis (A case report due to Mucormycosis). *Indian J Ophthalmol.* 1979;27:55–6.
24. Badakere A, Patil-Chhablani P, 1, 2. Orbital Apex Syndrome: A Review. *Akshay Badakere and Preeti Patil-Chhablani Orbital Apex Syndrome: A Review Eye Brain.* 2019;11:63–72.
25. Bae MS, Kim EJ, Lee KM, Choi WS. Rapidly Progressive Rhino-orbital-cerebral Mucormycosis Complicated with Unilateral Internal Carotid Artery Occlusion: A Case Report. *Neurointervention.* 2012;7(1):45–54. doi:10.5469/neuroint.2012.7.1.45.
26. Thurtell MJ, Chiu AL, Goold LA, Akdal G, Crompton JL, Ahmed R. Neuro-ophthalmology of invasive fungal sinusitis: 14 consecutive patients and a review of the literature. *Clin Experiment Ophthalmol.* 2013;41:567–76.

Author biography

Rashmi Joshi, Associate Professor

Dinesh Kumar Yadav, Resident

Lakshita Maherda, Resident

Poonam Bhargava, Assistant Professor

Gargi Sharma, Resident

Shilpa Jangir, Resident

Cite this article: Joshi R, Yadav DK, Maherda L, Bhargava P, Sharma G, Jangir S. Clinical presentation of orbital mucormycosis in North–West Rajasthan: An observational study. *Panacea J Med Sci* 2022;12(2):374-379.