



## Original Research Article

## Evaluation of vulval masses

Pawar Kalyani S<sup>1</sup>, Shilpa Chaudhari<sup>1,\*</sup>, Shastri Shraddha<sup>1</sup>, Hol Kishorkumar<sup>1</sup><sup>1</sup>Dept. of Obstetrics and Gynecology, Smt. Kashibai Navale Medical College and General Hospital, Narhe, Pune, Maharashtra, India

## ARTICLE INFO

## Article history:

Received 07-03-2021

Accepted 03-06-2021

Available online 24-11-2021

## Keywords:

Benign vulval masses

Neurofibroma

Angiofibroma

Fibroepithelial

Bowen's disease

## ABSTRACT

In last few decades number of vulval lesions are increased. Patients came with complaints of itching, burning, or swelling. Although benign vulval masses are an uncommon condition of the lower genital tract, it is important to consider these tumors in the differential diagnosis of vulval complaints. Very few studies are done for benign vulval masses.

**Aim:** To study various vulval masses and their prevalence in patients operated in tertiary care center.

**Materials and Methods:** We conducted 5 years retrospective observational study of benign vulval masses in our hospital. Total 50 cases were operated which were included in the study.

Data collection was done from the Indoor patient department & Operation Theatre Register.

**Results:** In this study maximum cases were from age group 21–40 years. Bartholin cyst was most common pathology followed by Inclusion cyst & Gartner's cyst. Rare cases of vaginal mass like Neurofibroma of vulva, Angiofibroma of vulva, Fibroepithelial polyp of labia & Bowen's disease were also seen.

**Conclusion:** This study helps us to get an insight of various benign vulval masses and there prevalence.

This is an Open Access (OA) journal, and articles are distributed under the terms of the [Creative Commons Attribution-NonCommercial-ShareAlike 4.0 License](https://creativecommons.org/licenses/by-nc-sa/4.0/), which allows others to remix, tweak, and build upon the work non-commercially, as long as appropriate credit is given and the new creations are licensed under the identical terms.

For reprints contact: [reprint@ipinnovative.com](mailto:reprint@ipinnovative.com)

## 1. Introduction

Recently number of patients complaining of vulval lesions are increased. Although benign vulval mass are an uncommon condition of the lower genital tract, it is important to consider these tumors in the differential diagnosis of vulval complaints. These disorders include vulval atrophy, benign tumors, hamartomas, and cysts, infections disorders, and nonneoplastic epithelial disorders.<sup>1</sup> Benign tumors of the vulva are relatively uncommon and may show nonspecific findings and therefore a biopsy is often needed to exclude malignancy. Many benign vulval tumors are asymptomatic and are found only on self-examination. Smooth muscle tumors are rare in vulva. In this study we will discuss cases

presenting with different types of vulval mass with different clinical features. This study will include cases which were operated in our tertiary care center. We aim to create awareness regarding the vulval diseases and its need for early diagnosis and treatment.<sup>2</sup>

## 2. Objectives

1. To study prevalence of benign vulval masses in patients operated in tertiary care center.
2. To study various vulval masses.
3. To create awareness in the society.

## 3. Materials and Methods

We conducted 5 years retrospective observational study of benign vulval masses in our hospital. Total 50 cases were operated which was included in the study.

\* Corresponding author.

E-mail address: [drshilpachaudhari15671@gmail.com](mailto:drshilpachaudhari15671@gmail.com) (S. Chaudhari).

Data collection was done from the Indoor patient department & Operation Theatre Register.

And was analysed statistically.

**3.1. Place**

This study was carried out in the Department of Obstetrics and Gynecology, Smt Kashibai Navale Medical College & General Hospital, Narhe, Pune.

**3.2. Time period**

January 2016 to December 2020

**3.3. Inclusion criteria**

All vulval masses operated during study period.

**3.4. Exclusion criteria**

1. Cases of vulvovaginitis.
2. Cases of trauma at vulva causing hematoma

**3.5. Drawbacks of this study**

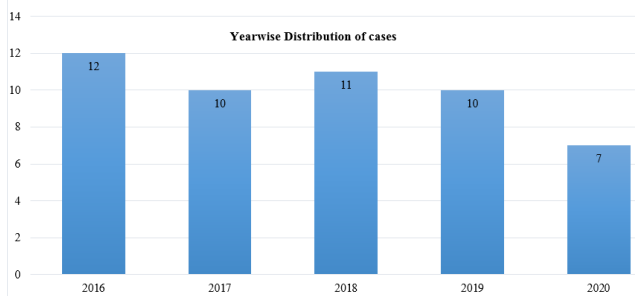
Follow up of cases is not taken so recurrence of disease is not known.

1. Approved by Ethical Committee

**4. Results**

**Table 1:** Number of cases

Year	No. of Cases (Total - 50)	Percentage (%)
2016	12	24
2017	10	20
2018	11	22
2019	10	20
2020	7	14

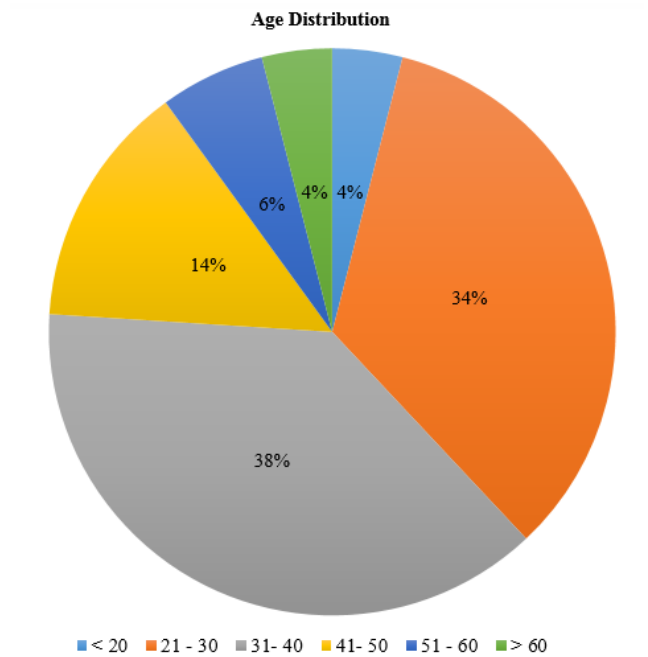


**Graph 1:** Year wise Distribution of cases

In 5 years of study period total 50 surgeries were performed in our tertiary care center for benign vulval masses. Out

**Table 2:** Age group wise distribution of cases

Age group (years)	No. of cases	Percentage (%)
10 – 20	02	04
21 – 30	17	34
31 – 40	19	38
41 – 50	07	14
51 – 60	03	06
≥ 61	02	04



**Graph 2:** Pie chart of age distribution

**Table 3:** Vulval masses distribution

Vulval masses	No of cases	Percentage (%)
Bartholin Cyst	28	56
Vulval abscess	02	04
Gartner’s cyst	04	08
Antibioma	01	02
Vulval lipoma	02	04
Vulval nodule	01	02
Inclusion cyst	08	16
Bowen disease (Vulval erosions)	01	02
Neurofibroma of vulva	01	02
Angiofibroma of vulva	01	02
Fibroepithelial polyp of labia	01	02

of that maximum number of cases (total 36 cases) were from age group 21 – 40. Less number of cases seen in both extremities of ages. Bartholin cyst (56%) was most common pathology in this study followed by Inclusion cyst (16%) and Gartner's cyst (08%). Rare cases of vaginal mass like Neurofibroma of vulva, Angiofibroma of vulva, Fibroepithelial polyp of labia & Bowen's disease are also seen.

## 5. Discussion

### 5.1. Bartholin cyst

Bartholin's gland also known as greater vestibular gland's most common pathology is cyst formation also known as Bartholinitis which may infected and abscess formation takes place. These cysts and abscesses are the most common gynecological cystic disease of the vulva all over the world.<sup>3</sup> Approximately 2% of women in the world, between age group 15-45 years would develop Bartholin's gland cyst or abscess.<sup>4</sup> Obstructed Bartholin duct causes accumulation of secretions which results in formation of cyst. When this cyst became infected, abscess formation takes place.<sup>5</sup> Simple and quick method of providing relief for a patient is an incision and drainage of the infected area followed by a suture closure; however, this method is prone to recurrence of cyst or abscess formation.<sup>6</sup> Sitz baths are recommended for abscesses that tend to spontaneously rupture.

### 5.2. Gartner cyst

The vestigial remnant of the mesonephric duct in females called Gartner's duct. Gartner cysts or mesonephric cysts of vagina originate as a consequence of the obstruction of the Gartner duct, located on the anterolateral wall of the vagina. These ducts cysts are benign lesions.<sup>7</sup> These Gartner's duct cysts are most common in females between the ages 21-75 years, maximum number of cases seen between age group 30-40 years.<sup>8</sup> The Gartner duct cysts account for nearly 12% of all vaginal cysts.<sup>8</sup> Risk factors for these cysts are vaginal birth delivery trauma, gynaecological procedure like colposcopy. Most commonly cysts form during pregnancy and regress after delivery, Excision may be needed if cysts persists.<sup>8</sup> Surgical excision was performed in all symptomatic cases.<sup>9</sup>

### 5.3. Neurofibroma

Neurofibroma of vulva is rare benign tumour. Vulval neurofibroma makes up to 5% of all benign vulval lesions.<sup>10</sup> Neurofibromatosis, the most common type of neurocutaneous syndrome, includes two conditions which are clinically and genetically separated, with an autosomal dominant pattern of inheritance.<sup>11</sup> Neurofibromatosis type 1 (NF1), also called von Recklinghausen's neurofibromatosis,

is the most common type which is caused by mutations in the NF1 gene on chromosomes 17, half of which are new mutations. NF1 is characterized by neurofibromas (benign peripheral nerve connective tissue tumor) and café-au-lait spots, it may affect numerous other systems.<sup>11</sup> Vulval involvement in women with NF1 is seen in about 18%, while approximately half of all vulval neurofibromas are seen in women with NF1.<sup>12</sup> Neurofibromas which involves the female reproductive system commonly involves the clitoris and the labia but it may also affect the vagina, cervix, endometrium, myometrium and ovary, it may be associated with urinary tract NF.<sup>13</sup> vulval neurofibroma most commonly seen with trauma to the perineum such as episiotomies or other vulval injuries.<sup>14</sup> This was case of 45 year old, post-menopausal, known case of NF1 since birth, with vulval mass since 10 years which increased rapidly in 3-4 months. In this case there was no malignant changes and surgical excision was therapeutic treatment. Histopathological examination reported neurofibroma of the vulva.

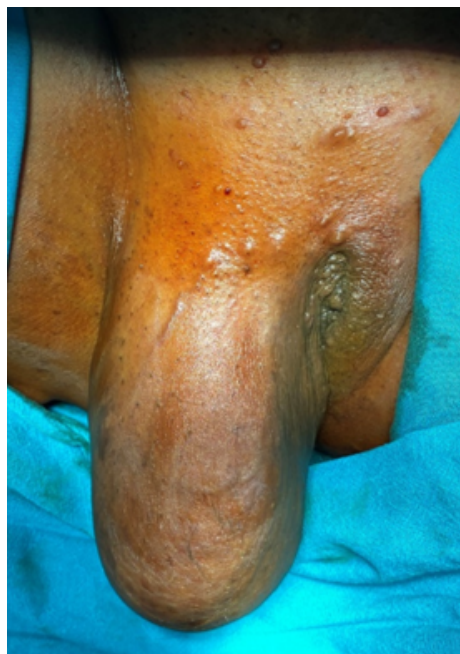

Fig. 1: Neurofibroma of vulva

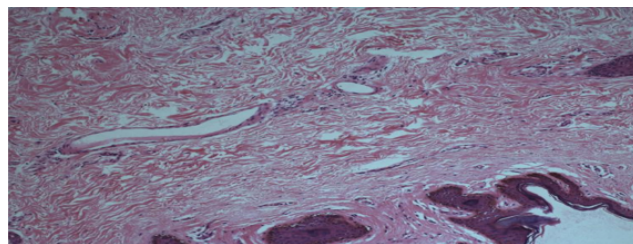
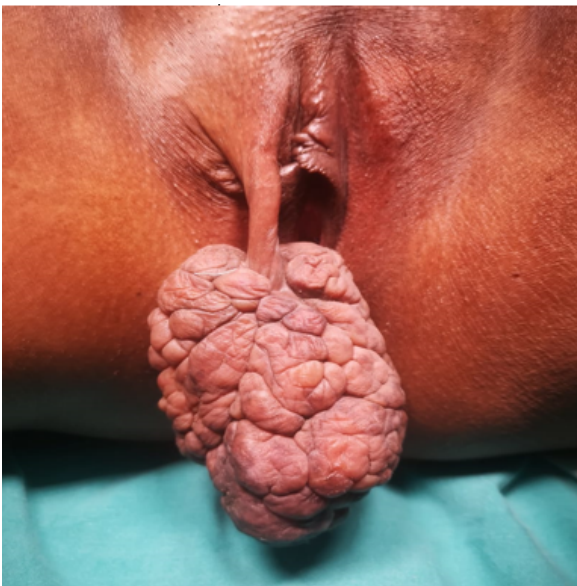

Fig. 2: Histopathological picture of Neurofibroma

Histopathological report – Vulval mass showing hypocellular proliferation of bland spindle cells with interspersed “Shredded carrot collagen”.

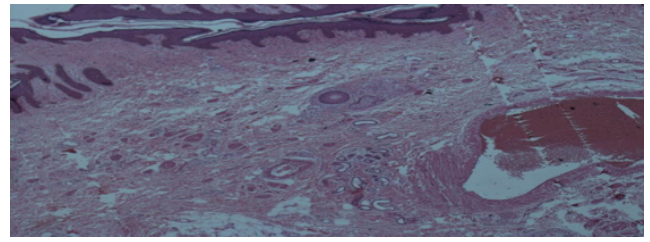
#### 5.4. Fibroepithelial Polyp

Fibroepithelial polyps also known as Acrochordons, skin tags, papillomas, which are the type of mesenchymal tumor that typically occurs in women of reproductive age group. They are mostly small in size and histologically benign.<sup>15,16</sup> Larger lesions are rare, which are proliferation of mesenchymal cells that are hormonal sensitive subepithelial stromal layer of the lower genital tract.<sup>16</sup> Associated with rare autosomal dominant disorder called Birt-Hogg-Dube syndrome.<sup>16</sup> These are most common benign tumor which occurs in obese adult women with an average of 46% incidence in the general population.<sup>17</sup> These site-specific polyps most commonly seen around neck, axilla & perineal areas and have a preference for perineal area. These polyps associated with known family history, diabetes mellitus and obesity. Mostly asymptomatic, but friction from clothing results in pruritus, inflammation which can be painful. Excision of mass is done mostly because of cosmetic purpose. Our case was of 35 year old female, Para1 Living 1, with a huge polypoidal mass of the vulva since 5 years, on the right side labia majora, measuring about 8x10 cm. Surgical excision of the mass was done. Histopathological examination reported a fibroepithelial stromal polyp of the vulva.



**Fig. 3:** Fibroepithelial polyp

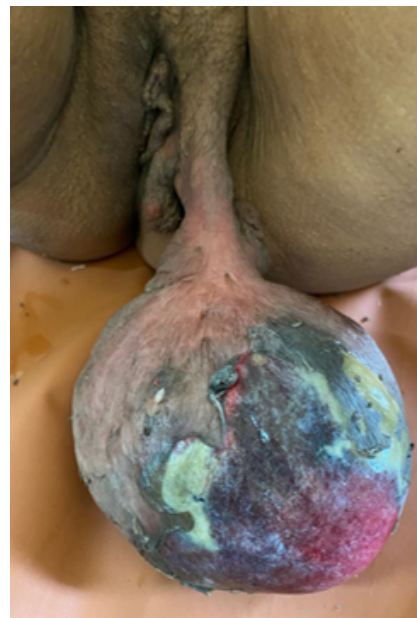Histopathological report – Squamous epithelium covered hypocellular tumor showing spindle cells set in a loose collagenized to myxoid stroma.



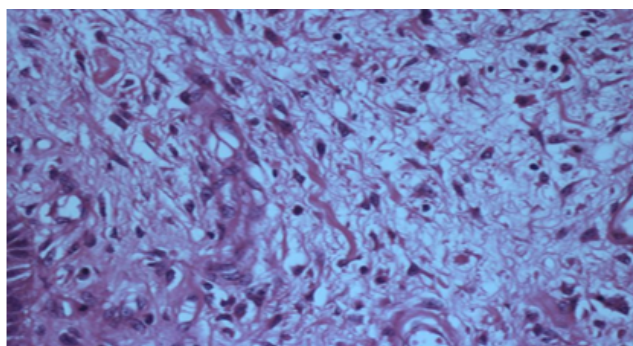
**Fig. 4:** Histopathological picture of Fibroepithelial polyp

#### 5.5. Angiofibroma

Cellular angiofibroma, benign mesenchymal tumor, was first described in 1971 and which mainly involves the vulval area.<sup>18</sup> Vulval Cellular Angiofibromas are generally painless, they may also remain undetected due to a lack of significant signs and symptoms. However, some are known to grow to large sizes and cause pain and compression of the adjoining genital organs. Cellular Angiofibroma of Vulva is generally seen in women between age group 27-63 years, while most commonly seen in women between age group 40-50 years.<sup>19</sup> The treatment is a surgical removal of the entire tumor. The prognosis of Cellular Angiofibroma of Vulva is very good after surgical excision. This case was a 56 years old, Para 7 Living 5 Dead 2, with vulval mass since 6 years which was localized on left labia majora, measures 21x12 x2 cm mass with stalk with purulent discharge. On local site sonography of mass increased vascularity seen. More than half of mass was necrosed hence emergency surgical excision was done. Histopathological examination reported angiofibroma of the vulva.

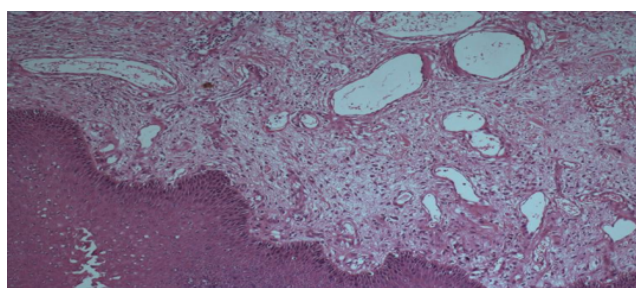


**Fig. 5:** Angiofibroma



**Fig. 6:** Histopathological picture of Angiofibroma

Histopathological report – High power image showing stellate fibroblasts and upper right corner showing mast cell.



**Fig. 7:** Histopathological picture of angiofibroma

Histopathological report – skin covered cellular tumor showing haphazardly arranged spindled to stellate fibroblasts and many varying calibre dilated blood vessels in a collagenous stroma.

### 5.6. Bowen's disease

An early form of skin cancer is Bowen's disease which can be easily cured. It is presented as a red, scaly patch on the skin. In only 10% cases this pre-cancerous condition can progress to skin cancer. It affects the outermost layer of skin, squamous cells layer hence is also known as squamous cell carcinoma in situ.<sup>20</sup> The lesion is usually very slow growing, but untreated cases may progress to very serious form of skin cancer. Bowen's disease most commonly seen in older people between age group 60-70 years. Human papilloma virus (HPV) infection is a high risk factor to developed Bowen's disease. HPV 16, 18, 34, and 48 are associated with Bowen disease at genital sites, in which HPV 16 is most commonly seen. Very rarely, HPV types 2, 16, 34, and 35 are associated with Bowen disease in areas of the body other than the genitals.<sup>20</sup> Surgical excision is treatment of choice. The abnormal skin is scrapped off under anesthesia and skin closure is done. This was the case of a 28 year old, Para 3 Living 3, tubectomised complaining of itching and vulval erosions since 3 years, 2 x 3 cm

white plaque like lesion was there on right labia minora. The skin was scrapped off under anesthesia. Histopathology examination reported Bowen's disease.<sup>21–23</sup>

## 6. Conclusion

This study helps us to get an insight of various benign vulval masses and there prevalence.

Vulval masses	Percentage (%)
Bartholin Cyst	56
Vulval abscess	04
Gartner's cyst	08
Antibioma	02
Vulval lipoma	04
Vulval nodule	02
Inclusion cyst	16
Bowen disease (Vulval erosions)	02
Neurofibroma of vulva	02
Angiofibroma of vulva	02
Fibroepithelial polyp of labia	02

Further long-term studies are required to fully assess the recurrent rates and risk of malignancy of benign vulval masses.

## 7. Conflict of Interest

The authors declare they have no conflict of interest.

## 8. Source of Funding

No financial support was received for the work.

## References

- Ridley CM, Frankman O, Jones IS, Pincus SH, Wilkinson EJ, Fox H, et al. New nomenclature for vulvar disease: International Society for the study of vulvar disease. *Hum Pathol.* 1989;20(5):495–6. doi:10.1016/0046-8177(89)90019-1.
- Giannella L, Costantini M, Mfuta K, Cavazza A, Cerami L, Gardini G, et al. Pendunculated angiofibromablastoma of the vulva: case report and review of literature: case report. *Case Rep Med.* 2011;p. 893261.
- Bhide A, Nama V, Patal S, Kalu E. Microbiology of Cysts/Abscesses of Bartholins Glands: Review of Empirical Antibiotic Therapy against Microbial Culture. *J Obstet Gynaecol.* 2010;30(7):701–3. doi:10.3109/01443615.2010.505672.
- John CO, Enyinda CE, Okonya O. Bartholin's Cyst and Abscesses in a Tertiary Health Facility in Port Harcourt, South-South Nigeria. *J Med Biol Sci Res.* 2015;1(8):107–11.
- Anozie OB. Incidence, Presentation and Management of Bartholin's Gland Cysts/ Abscesses: A Four-Year Review in Federal Teaching Hospital. *Open J Obstet Gynecol.* 2016;6(5):299–305.
- Hill DA, Lense JJ. Office management of Bartholin gland cysts and abscesses. *Am Fam Physician.* 1998;57(7):1619–20.
- Niu S, Dide RD, Schuchmann JK. Gartner's duct cysts: a review of surgical management and a new technique using fluorescein dye. *Int Urogynecol J.* 2020;31(1):55–61. doi:10.1007/s00192-019-04091-9.
- <https://www.dovemed.com/diseases-conditions/gartner-duct-cysts-va-gina/>Last updated Sept. 16, 2018, Approved by: Krish Tangella MD, MBA, FCAP.

9. Escudero RM, Martinez MCN, Castillo OA. Vaginal Gartner cysts: clinical report of four cases and a bibliographic review. *Arch Esp Urol*. 2014;67(2):181–4.
10. Gersell DJ, Fulling KH. Localized neurofibromatosis of the female genitourinary tract. *Am J Surg Pathol*. 1989;13(10):873–8. doi:10.1097/0000478-198910000-00007.
11. Ralston S, Penman I, Strachan M, Hobson R. Davidson's Principles and Practice of Medicine. In: 23rd Edn. Elsevier; 2018. p. 1131.
12. Haley JC, Mirowski GW, Hood AF. Benign vulval tumours. *Semin Cutan Med*. 1998;17(3):196–204. doi:10.1016/s1085-5629(98)80014-x.
13. Gordon MD, Weilert M, Ireland K. Plexiform neurofibromatosis involving the uterine cervix, endometrium, myometrium and ovary. *Obstet Gynecol*. 1996;88(4 pt 2):699–701. doi:10.1016/0029-7844(96)00242-6.
14. Sonnendecker EW, Cohen RJ, Dreyer L, Sher RC, Findlay GH. Neuroma of the vulva. A case report. *J Reprod*. 1993;38(1):33–6.
15. Syed SYB, Lipoff JB, Chatterjee K. StatPearls [Internet]. Treasure Island (FL): StatPearls Publishing; 2020 Jan. 2020 Aug 10.
16. Rexhepi M, Trajkovska E, Besimi F, Rufati N. Giant Fibroepithelial Polyp of Vulva: A Case Report and Review of Literature. *PRILOZI*. 2018;39(2-3):127–30.
17. Ahmed S, Khan AK, Hasan M. A huge acrochordon in labia majora—an unusual presentation. *Bangladesh Med Res Counc Bull*. 2011;37(3):110–1. doi:10.3329/bmrcb.v37i3.9123.
18. Nucci MR, Granter SR, Fletcher CD. Cellular angiofibroma: a benign neoplasm distinct from angiomyofibroblastoma and spindle cell lipoma. *Am J Surg Pathol*. 1997;21(6):636–44.
19. McCluggage WG, Perenyi M, Irwin ST. Recurrent cellular angiofibroma of the vulva. *J Clin Pathol*. 2002;55(6):477–9. doi:10.1136/jcp.55.6.477-b.
20. Available from: <https://rarediseases.org/rare-diseases/bowen-disease/>.
21. Bowens disease - NHS site. Available from: <https://www.nhs.uk/conditions/bowens-disease/>.
22. Schwartz AR. enBign Vulvar lesions: Medscape; 2020. Available from: <https://emedicine.medscape.com/article/264648-overview>.
23. Nath B, Gaikwad HS, Rajamani N, Chouhan M, Sharma M, Topden S. Vulvar Smooth Muscle Tumours: Case Series and Review of Literature. *J Clin Diagn Res*. 2019;13(6):QR01–QR04.

## Author biography

**Pawar Kalyani S**, Junior Resident

**Shilpa Chaudhari**, Professor and HOD

**Shastri Shraddha**, Associate Professor

**Hol Kishorkumar**, Associate Professor

**Cite this article:** Pawar Kalyani S, Chaudhari S, Shraddha S, Kishorkumar H. Evaluation of vulval masses. *Panacea J Med Sci* 2021;11(3):458-463.