



## Case Report

# Overdentures the realms of overshadowness or obliviousness

Srabanti Nandy<sup>1,\*</sup>, Sanjit Lal Das<sup>1</sup>, Uttam Kumar Sen<sup>1</sup>, Arindam Karmakar<sup>1</sup>

<sup>1</sup>Dept. of Prosthodontics and Crown & Bridge, Haldia Institute of Dental Sciences and Research, Haldia, West Bengal, India



### ARTICLE INFO

#### Article history:

Received 05-07-2021

Accepted 20-10-2021

Available online 20-12-2021

#### Keywords:

Root preservation

Tooth supported overdenture

Ball attachment

Parallelometer

### ABSTRACT

**Statement of Problem:** The overdenture is a predictable and valuable option in the treatment of a patient with multiple missing teeth. It aids by preservation of alveolar bone, teeth and supporting structures, maintenance of proprioceptive response and neuromuscular co-ordination, and enhances the quality of a prosthesis by improving the stability, retention and patient acceptance.

**Purpose:** Often while fabricating an overdenture with retained attachments it becomes mandatory to cast the wax pattern and by no means can that be judged for parallelism with the abutments. A lucid method of obtaining parallelism has been described, adjunct with significant improvement of bite force has been portrayed.

**Summary & Conclusion:** Careful case selection and abutment preparation as well as periodic recall is the key to a successful over denture rehabilitation. This case report also depicts the tooth supported overdenture as a viable option with the use of a customized parallelometer which has its ease of use and cost effectiveness for determining parallelism of abutments using a prefabricated ball attachment system and decipheres the increase in bite force in a dynamic manner.

This is an Open Access (OA) journal, and articles are distributed under the terms of the [Creative Commons Attribution-NonCommercial-ShareAlike 4.0 License](https://creativecommons.org/licenses/by-nc-sa/4.0/), which allows others to remix, tweak, and build upon the work non-commercially, as long as appropriate credit is given and the new creations are licensed under the identical terms.

For reprints contact: [reprint@ipinnovative.com](mailto:reprint@ipinnovative.com)

## 1. Introduction

The overdenture, a complete or partial denture prosthesis constructed over existing teeth or root structure is not a new concept in a technical approach to a prosthodontic problem. Today, with the stress on preventive measures in prosthodontics, the use of overdentures has increased to the point where it is now a feasible alternative to most treatment plan outlines in the construction of a prosthesis for patients with some remaining teeth. Because of increased awareness towards dental health and improved oral hygiene practices, an increase in number of the elderly with few teeth remaining, in comparison to the completely edentulous patients, has been observed.<sup>1</sup> Bone loss in the edentulous arches following extraction facilitates faster resorption rate, coupled with declination of neuromuscular function

and marked decrease in the proprioceptive response often leads to compromised situations and mandates replacement with implant supported prosthesis, requiring extensive surgeries and augmentation procedures, overall reckoning to increased morbidity. Despite recent developments and extravagant use of dental implants, the conservative approach to root preservation is still treasured. This case report is a humble effort to represent the requirement and result of preservation and its meticulous application in clinical scenario for optimal functional harmonization.

## 2. Case Report

A male patient aged 57 years reported to the out-patient department of Prosthodontics and Crown & Bridge, with the chief complaint of inability to chew for the last few months. After thorough corroboration of history it was found out that the patient had undergone extractions of multiple teeth

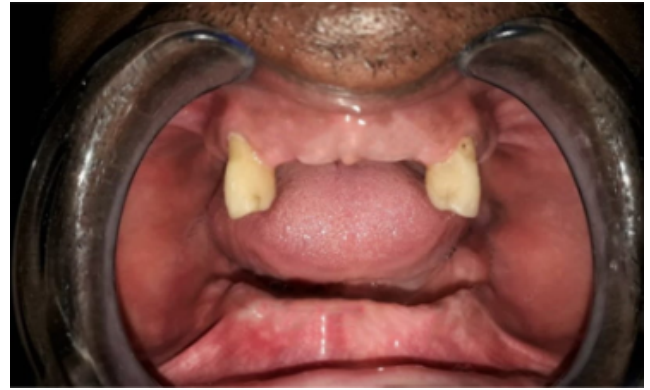\* Corresponding author.

E-mail address: [srabantirockz@gmail.com](mailto:srabantirockz@gmail.com) (S. Nandy).


in either arches due to carious lesions and periodontal degradations with time. On intra oral examination it was found that the patient presented with a completely edentulous lower arch and canine abutments present in the upper arch (Figure 1). Upon discussion and presentation of different treatment modalities and importance of preservation being explained, a tooth supported overdenture (attachment retained) for the maxillary arch and an opposing conventional complete denture was planned out following proper consent. Diagnostic impressions were made with irreversible hydrocolloids and subsequently a diagnostic mounting was performed to determine the available inter arch space (Figure 2) as overdenture fabrication mandates the requirement of sufficient available inter arch space. Endodontic therapy was advocated for the remaining abutments (Figure 3), post space preparation was completed and the prefabricated ball attachment post (EDS Access Post, Figure 4) was checked for snug fit, appropriate depth and angulation. (Figure 5). For proper verification of angulation and parallelism of attachments a customized parallelometer was advocated. The crown of the abutment teeth was prepared up to 3 mm above the height of the gingival margin. They were rounded in all directions to make the coronal portion dome-shaped. The shaping allowed placement of the denture directly in the same position as the original coronal portion of the tooth. The parallelometer consisted of a handle, two miniplates that slide past each other horizontally, and two analyser rods which remained parallel to each other in any given relationship of miniplates.<sup>2</sup> (Figure 6). After final verification, clinically and radiographically, (Figure 7) the post space was luted with cotton plugs and temporary cement. Conventional method of fabrication of complete dentures were carried out and the dentures were processed accordingly. At the final appointment the prefabricated ball attachment posts were luted and the pick-up procedure of the female housings were done on the intaglio surface of the finished dentures with self-cure acrylic resin. (Figure 8) The patient was given all necessary post insertion instructions. The patient reported back after 2 weeks for post insertion check-up (Figure 9) with no associated complaints, slight occlusal adjustments were provided and was followed up at an interval of 6 months there.

### 3. Discussion

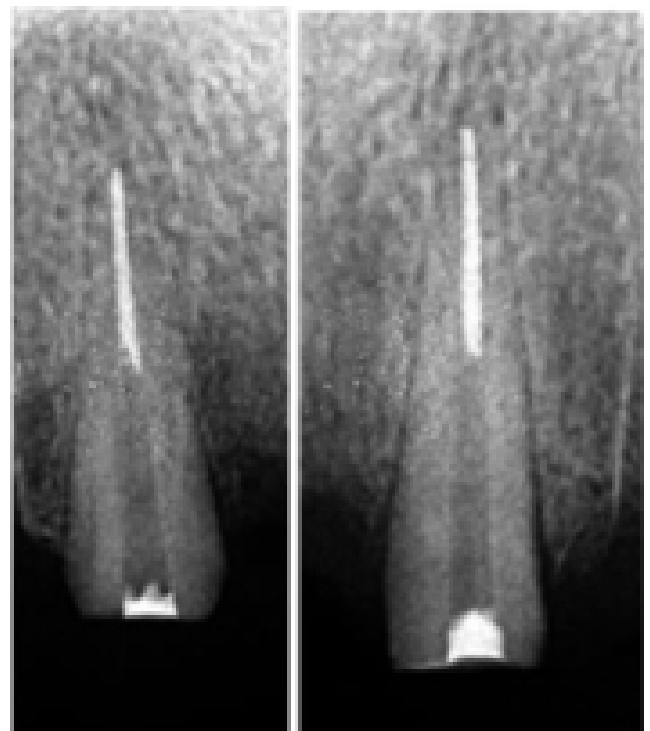The prospect of losing all teeth can be very annoying for a patient. It hampers physiologic and psychologic aspects as it is an indirect reminder for being dependent on others and losing senescence. In such conditions, overdenture option as preventive prosthodontic treatment modality should be regularly imbibed because of its innumerable advantages. Crum and Rooney<sup>3</sup> graphically demonstrated in 5 years study, an average loss of 0.6 mm of vertical bone in the anterior part of the mandible of



**Fig. 1:** Pre-Op intra oral



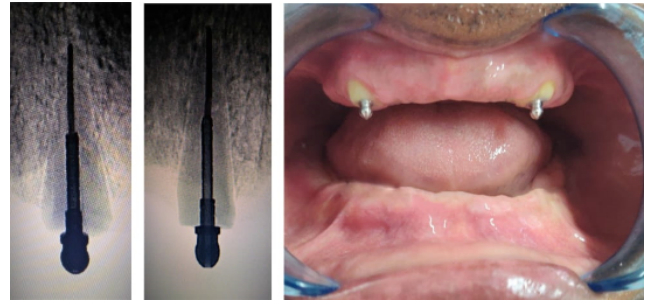
**Fig. 2:** Tentative jaw relation to determine inter arch space



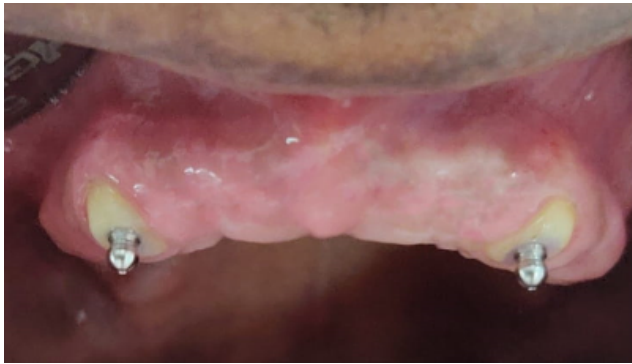**Fig. 3:** Post space preparation with 4-5 mm of apical seal



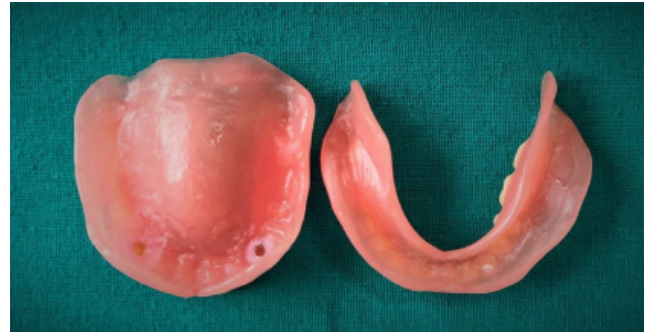**Fig. 4:** EDS ACCESS post system



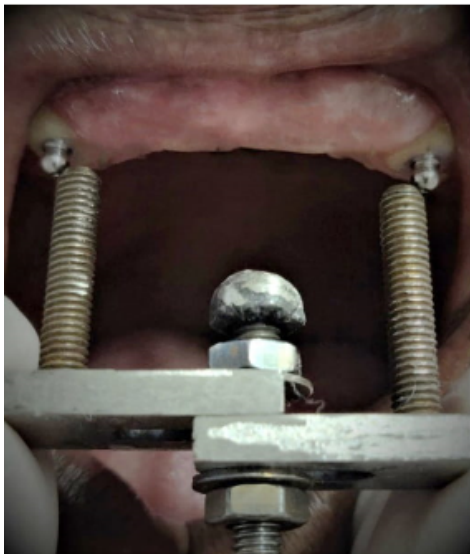**Fig. 7:** Luting and clinical and radiographic verification



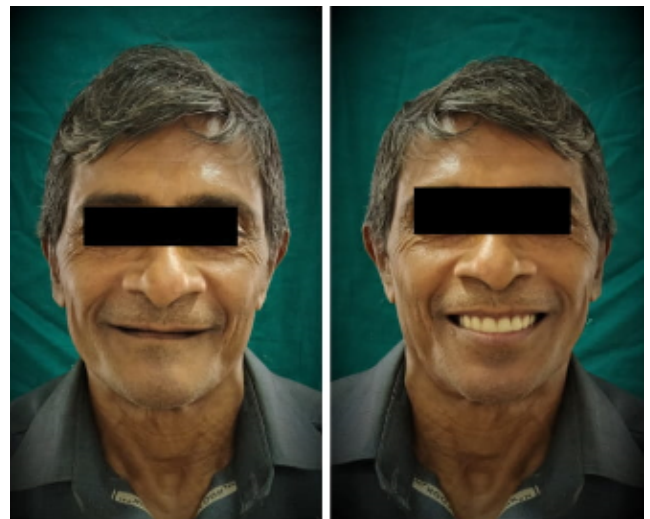**Fig. 5:** Verification of attachment post for snug fit and appropriate depth



**Fig. 8:** Picking up of the female housing with self-cure acrylic resin



**Fig. 6:** Utilization of customized parallel meter



**Fig. 9:** Post-Op frontal view

overdenture patients through cephalometric radiographs as opposed to 5.2 mm loss in complete denture patients. Thus, the importance of preservation places huge significance in clinical outcomes. Various types of attachments have been used during overdenture fabrication; however, no attachment systems possess one hand one glove concept, they vary in myriad manners such as plane of rotation, ease of use and cost. Irrespective of the attachment used, it is

important to maintain parallelism between the attachments for ease of insertion and removal, functional efficiency, and durability of the prosthesis.<sup>4</sup> It is challenging to obtain parallelism between attachments when the abutments are divergent, or multiple abutments are engaged. Usage of castable attachments mandates, a pick-up impression of the arch with post patterns, later, on the working cast obtained, castable attachments are connected to the post pattern. Surveying is performed to obtain the parallelism, and casting is carried out.<sup>5</sup> This case reports makes use of a customized parallelometer which eliminates various complicated armamentarium and is cost effective. Patil R. et al. conducted a study and stated that group of individuals rehabilitated with overdenture showed greater values of bite forces than lower baseline value of conventional complete dentures.<sup>6</sup> With a Retentive Force Analyser, an overdenture seems to be (3.9655 = 4) times more retentive than a conventional complete denture as portrayed within this case report by the use of digital force gauge, (Fig 1.10), which depicts the outcome of such treatment procedure. Tooth supported overdenture is a viable treatment option and can be deployed if all other parameters are within clinical norms as a way of preservation as well as achieving highest clinical success.

#### 4. Conclusion

Even though the technique resembles that of complete denture there are important differences. The prognosis of the restoration is likely to be influenced by numerous factors viz, selection of patient, treatment planning, preparation of mouth, prosthodontic work and maintenance. Finally, it is reasonable to believe that the retention of a part of the natural dentition affords the overdenture patient a gain in neuromuscular performance thereby giving him/her an edge over their edentulous counterparts.

#### 5. Conflicts of Interest

The authors declare that there are no conflicts of interest regarding the publication of this paper.

#### 6. Source of Funding

None.

#### References

1. Allen PF, Mckenna G, Creugers N. Prosthodontic care for elderly patients. *Dent Update*. 2011;38(7):469–70. doi:10.12968/denu.2011.38.7.460.
2. Pawar RS, Raipure PE, Kulkarni RS, Tagore M, Ganesan R. Fabrication of custom overdenture attachments using indigenously made parallelometer: A technique. *J Indian Prosthodont Soc*. 2019;19(1):83–7. doi:10.4103/jips.jips\_282\_18.
3. Crum RJ, Rooney GE. Alveolar bone loss in overdentures: A 5-year study. *J Prosthet Dent*. 1978;40(6):610–3. doi:10.1016/0022-3913(78)90054-9.
4. Schuch C, Moraes APD, Sarkis-Onofre R, Pereira-Cenci T, Boscato N. An alternative method for the fabrication of a root-supported overdenture: A clinical report. *J Prosthet Dent*. 2013;109(1):1–4. doi:10.1016/S0022-3913(13)00013-9.
5. Bansal S, Aras MA, Chitre V. Tooth supported overdenture retained with custom attachments: A case report. *J Indian Prosthodont Soc*. 2014;14(1):283–6. doi:10.1007/s13191-013-0340-0.
6. Patil R, Sajjanar J, Bembalagi M, Shetty P. Bite Force in Tooth Supported Prosthodontics. *J Dent Med Sci*. 2015;14(1):66–8.

#### Author biography

**Srabanti Nandy**, Post Graduate Trainee

**Sanjit Lal Das**, Professor and HOD

**Uttam Kumar Sen**, Professor, Principal

**Arindam Karmakar**, Professor

**Cite this article:** Nandy S, Das SL, Sen UK, Karmakar A. Overdentures the realms of overshadowness or obliviousness. *J Dent Spec* 2021;9(2):80-83.