



Case Report

Osteosarcoma presenting as ludwig's angina in a down's syndrome patient: A case report

Manjunath Vijapur¹, Vasanth Kattimani², Dhaya Ann Varghese³, Bhargav Ram^{3,*}, Rishikesh Kumar³, Anuradha Naganagoudar¹

¹Dept. of Oral and Maxillofacial Surgery, Karnataka Institute of Medical Sciences, Hubli, Karnataka, India

²Dept. of Oral and Maxillofacial Surgery, District Hospital, Dharwad, Karnataka, India

³Dept. of Oral and Maxillofacial Surgery, K.V.G. Medical College & Hospital, Sullia, Karnataka, India



ARTICLE INFO

Article history:

Received 26-11-2021

Accepted 30-11-2021

Available online 20-12-2021

Keywords:

Case report

Down's Syndrome

Osteosarcoma

Ludwig's Angina

ABSTRACT

Individuals with Down's Syndrome are predisposed to leukaemia, possibly other malignancies, various infection as well as increased mortality from other causes. osteosarcoma has been linked to genetic illnesses such as hereditary retinoblastoma, Li-Fraumeni syndrome, and Rothman-Thomson syndrome, it has not been linked to Down syndrome. Treatment plan for osteosarcoma includes surgical resection with systemic chemotherapy. Osteosarcoma is highly resistant to radiotherapy. Here we present a 21 year old female patient which is a unique case of Osteosarcoma in Down's Syndrome patient presenting as Ludwig's Angina. This current report highlights a clinical presentation of Osteosarcoma in Down's Syndrome.

This is an Open Access (OA) journal, and articles are distributed under the terms of the [Creative Commons Attribution-NonCommercial-ShareAlike 4.0 License](https://creativecommons.org/licenses/by-nc-sa/4.0/), which allows others to remix, tweak, and build upon the work non-commercially, as long as appropriate credit is given and the new creations are licensed under the identical terms.

For reprints contact: reprint@ipinnovative.com

1. Introduction

In the year 1866 John Langdon Down was the first to define Down's syndrome, identifying the phenotypic manifestation of those with circulatory and coordination problems as having Down's syndrome. A century later, Jerome Lejeune postulated that nondysjunction during meiosis may result in trisomy of the 21st chromosome. Down's syndrome is now understood to be caused by a chromosomal defect. The word "trisomy21" refers to a condition in which three chromosomes 21 are present rather than two. In a rare situation, the typical 46 chromosomes are present, but chromosome 21 has been translocated to another location. Although a genetic translocation of one of the pair of chromosomes 21 may occur if the mother is young, the condition is more common in children born to older mothers, especially those over the age of thirty-five.¹

Down's syndrome children are intellectually impaired to some extent, and they are often shorter than average in height for their age. They have Midface dysplasia, a flat broad bridge of the nose, "lop" ears, epicanthal folds, and slanting almond-shaped eyes, which gave rise to the term mongoloid. The majority of the youngsters have brachycephaly (a broad, short head) as well as an absence of supraorbital ridges and hypotelierism. Absence of frontal sinuses, absent or reduced maxillary sinuses, nasal septum or nasal conchl deviations are frequently observed, resulting in a partially obstructed or narrow air passage and contributing to the problem of mouth breathing, which is prone to infections, particularly upper respiratory tract infections.²

Individuals with Down's Syndrome are predisposed to leukaemia and possibly other malignancies, as well as increased mortality from other causes, however data on the magnitude of risk associated with specific diseases or causes of death is limited.³

* Corresponding author.

E-mail address: bhargav01@live.com (B. Ram).

Osteosarcoma is the most common primary bone tumour in children and adolescents, with a peak frequency between the ages of 12 and 16. The total five-year survival rate for localised disease was 70%. Multidrug chemotherapy regimens with high-dose methotrexate, doxorubicin, and cisplatin have been standard medical treatment since the 1970s. Although osteosarcoma has been linked to genetic illnesses such as hereditary retinoblastoma, Li-Fraumeni syndrome, and Rothman-Thomson syndrome, it has not been linked to Down syndrome. Only a few such cases have been documented and one patient died from sepsis 18 days after receiving high-dose methotrexate therapy.⁴

Here we present a 21-year old female patient which is a unique case of Osteosarcoma in Down's Syndrome patient presenting as Ludwig's Angina. This current report highlights a clinical presentation of Osteosarcoma in Down's Syndrome.

1.1. Narrative

Father of a 21-year-old patient came to us with a complaint of swelling in his daughter's chin region since one and half months which was gradual on onset. Pain which was radiating towards her head that was intermittent in nature which led to the present size. H/O local ayurvedic balm application 1 month back. No H/O breathing difficulty. patient was taken to a local dentist where unknown medications were given and there were no relief in symptoms. Patient has been physically and mentally challenged since the time of birth and was not under any medication. Patient's parents does not give any history of previous admission or treatments. On inspection, epicanthic folds & up slanted eyes were noted. Low set ears depressed nasal bridge, flattened face, short neck with enlarged tongue there was gross facial asymmetry noted on the lower third of face. Based on patient's physical growth status and psychological presentation, patient was clinically diagnosed with Downs Syndrome.

A solitary diffused swelling was noted bilaterally from the middle third of face extending antero-posteriorly from bilateral corner of mouth extending till the posterior border of ramus of mandible and superior-inferiorly from bilaterally ala-tragus extending inferiorly till the laryngeal prominence region measuring approx. 6*6 cm in diameter. Skin over the swelling appears to be stretched with signs of active pus discharge & sinus opening. Bilateral level 1B palpable and tender. Swelling was tender on palpation, non-fluctuant, non-pulsatile swelling present, soft to firm in consistency, skin over the swelling surface is smooth with no irregularities without local rise in temperature. Intraorally, multiple carious teeth noted and mouth opening limited to 25 mm. Occlusion maintained bilaterally without deviation of mandible.

Patient was provisionally diagnosed with Ludwig's Angina for which intravenous antibiotics were administered

Table 1: Blood Parameters were as follows

Blood Group	B Negative
Hemoglobin	9.4%
PCV	29.8%
TLC	8200cells/mm
DLC	N – 49%, M – 04%, L – 45%, E – 2%, B – 0%
ESR	80 mm/hour
RBS	9.1 mg/dl
Platelets	3.13 lakhs/ cu mm
Blood Urea	15 mg/dl
S. creatinine	0.93 mg/dl
Sodium	139 mmol/L
Potassium	4.03 mmol/L
Chloride	108 mmol/L
APTT	T 31.2 Control - 34
PT	T – 14.9 Control – 12.4
INR	1.17
HBsAg, HIV, HCV, COVID- 19	Negative

and incision - drainage was done. As patient's condition did not improve in the following days, further investigations were advised.

Computed tomography revealed involvement of right mandibular body suggestive of osteomyelitic changes. An informed and written consent was obtained from the patient bystander for the procedure. FNAC report was suggestive of dysplastic changes followed by biopsy which revealed osteosarcoma. The patient was planned for mandibular resection with modified radical neck dissection and reconstruction. The patient was discharged against medical advice and she has passed away after two weeks.

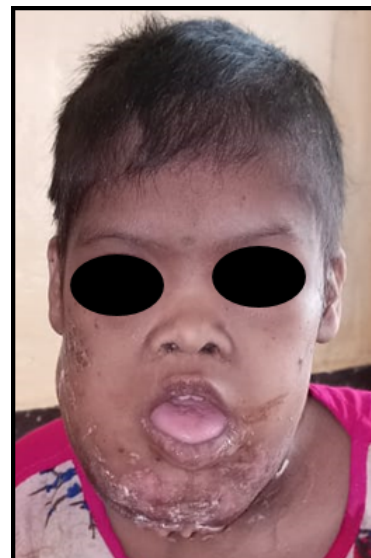

Fig. 1: Frontal view

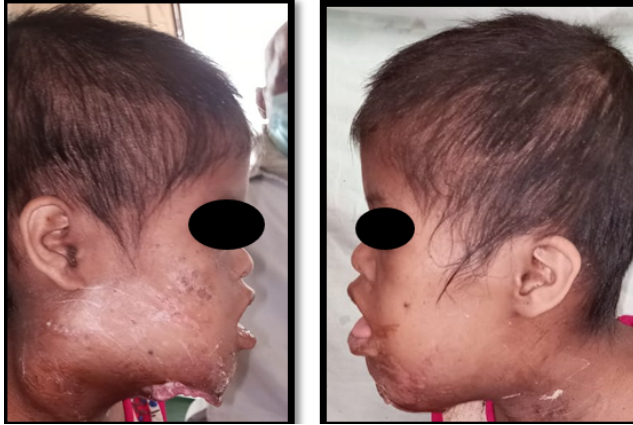

Fig. 2: a,b – Lateral view

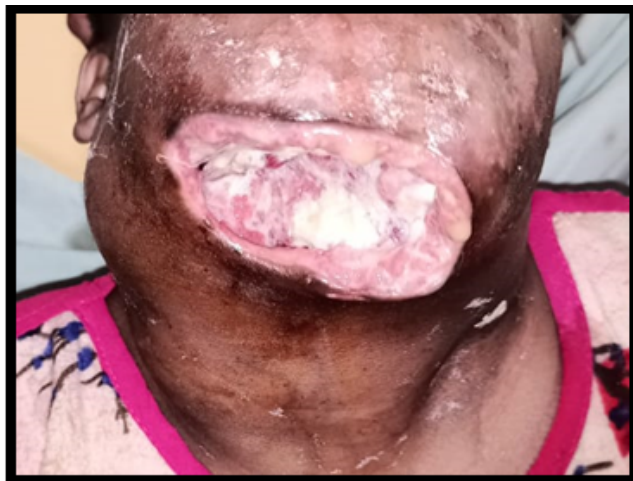

Fig. 3: Showing the lesion

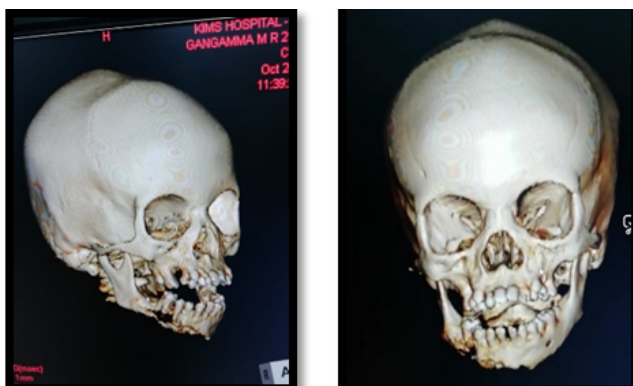


Fig. 4: Showing 3D reconstructed ct images

2. Discussion

Down's syndrome (trisomy 21) is known to be associated with acute leukaemia, although there is no evidence of an increased incidence of other cancers. Down syndrome affects one out of every 800 to 1,000 live births and is related with trisomy of chromosome 21, except in rare situations of chromosome 21 translocation (4-5 percent of all cases) or chromosome 21 deletion or Mosaicism (2-4%). persons with down syndrome have an increased chance of developing acute leukaemia and excess mortality owing to infectious agents, congenital abnormalities, and other disorders.²

Down's syndrome patients are generally not susceptible to dental caries and are more prone to periodontal infections, but in this report patient presented with multiple carious teeth. As there was bilateral submandibular, submental and sublingual swelling it was provisionally diagnosed as Ludwig's Angina. This is a very unique case of Osteosarcoma in Down's Syndrome patient presenting as Ludwig's Angina.⁵

Because almost all patients with osteosarcoma have at least microscopic metastatic disease, systemic chemotherapy is required for successful treatment. Systemic chemotherapy is required for the successful treatment of osteosarcoma. The chemotherapeutic drugs used in most treatment regimens are chosen from those that have been shown to be effective against osteosarcoma. Doxorubicin, cisplatin, ifosfamide, high-dose methotrexate with leucovorin rescue (HDMTX), and cyclophosphamide are among them. These agents are harmful in both the short and long term. Surgery is the sole effective method for local control of osteosarcoma because it is particularly resistant to radiation therapy. The surgical management of Mandibular Osteosarcoma involves resection of the mandible with Radical Neck Dissection and Reconstruction with local pedicle or distant free flaps.^{6,7}

Although methotrexate-based chemotherapy regimens for paediatric osteosarcoma have been widely investigated, no standardised treatment procedures for individuals who are unable to tolerate high-dose methotrexate (12 g/m² dosage) have been developed. It is well established that patients with Down syndrome who develop acute lymphoblastic leukaemia are more susceptible to methotrexate toxicity.⁸ Methotrexate's delayed renal clearance may predispose these patients to more severe side effects. Most notably, methotrexate appears to cause greater myelosuppression in Down syndrome patients, leading to an increased frequency of infections and fatalities from sepsis.⁹

Sims et al. treated a 14-year-old Down syndrome kid with 1 dose of carboplatin, 480 mg/m² cisplatin, 450 mg/m² doxorubicin, and 56 g/m² ifosfamide in a case report. Due to chronic renal insufficiency, the initial regimen was changed to include cisplatin instead of carboplatin and lower

ifosfamide dosages. Their patient is living three years after finishing this chemotherapy treatment and having tumour excision with no new tumours or metastases discovered on imaging. He handled treatment effectively, with no signs of sepsis.^{10,11}

3. Conclusion

Osteosarcoma is aggressive bone pathology with very high morbidity and mortality. Misdiagnosis and delay in treatment especially in such cases of aggressive osteosarcoma can result in complications and deterioration in systemic condition. A multidisciplinary approach to treatment that includes surgeons, genetic medicine specialist, pathologist and radiologist can aid in appropriate treatment plan. This current case report hereby hopes to prevent such untimely death in the future in case of patients presenting with similar symptoms.

4. Conflicts of Interest

The authors declare that there are no conflicts of interest regarding the publication of this paper.

5. Source of Funding

None.

References

1. Smith GF, Berg JM. Down's anomaly. 2nd Edn. Scotland: p. 100–49.
2. Mattei JF, Mattei MG, Ayme S, Giraud F. Origin of the extra chromosome in trisomy 21. *Hum Genet.* 1979;46(1):107–10.
3. Wilimas J, Barrett G, Pratt C. Osteosarcoma in 2 very young children. *Clin Pediatr.* 1977;16(6):548–51. doi:10.1177/000992287701600612.
4. Hill DA, Gridley G, Cnattingius S, Mellemkjaer L, Linet M, Adami HO, et al. Mortality and cancer incidence among individuals with Down syndrome. *Arch Intern Med.* 2003;163(6):705–11. doi:10.1001/archinte.163.6.705.
5. Ottaviani G, Jaffe N. The etiology of osteosarcoma. *Cancer Treat Res.* 2009;152:15–32. doi:10.1007/978-1-4419-0284-9_2.
6. Abramson DH, Ellsworth RM, Kitchin FD, Tung G. Second nonocular tumors in retinoblastoma survivors: are they radiation-induced? *Ophthalmology.* 1984;91(11):1351–5. doi:10.1016/s0161-6420(84)34127-6.
7. Bacci G, Ruggieri P, Picci P, Briccoli A, Ferraro A, Ferrari S, et al. Changing pattern of relapse in osteosarcoma of the extremities treated with adjuvant and neoadjuvant chemotherapy. *J Chemother.* 1995;7(3):230–9.
8. Shah N, Al-Ahmari A, Al-Yamani A. Outcome and toxicity of chemotherapy for acute lymphoblastic leukemia in children with Down syndrome. *Pediatr Blood Cancer.* 2009;52(1):14–9. doi:10.1002/pbc.21737.
9. Gorlick R, Janeway K, Lessnick S. Children's Oncology Group's 2013 blueprint for research: bone tumors. *Pediatr Blood Cancer.* 2013;60(6):1009–15. doi:10.1002/pbc.24429.
10. Sims E, Nath A, Sugalski A. Successful Treatment of Osteosarcoma Without Methotrexate in a 13-Year-Old Boy With Down Syndrome. *J Pediatr Hematol Oncol.* 2019;41(1):71–3. doi:10.1097/MPH.0000000000001212.
11. Bacci G, Ferrari S, Mercuri M, Longhi A, Capanna R, Tienghi A, et al. Neoadjuvant chemotherapy for extremity osteosarcoma-preliminary results of the Rizzoli's 4th study. *Acta Oncol.* 1998;37(1):41–8. doi:10.1080/028418698423168.

Author biography

Manjunath Vijapur, Associate Professor

Vasanth Kattimani, Specialist

Dhaya Ann Varghese, Post Graduate

Bhargav Ram, Post Graduate

Rishikesh Kumar, Post Graduate

Anuradha Naganagoudar, Senior Resident

Cite this article: Vijapur M, Kattimani V, Varghese DA, Ram B, Kumar R, Naganagoudar A. Osteosarcoma presenting as ludwig's angina in a down's syndrome patient: A case report. *J Dent Spec* 2021;9(2):72-75.