



## Case Report

# Phonetic contouring of polished surface of denture base for speech enhancement

Komal Kaur Saroya<sup>1,\*</sup>, Kavipal Singh<sup>1</sup>, Nimish Sethi<sup>1</sup>, Neelam Suman<sup>1</sup>

<sup>1</sup>Dept. of Prosthodontics and Crown and Bridge, Sri Guru Ram Das Institute of Dental Sciences and Research, Amritsar, Punjab, India



### ARTICLE INFO

#### Article history:

Received 19-08-2021

Accepted 24-09-2021

Available online 09-10-2021

#### Keywords:

Rugae

Phonetics

Palatal contouring

Speech

Palatal anatomy replication

Rugae duplication

### ABSTRACT

The three main factors in complete denture construction are mechanics, esthetics, and phonetics. Out of which phonetics is generally given least importance as the tongue tends to adapt and patients tend to return to normal speech after a post insertion practice period of several weeks to several months. This may not be acceptable to certain group of people in accordance with their needs to speak socially or vocationally. An accurate approximation of palatal contours of a maxillary complete denture to patient's tongue can improve intelligibility and decrease the post- insertion practice period. This article outlines a technique to replicate the patient's palatal anatomy onto the polished palatal surface of a complete denture.

This is an Open Access (OA) journal, and articles are distributed under the terms of the [Creative Commons Attribution-NonCommercial-ShareAlike 4.0 License](https://creativecommons.org/licenses/by-nc-sa/4.0/), which allows others to remix, tweak, and build upon the work non-commercially, as long as appropriate credit is given and the new creations are licensed under the identical terms.

For reprints contact: [reprint@ipinnovative.com](mailto:reprint@ipinnovative.com)

## 1. Introduction

The three cardinal factors in complete denture construction are mechanics, esthetics, and phonetics. Considerable progress has been made in improving mechanics and esthetics, but little has been done to improve phonetics.<sup>1</sup>

Quite frequently, denture patients (both new and replacement) complain of speech problems as they cause embarrassment and add to their burden of physiologic adaptation to the denture. Neglect of this major factor in denture construction may be attributed to the fact that most edentulous patients tend to return to normal speech after a post insertion practice period of several weeks to several months.<sup>2</sup> While it is true that the tongue is very adaptable, it must be recognized that this quality is far more significant in patients of a younger age than those that are within an older age range.<sup>3</sup> This may also not be acceptable to certain group of people in accordance with their needs to speak socially or vocationally.

The most common, as well as the most difficult inaccuracy to overcome, is the mispronunciation of the S and SH sounds<sup>1</sup> which are palatolingual sounds formed by the articulation of the tongue with the anterior and lateral portion of the palate. Pronunciation of other palatolingual sounds (T, D, N and L) may also be hampered.<sup>4</sup> Tactile sense is often required to orient the tongue for proper articulation and palatal rugae serve as a cue to it. Hence, reproduction of the palatal vault as close as possible to the patient's natural palatal contour will not only enhance speech intelligibility but also aid in mastication, deglutition and better taste perception with the newly constructed denture.<sup>5</sup>

The purpose of this article, therefore, is to outline a technique to replicate the patient's palatal anatomy onto the polished palatal surface of a complete denture.

### 1.1. Procedure

1. Primary impression of the edentulous ridges was made with impression compound and the primary cast was poured.

\* Corresponding author.

E-mail address: [komalsaroya@gmail.com](mailto:komalsaroya@gmail.com) (K. K. Saroya).

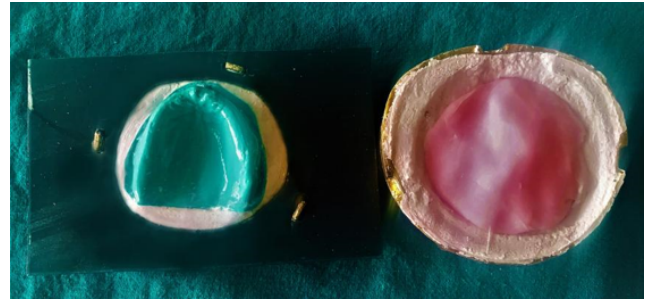
2. Final impression was made using zinc oxide eugenol in custom acrylic trays border moulded with green stick impression compound and the master cast was poured in type III impression plaster.
3. For the fabrication of a permanent denture base duplicating the rugae of the patient, a two mm thick metal plate was fabricated that would fit in between the drag and the cope of the flask when it was closed. The central portion of the metal plate was hollowed out such that it seated only on the edges of the flask. (Figure 1)
4. The master cast was flaked first without the metal plate. The dental stone was allowed to set completely before opening the flask. Thereafter, heat cure acrylic resin was packed and the flask was closed with the metal plate in between. (Figure 2)
5. After acrylization, a denture base was obtained with a two mm even thickness. The rugae area was replicated on the polished palatal surface. (Figure 3)
6. Jaw relations were recorded on the permanent denture bases and articulation was done
7. Teeth setting, trial was done and the denture was processed in a regular manner
8. A complete denture was obtained with the patient's palatal anatomy replicated onto it with an even thickness. (Figure 4)



**Fig. 1:** A two millimeter thick metal plate designed to fit in between the drag and the cope of the flask.

## 2. Discussion

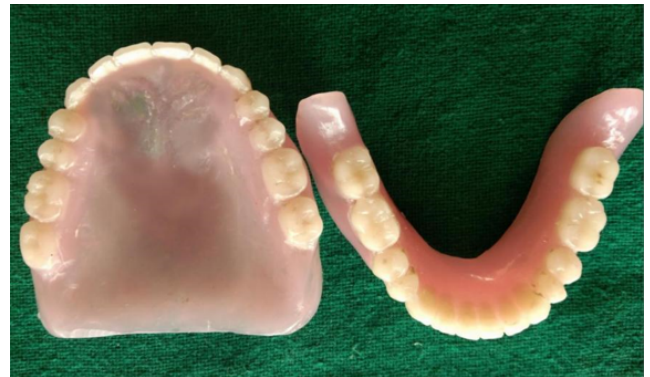In order to produce articulate speech in complete denture patients, an effective tongue-to-palate contact is an important factor.<sup>2</sup> A few attempts have been made to modify the palatal contours of maxillary dentures to produce the desired “normal” speech. These methods include capturing of the palatal rugae by tin foil,<sup>6</sup> interdental floss,<sup>7</sup> palatograms,<sup>1,5,8,9</sup> plastic palate forms, corrugated metal



**Fig. 2:** Metal Plate in place during packing of the denture base with heat cure acrylic resin.



**Fig. 3:** Rugae area replicated on the polished palatal surface.



**Fig. 4:** Finished denture

plate,<sup>10</sup> putty impression and free hand wax carving. All these techniques attempt to replicate the patient's palatal anatomy but the resulting denture base is not precise and even in thickness. The technique described above results in an even, 2mm thick denture which is an exact replica of the patient's palatal vault.

### 3. Conclusion

Accurate approximation of palatal contours of a maxillary complete denture to patient's tongue can improve intelligibility and decrease the post- insertion practice period. A simplified technique for adding customized rugae and palatal contours has been described for achieving normal speech after denture insertion.

### 4. Conflicts of Interest

All contributing authors declare no conflicts of interest.

### 5. Source of Funding

None.

### References

- Allen LR. Improved phonetics in denture construction. *J Prosthetic Dent.* 1958;8(5):753. doi:10.1016/0022-3913(58)90095-7.
- Goyal BK, Greenstein P. Functional contouring of the palatal vault for improving speech with complete dentures. *J Prosthetic Dent.* 1982;48(6):640–6.
- Martone AL, Black JW. An approach to prosthodontics through speech science: Part V. Speech science research of prosthodontic significance. *J Prosthetic Dent.* 1962;12(4):629–36.
- Rothman R. Phonetic considerations in denture prosthesis. *J Prosthetic Dent.* 1961;11(2):214–23.
- Palmer JM. Structural changes for speech improvement in complete upper denture fabrication. *J Prosthetic Dent.* 1979;41(5):507–10.
- Gitto CA, Esposito SJ, Draper JM. A simple method of adding palatal rugae to a complete denture. *J Prosthetic Dent.* 1999;81(2):237–9.
- Vijayaraghavan V, Chandni P. A simple method for palatal rugae carving in complete dentures. *J Indian Prosthodontic Soc.* 2013;13(2):137–8.
- Kong HJ, Hansen CA. Customizing palatal contours of a denture to improve speech intelligibility. *J Prosthetic Dent.* 2008;99(3):243–8.
- Sanjay VB, Priti S, Sadekh A. Reproducing functional palatal contours in complete dentures to improve speech-a case report. *J Indian Dent Assoc.* 2012;6(2):111–4.
- Rogers OW. Electroformed metal palates for complete dentures. *J Prosthetic Dent.* 1970;23(2):207–17.

### Author biography

**Komal Kaur Saroya**, Student

**Kavipal Singh**, Principal, Professor and HOD

**Nimish Sethi**, Professor

**Neelam Suman**, Reader

**Cite this article:** Saroya KK, Singh K, Sethi N, Suman N. Phonetic contouring of polished surface of denture base for speech enhancement. *J Dent Spec* 2021;9(1):19-21.