



Original Research Article

The effect of zinc lozenge on pain, oedema, and trismus after impacted third molar surgery: A prospective randomized, double-blinded, placebo-controlled study

Tejashree Rajanna^{1,*}, Hemalatha B R¹

¹Dept. of Dentistry, Shri Atal Bihari Vajpayee Medical College & Research Institute, Bengaluru, Karnataka, India



ARTICLE INFO

Article history:

Received 17-06-2021

Accepted 03-09-2021

Available online 09-10-2021

Keywords:

Postoperative sequelae

Third molar

Zinc

ABSTRACT

Background: The postoperative sequelae after third molar surgery include pain, swelling and trismus. Zinc acts as anti-inflammatory agent, can promote wound healing, immune system modulation, tissue repair, and significant reduction in the use of analgesics for oral pain. This study was aimed to evaluate the efficacy of oral zinc lozenge given 30 min before surgery on reducing postoperative sequelae.

Materials and Methods: We recruited 70 patients, randomly assigned to two groups: Zinc and Control group, groups received 40mg Zinc lozenge, placebo lozenge 30 min before surgery respectively and every 6h till 72h after surgery. Third molar extraction was performed under local anesthesia. After extraction, pain, swelling, and mouth opening in both groups observed till 72h.

Statistical Analysis: Preoperative and postoperative measurement of visual analog scale scores for pain, edema, interincisal opening, was analyzed using Student t test or ANOVA, Chi-square or Mann-Whitney U test was performed for non-parametric samples. $P < 0.05$ was considered as statistically significant

Results: The overall incidence of Pain in the Zinc group was 18% compared to 43% in the Control group ($P = .003$) Incidence of Pain, swelling, and mouth opening at different time intervals 6h, 24h, 48h and 72h were significantly ($P > 0.05$) better in Zinc group

Conclusion: oral zinc lozenge administered 30 minutes preoperatively can significantly reduce complications like pain, swelling, and limited mouth opening after third molar extraction.

This is an Open Access (OA) journal, and articles are distributed under the terms of the [Creative Commons Attribution-NonCommercial-ShareAlike 4.0 License](https://creativecommons.org/licenses/by-nc-sa/4.0/), which allows others to remix, tweak, and build upon the work non-commercially, as long as appropriate credit is given and the new creations are licensed under the identical terms.

For reprints contact: reprint@ipinnovative.com

1. Introduction

Third molar extractions are one of the most common and basic outpatient interventions in oral and maxillofacial surgery.¹ Depending on the location, depth, tooth angulation and bone density, the complexity of surgical extraction may vary, and is generally associated with post-operative pain, oedema, and trismus.² Recently some strategies have been developed for minimizing postoperative discomfort after third molar surgery, including the use of pharmacological therapy and alternative medicine,³ and complementary protocols like minimally-

invasive tooth extraction have been suggested for the postsurgical therapy of third molar surgery.⁴ However, patients still suffer some pain, swelling, and limitation in mouth mobility and other symptoms after surgery. Reducing dental malaise and postoperative complications is a critical issue for oral and maxillofacial surgery doctors.⁵

Zinc is a group IIb metal that is involved in diverse physiological processes such as growth, immune system modulation and tissue repair, and it acts as anti-inflammatory agent and can promote wound healing.⁶ Zinc has been shown to be effective in the prevention of oral mucositis, xerostomia, and pain associated with chemotherapy.⁷ A recent oncologic study showed zinc lozenge, showing a significant reduction in the use of

* Corresponding author.

E-mail address: tejashree.darshu@gmail.com (T. Rajanna).

analgesics for oral pain.⁸

The advantages of this treatment are: simplicity of execution, good tolerance of patients, absence of side effects or adverse reactions and high medical-social efficiency.⁹

At present, the clinical evidence regarding the effect of Zinc is sparse. In light of these findings, this study was designed to compare the efficacy of oral zinc lozenge given 30 min before surgery on reducing pain during 3 days after surgical extraction of mandibular third molars.

2. Materials and Methods

This prospective randomized controlled trial (RCT) was conducted between May 2019 and April 2020. It was reviewed and approved by the Institutional Ethics Committee; we recruited 70 patients after written informed consent form before the beginning of this study with mandibular-impacted third molar. Inclusion criteria: age between 18 and 30 years, American Society of Anesthesiology (ASA) score of 1 (i.e., no systemic diseases or medical conditions), no discernible active pathology associated with the third molars, no acute pericoronitis, and no periodontal disease. Exclusion criteria: contraindications of surgery; long-term administration of medication, recent administration of glucocorticoids, antibiotics, or recurrent pericoronitis of the impacted tooth; moderate caries of the wisdom tooth and adjacent teeth; periapical periodontitis, pulpitis, or periodontitis, anti-platelet or anticoagulant therapy, pregnancy or lactating, recent local infection within 15 days prior to surgery.

Sample size calculated based on previous studies, we presumed the incidence of postoperative pain to be 65%. Using power analysis, sample-size calculation revealed that 31 patients per group would be required to detect a 50% reduction in the incidence of postoperative pain, with $\alpha = 0.05$ and $\beta = 0.20$ for two-tailed statistical analysis. Therefore, each group included 35 patients.

We randomly divided patients into equal Zinc group and Control group, using a computer randomization generator, each with 35 patients. The double-blind method was used to conduct perioperative treatment for patients in the two groups. All patients received routine examination and dental X-ray film before surgery. The degree of swelling, index of limitation of mouth opening, and related data were measured before surgery.

All patients in the group received Lozenge 30 min before surgery, followed by every 6th hour for 72hrs.

1. Group Z (Zinc group) (n=35) - oral zinc lozenge (40mg)
2. Group C (Control group) (n=35) - oral lozenge as placebo.

Zinc lozenge - Zinc lozenge with 40 mg elemental zinc in the form of zinc citrate, matched with placebo lozenge, Placebo lozenge- containing sucrose, sodium free, and

calcium with xylitol, glucerin and which is indistinguishable in appearance and taste from the one containing Zinc lozenge. Lozenge will be provided by the staff nurse not involved in the subsequent assessment of the patient. Patients and operating surgeon will not be aware of the study drug.

All surgical procedures were performed by one oral and maxillofacial surgeon; aseptic scrubbing and draping were done. Under strict aseptic precautions, 2 ml of 2% lignocaine with 1:2,00,000 adrenaline was used for an inferior alveolar nerve block, following the hospital's protocol. Additionally, infiltration anesthesia was administered in the buccal fold and distal of the incision in the mandibular ramus region.

A standard Ward's incision or a modified Ward's incision was given for all the cases. In cases where the crown or part of crown of the tooth was visible intraorally, a standard ward's incision was placed. In cases where the tooth was completely covered by mucosa, a modified ward's incision was placed. To eliminate bias, the same incision was planned and placed for the control and study side. A full-thickness mucoperiosteal flap was raised to expose the tooth and surrounding alveolar bone. Buccal bone guttering was done using a round bur and a straight fissure bur no 701. The radiographs were analyzed preoperatively and the arc of rotation of the tooth was determined. Tooth sectioning was done using a straight fissure bur no 703 if interference to removal was found on analysis. After extraction, granulation tissue, follicular remnants and bony spicules were removed from the socket and closure with 3-0 silk sutures and control side-surgical extraction followed by closure with 3-0 silk sutures. Immediately after surgery, patients were given verbal and written postoperative instructions. Patients in both groups were provided with an ice pack for postoperative cooling, and were prescribed 3-day course of amoxicillin + clavulanate 1000 mg-twice daily, all patients were given comprehensive instructions on the importance of maintenance of oral hygiene and jaw physiotherapy postoperatively.

Detection of indexes and evaluation. The visual analog score (VAS) was adopted to evaluate the pain degree of patients. The score range was 0-10 (0 for no pain and 10 for intolerable severe pain). Standard: no pain: 0-1 points for no pain or little pain or pain hard to feel; mild: 2-3 points for tolerable pain that did not affect sleep; moderate: 3-6 points for pain that altered normal daily activities and sleep; severe: ≥ 7 points for intolerable pain, patients took a combination of ibuprofen 400 mg + Paracetamol 325 mg 1 tablet, The patient marked the appropriate response on the scale at 24 h, 48 h and 72h after surgery.

The measurements were obtained using a flexible ruler in the pre and post-operative periods of 6, 24, 48 and 72 h. The sum of the pre-operative measurements was considered the standard of normality for each side. After verification

of the measurements from the post-operative period, the difference between the measurements before and after the surgical procedure was observed, determining the level of oedema.

Trismus was evaluated by maximum buccal opening. The maximum inter-incisional vertical distance was measured using a digital caliper with two decimal places and transcribed in millimeters. The measurement considered the distance between the surfaces of the upper and lower right central incisors, after maximum opening without aid, pre-operatively and post-operatively 6, 24, 48 and 72 h. The amount of reduction of the buccal opening was measured and compared to the baseline. Thus, the relative mean for each patient between the final and initial measurements (Delta) was calculated.

2.1. Statistics

Statistical calculations were conducted using SPSS (Statistical Package for the Social Sciences) Version 24.0 (IBM Corporation, Chicago, USA). The parametric variables were presented as mean \pm SD and analyzed by Student t test or ANOVA and Pearson correlation test as appropriate, Chi-square or Mann-Whitney U test and Spearman correlation coefficients was performed for non-parametric samples. $P < 0.05$ was considered as statistically significant.

3. Results

A total of 70 patients were included in the study and randomly assigned to one of the groups. Thirty five patients received Zinc and thirty-five received placebo lozenge. There were no significant differences between two groups of patients with respect to age, sex, and BMI (Table 1).

The overall incidence of Pain in the Zinc group was 18% shown in green (Figure 1) compared to 43% in the Control group shown in red ($P = .003$) using generalized estimating equation with binomial probability distribution, logit link function, and auto regressive (AR) working correlation matrix resultant in odds ratio (95% confidence interval), 4.220 (2.082–14.587). Error bars represent 95% confidence interval.

Incidence of Pain in the Zinc group is shown in green (Figure 2) and the Control group in red. At time 6h, incidence of Pain in Zinc group was 0% compared to 24% of the Control group (adjusted $P = .004$); since the incidence of Pain at 6 hour in Zinc group was 0, the Hessian matrix was singular and some convergence criteria not satisfied, an accurate 95% confidence interval (CI) or odds ratio (OR) could not be reported; at time interval 24 hours, incidence of Pain was 10% in the Zinc group compared to 34% in the Control group (adjusted $P = .0495$) with OR 4.407 (95% CI, 2.407–14.939); at time interval 48 hours, incidence of Pain was 7% in the Zinc group compared to 29% in the

Control group (adjusted $P = .046$) with OR 4.828 (95% CI, 1.242–18.762); and at time interval 72 hours, the incidence of Pain was 13% in the zinc group compared to 24% in the Control group (adjusted $P = .209$) with OR 2.129 (95% CI, 0.654–6.930). Using generalized estimating equation with AR working correlation matrix and binomial probability distribution, $P < .05$ was considered statistically significant. Holm-Bonferroni method was used to adjust obtained P values (adjusted $P = (C - i + 1) \times p$, where C is the number of tests, i is the order of lowest to the highest unadjusted P values (1–4), and p is the unadjusted P value): at time point 6 hours, adjusted $P = (4 - 1 + 1) \times .001 = .004$; at 24 hours, adjusted $P = (4 - 2 + 1) \times .0165 = .0495$; at 48 hours, adjusted $P = (4 - 3 + 1) \times .023 = .046$; and at 48 h, adjusted $P = (4 - 4 + 1) \times .209 = .209$.

According to the VAS results of pain after surgery, the Zinc group exhibited significantly lower scores at each time point compared to the control group (Table 2), indicating more efficient pain reduction.

In terms of swelling degree after surgery, swelling decreased in both groups from day 1 to day 3 after surgery (Table 3). However, the Zinc group exhibited significantly lower swelling than the control group at each time point (Table 3), indicating more efficient swelling management.

The limitation of mouth opening degree decreased in both groups from day 1 to day 3 after surgery (Table 4). However, the Zinc group exhibited significantly lower scores than the Control group at each time point (Table 4), indicating more efficient functional recovery after surgery.

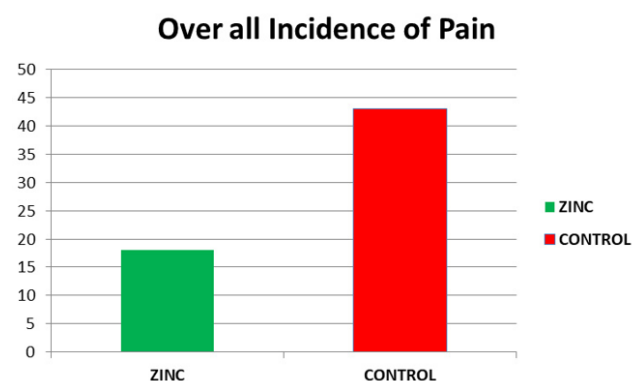


Fig. 1: Overall incidence of Pain

4. Discussion

The occurrence rate of complications after extraction of third molars can reach up to 20%. Therefore, effective prevention of complications in these procedures has become a key priority for dentists.¹⁰ Postoperative complications include pain, dry socket, face swelling, limited mouth opening, and other. These symptoms typically last for seven days, causing serious impact on the daily life

Table 1: Demographic Characteristics of Patients in Two Groups

Variables	ZINC (mean ± SD)	CONTROL (mean ± SD)	P Value
Age (year)	27.6 ± 11.5	26.3 ± 10.2	0.34
Male (%)	55	52.5	0.28
Weight (Kg)	72.3 ± 18.2	73.3 ± 17.7	0.30
BMI (kg/m ²)	21.2 ± 4.3	22.6 ± 3.6	0.26

Table 2: Pain by VAS scale

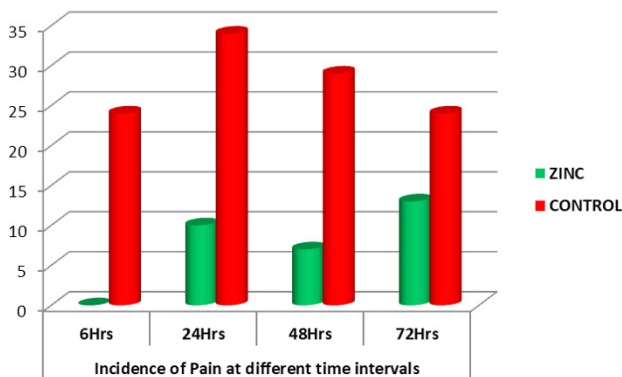
Group	Postoperative day 1	Postoperative day 2	Postoperative day 3
Zinc	5.35±1.14	4.06±1.13	2.23±1.02
Control	6.06±1.23	4.73±1.25	2.76±1.17
t-value	2.540	2.368	2.049
p-value	0.013	0.019	0.044

Table 3: Swelling degree after surgery

Group	Postoperative day 1	Postoperative day 2	Postoperative day 3
Zinc	2.23±0.34	1.23±0.13	0.23± 0.11
Control	2.85±0.43	1.98±0.27	1.01± 0.37
t-value	6.786	15.017	12.124
p-value	<0.0001	<0.0001	<0.0001

Table 4: Limitation of mouth opening

Group	Postoperative day 1	Postoperative day 2	Postoperative day 3
Zinc	2.15±0.34	1.16±0.33	0.43±0.12
Control	2.76±0.53	1.83±0.45	1.16±0.27
t-value	5.812	7.204	14.824
p-value	<0.0001	<0.0001	<0.0001

**Fig. 2:** Incidence of Pain at different time intervals

of patients.¹¹ Pain results from damaged tissues, which irritates the nerves. Destruction of tissue during surgery leads to edema and swelling of the face as part of the normal reactive edema. Moderate swelling is a protective reaction to trauma; however, excessive swelling has damaging consequences and even leads to infection.¹² The mechanism explaining the limited mouth opening is that cutting soft tissue during surgery irritates the temporal tendon and the muscle in nasal alar, causing a reflex spasm.¹³ Clinical

treatment of complications after tooth extraction include cold-hot compress, drainage tube, and oral administration of non-steroidal anti-inflammatory drugs. These treatments need to extend for a period after surgery to shorten the durations of pain, swelling, and limited mouth opening. The inflammatory response is the most basic reaction to injuries and is a necessary stage for injury repair after third molar extraction.¹⁴

The results of the present study showed overall incidence of 18% of Pain in group Zinc, while in Control group overall incidence of Pain was seen in 43% of the study subjects. Moreover, in our study there was a significant difference in Pain at 6h, 24h, 48h & 72 hour between Zinc and Control ($p < 0.05$). In the zinc group, the reduction in Pain is likely due to reduced localized inflammatory response as a result of decreased production of reactive oxygen species and subsequent reduction in COX-2 expression and PGE-2 production.¹⁵ This likely explains the significant difference in the incidence of Pain between the groups. The present study showed that oral zinc lozenge administered 30 min before surgery reduced the incidence of Pain, Swelling, and Trismus till 72h after surgery. Although the use of zinc sulphate did not decrease the incidence of Pain in patients, it decreased the intensity of Pain.

Tanmay Sarkar et al, conducted a study on 88 patients undergoing surgery with endotracheal intubation were randomly allocated into two groups, to either receive dispersible zinc tablet 40 mg or placebo tablet, 30 min preoperatively. At 4 h, there was a significantly lower incidence of post-operative sore throat (POST) in zinc group (6.8%) than the control group (31.8%) with a P value of 0.003. concluded that preoperative administration of 40 mg dispersible zinc tablet effectively reduces the incidence and severity of POST in the immediate postoperative period.⁹

Farhang B et al, studied 79 patients undergoing low- or moderate-risk surgery with endotracheal intubation were randomly assigned into 2 groups: Control group received placebo and zinc group received 40-mg zinc lozenges 30 minutes preoperatively. Observed that at 4 hours, there was a significantly lower incidence of POST in the zinc group, 7%, than the control group, 29% (P = .046). The incidence of POST at 0 hour was 0% in zinc group and 24% in control group (P = .004), concluded that the administration of a single dose of 40-mg zinc lozenge 30 minutes preoperatively is effective to reduce both incidence of POST in the first 4 hours and severity of mild and moderate POST in the immediate postoperative period.¹⁵

Wang MX, et al, reviewed to assess the effects of providing micronutrients singly through oral means, on cold incidence, and/or management (in terms of cold duration and symptom severity) in healthy adults from systematically searched randomized controlled trials, the quality of selected studies was assessed using the Cochrane risk of bias tool and certainty in the outcomes was assessed with the Grading of Recommendations Assessment, Development and Evaluation approach. The review found that micronutrients supplementation, mainly zinc supplementation was observed to potentially reduce cold duration by 2.25 days (when zinc is provided singly, 95% CI: -3.39, -1.12). This suggests that zinc supplementation may reduce the overall burden due to common cold among healthy adults.¹⁶

Leyva-Grado V et al, conducted a study on human respiratory tissues were to study inflammation and various treatment effects on respiratory epithelia. The cells and tissues were studied both in the presence and absence of bradykinin, one of the first inflammatory mediators of pharyngitis. Inflammation was measured by analyzing levels of prostaglandin E2 (PGE2), interleukin 8 (IL-8), and leukotriene B4 (LTB4), transepithelial electrical resistance (TEER), and lactate dehydrogenase (LDH) release. Tissue morphology was analyzed by immunohistochemistry results showed pharyngitis using organotypic human respiratory tissue stimulated with bradykinin, there was an increase in prostaglandin E2 (PGE2) and interleukin-8 (IL-8) in response to bradykinin. Acetyl salicylic acid (ASA), a non-specific COX inhibitor, was able to mitigate a bradykinin-induced increase in PGE2, concluded that, the complex mechanisms involved in

healing pharyngitis, an inflammatory condition of the upper respiratory epithelia.¹⁷

In these above-mentioned studies, it was suggested that the reduction in the incidence and severity of Pain, Swelling & Trismus was related with anti-inflammatory effects of the administered drugs. Similar to these previous studies, our study found that the zinc lozenge has reduced incidence and severity. Our study suggests that patients who received a single dose zinc sulphate preoperatively showed decreased symptoms with increased time (in the first 6 hours) and showed reduced incidence. Nevertheless, comparisons of the effectiveness of these treatments were performed in only a low number of small studies. Studies examining the comparative effectiveness of zinc versus other pharmacological drugs in preventing postoperative sequelae are still warranted.

5. Conclusion

In conclusion oral zinc lozenge administered 30 minutes preoperatively can reduce complications after third molar extraction, including pain, swelling, and limited mouth opening. Besides, Zinc can promote the recovery effect, improve the quality of life after surgery, and its administration is convenient, easy, economic, and has non-invasive characteristics that deserve wider clinical attention and application.

6. Conflicts of Interest

All contributing authors declare no conflicts of interest.

7. Source of Funding

None.

References

- Gurram P, Narayanan V, Chandran S, Ramakrishnan K, Subramanian A, Kalakumari AP, et al. Effect of heartfulness meditation on anxiety and perceived pain in patients undergoing impacted third molar surgery. *J Oral Maxillofac Surg.* 2021;doi:10.1016/j.joms.2021.04.027.
- Selvido DI, Bhattarai BP, Rokaya D, Niyomtham N, Wongsirichat N. Pain in Oral and Maxillofacial Surgery and Implant Dentistry: Types and Management. *Eur J Dent.* 2021;15(3):588–98. doi:10.1055/s-0041-1725212.
- Cho H, Lynham AJ, Hsu E. Postoperative interventions to reduce inflammatory complications after third molar surgery: review of the current evidence. *Aust Dent J.* 2017;62(4):412–9.
- Gulnazar Y, Alpan AL. Comparison of postoperative morbidity between piezoelectric surgery and conventional rotary instruments in mandibular third molar surgery: a split-mouth clinical study. *Med Oral Patol Oral Cir Bucal.* 2021;26(3):e269.
- Cosola S, Kim YS, Park YM, Giammarinaro E, Covani U. Cornectomy of Mandibular Third Molar: Four Years of Follow-Up of 130 Cases. *Medicina.* 2020;56(12):654. doi:10.3390/medicina56120654.
- Chinni V, El-Khoury H, Perera M, Bellomo R, Jones D, Bolton D, et al. Zinc supplementation as an adjunct therapy for COVID-19: challenges and opportunities. *Br J Clin Pharmacol.*

- 2021;87(10):3737–46. doi:10.1111/bcp.14826.
7. Gholizadeh N, Mehdipour M, Chavoshi SH, Kahani S, Sadrzadeh-Afshar MS. The effect of orally-administered zinc in the prevention of chemotherapy-induced oral mucositis in patients with acute myeloid leukemia. *Int J Cancer Manag.* 2017;10(8):e9252. doi:10.5812/ijcm.9252.
 8. Funato M, Ozeki M, Suzuki A, Ishihara M, Kobayashi R, Nozawa A, et al. Prophylactic effect of polaprezinc, a zinc-L-carnosine, against chemotherapy-induced oral mucositis in pediatric patients undergoing autologous stem cell transplantation. *Anticancer Res.* 2018;38(8):4691–7.
 9. Sarkar T, Mandal T. Preoperative oral zinc tablet decreases incidence of postoperative sore throat. *Indian J Anaesth.* 2020;64(5):409–14. doi:10.4103/ija.IJA_959_19.
 10. Byrne MJ, Tickle M, Glenny AM, Campbell S, Goodwin T, O'malley L, et al. A systematic review of quality measures used in primary care dentistry. *Int Dent J.* 2019;69(4):252–64.
 11. Alqooz F, Ghatam A, R. Mandibular Third Molar Postoperative Complications-A Brief Review. *Journal of the Bahrain Medical Society.* 2020;32(3):18–22.
 12. Tan Y, Li P. Bromelain has significant clinical benefits after extraction of the third molar during chemotherapy in patients with hematologic tumor. *Oncol Lett.* 2018;15(3):2962–6.
 13. Petropolis C, Antonyshyn O. Primary Repair of Soft Tissue Injury and Soft Tissue Defects. *Facial Trauma Surg.* 2020;p. 44–57. doi:10.1016/B978-0-323-49755-8.00012-8.
 14. Lima TC, Bagordakis E, Falci SG, Santos CRD, and MLP. Pre-emptive effect of dexamethasone and diclofenac sodium associated with codeine on pain, swelling, and trismus after third molar surgery: a split-mouth, randomized, triple-blind, controlled clinical trial. *J Oral Maxillofac Surg.* 2018;76(1):60–6.
 15. Farhang B, Grondin L. The effect of zinc lozenges on postoperative sore throat: a prospective randomized, double-blinded, placebo-controlled study. *Anesth Analgesia.* 2018;126(1):78–83.
 16. Wang MX, Win SS, Pang J. Zinc supplementation reduces common cold duration among healthy adults: a systematic review of randomized controlled trials with micronutrients supplementation. *Am J Trop Med Hygiene.* 2020;103(1):86–99.
 17. Leyva-Grado V, Pugach P, Latefi N. A novel anti-inflammatory treatment for bradykinin-induced sore throat or pharyngitis. *bioRxiv.* 2021;doi:10.1101/2020.11.06.370395.

Author biography

Tejashree Rajanna, Assistant Professor

Hemalatha B R, Senior Resident

Cite this article: Rajanna T, Hemalatha B R. The effect of zinc lozenges on pain, oedema, and trismus after impacted third molar surgery: A prospective randomized, double-blinded, placebo-controlled study. *J Dent Spec* 2021;9(1):13-18.