



Letter to Editor

Livedoid vasculopathy –Letter to editor

Siva Saumendra Sahoo¹, Sujata Panda¹, Shushruta Mohanty^{2,*}

¹Consultant Pathologist, NIDAN Diagnostic Centre, Berhampur, Odisha, India

²Dept. of Pathology, M.K.C.G MCH, Berhampur, Odisha, India



ARTICLE INFO

Article history:

Received 17-01-2022

Accepted 19-01-2022

Available online 28-02-2022

This is an Open Access (OA) journal, and articles are distributed under the terms of the [Creative Commons Attribution-NonCommercial-ShareAlike 4.0 License](https://creativecommons.org/licenses/by-nc-sa/4.0/), which allows others to remix, tweak, and build upon the work non-commercially, as long as appropriate credit is given and the new creations are licensed under the identical terms.

For reprints contact: reprint@ipinnovative.com

Dear Sir,

Livedoid vasculopathy (LV) as the name implies is a vasculopathy and not vasculitis. LV is a rare chronic non-inflammatory thrombotic vascular disorder. Clinically LV is characterized by painful recurrent purpuric eruptions and symmetric punched-out ulcerations, primarily located on the lower extremities, especially on ankles and over the malleoli. The ulcers heal after 3 to 4 months leaving an atrophic, stellate, ivory-to white, scar stippled with telangiectasia and surrounded by hyperpigmentation, known as atrophie blanche, which is hallmark lesion for LV.¹⁻³ We discuss here a case of Livedoid Vasculopathy in a 45 year old female patient throwing light on the clinical presentation, pathogenesis, histopathological features and treatment modalities of this rare vasculopathy.

A 45 years old obese female presented with persistent painful skin eruptions in the ankle region since 3 months. It started initially with multiple tender violaceous purpuric eruptions which later evolved to symmetric punched out small ulcers above and below the medial malleolus of the left ankle (Figure 1) over a period of time. The Ulcers had a thick crust over them that was tender on palpation. Few ulcers showed healing leaving an atrophic ivory white scar surrounded by hyperpigmentation. Pedal pulses were well palpable and it was not associated with

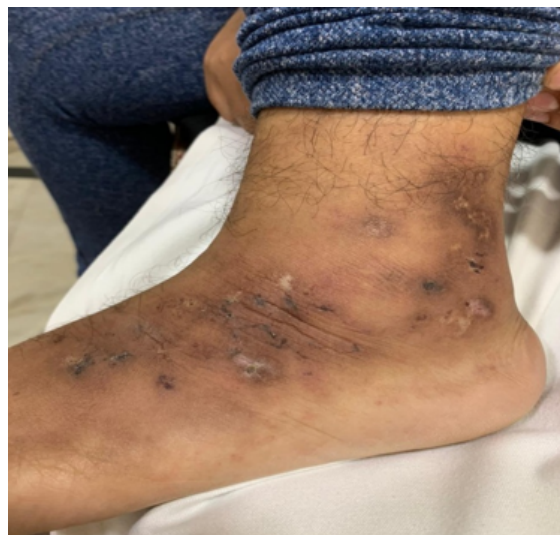


Fig. 1: Clinical Pic Showing purpuric eruptions and symmetric punched-out ulcerations, on ankles, at places shows healing leaving an atrophic, stellate, ivory-to white scars (atrophie blanche)

any inguinal lymphadenopathy. No edema or discharge was noted on the legs. She is a known hypertensive since 4yrs and her Blood pressure is under control as she is under medication. Other systemic examination were apparently normal. Skin biopsy from the lesion showed parakeratosis and inflammatory exudates over the

* Corresponding author.

E-mail address: sushruta.mohanty@gmail.com (S. Mohanty).

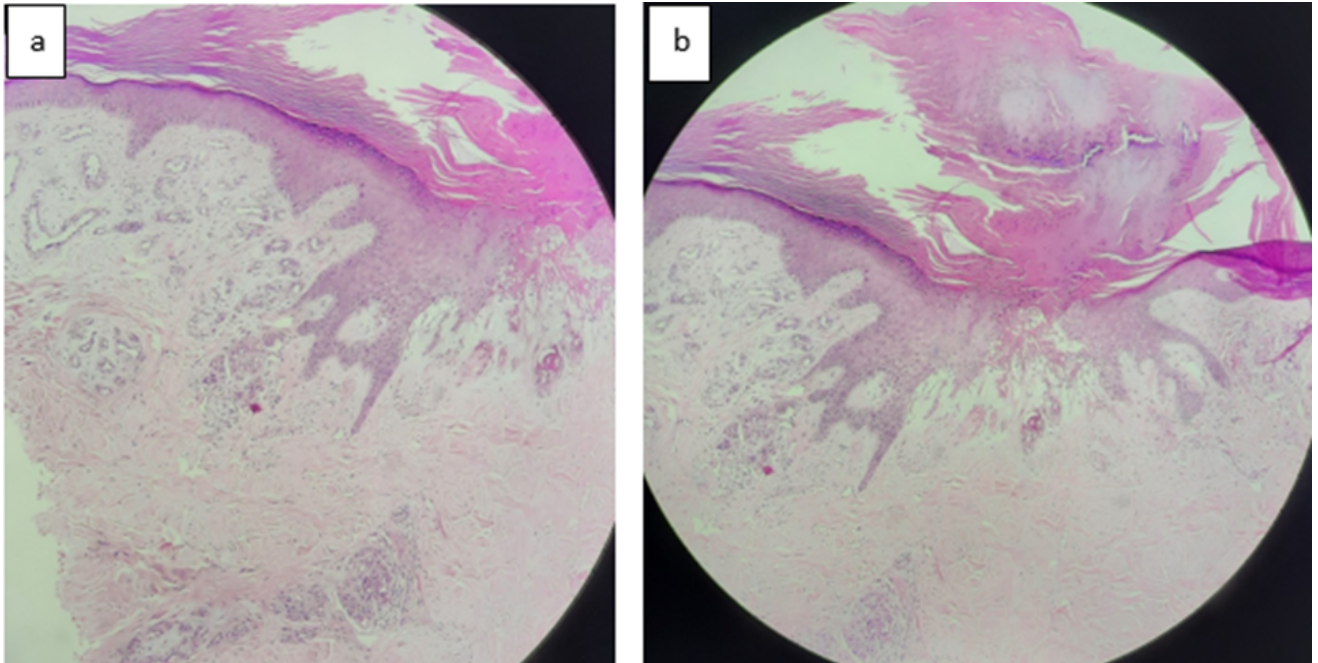


Fig. 2: a-b: 40x Scanner view showing parakeratosis and inflammatory exudates over the epidermis along with focal ulceration.

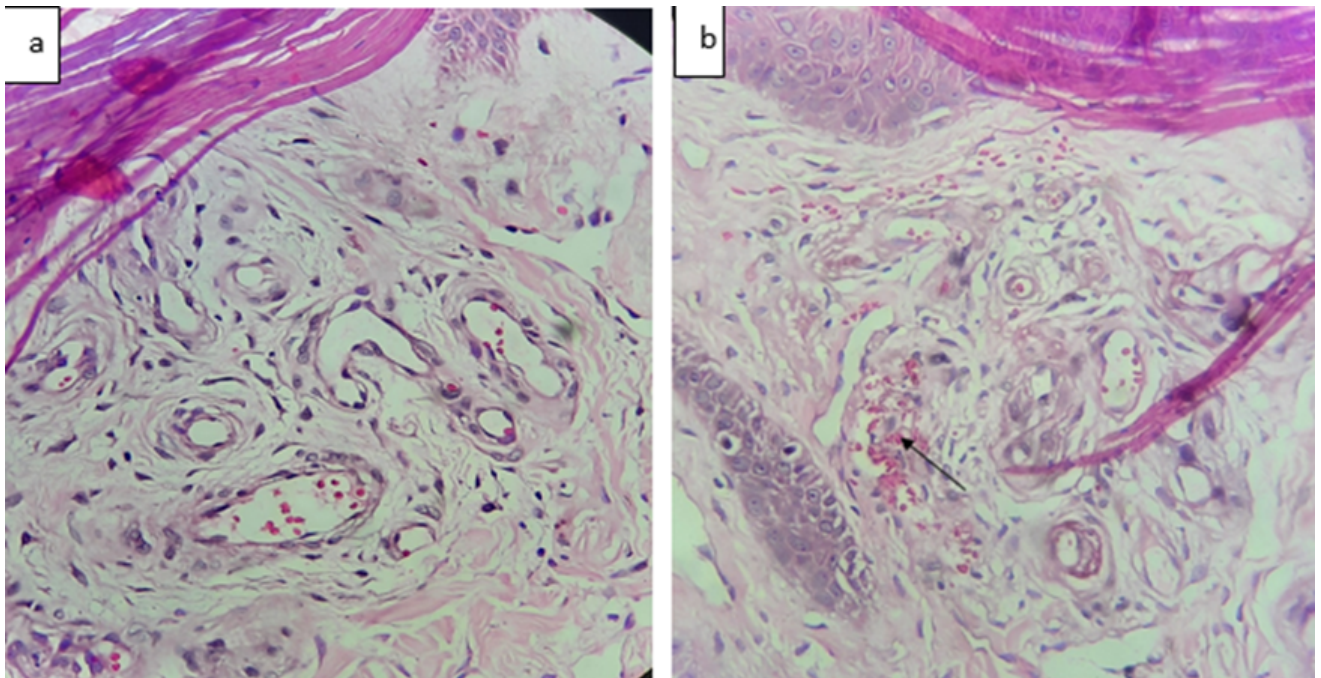


Fig. 3: a-b: low power view 100X- Showing vascular proliferation in superficial dermis; **b:** 100x Showing vascular proliferation in upper dermis with extravasation of RBC 's (black arrow)

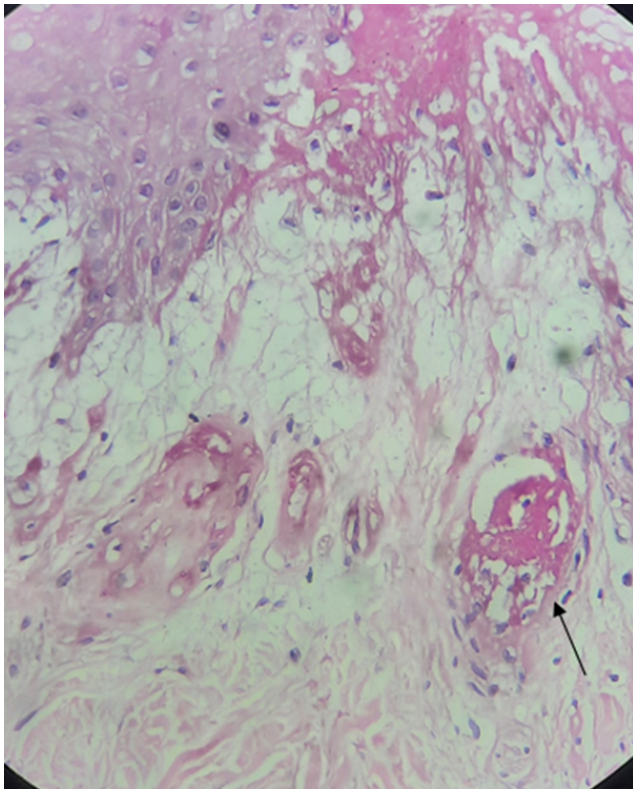


Fig. 4: Low power view - 100x Showing fibrinoid deposits in the vessel wall (black arrow).

epidermis along with focal ulceration, vascular proliferation in superficial dermis along with vascular luminal dilatation and thrombus formation in some vessels along with fibrinoid deposits. Focal extravasated RBC's are also seen (Figures 2, 3 and 4). Thinking along lines of vasculopathy a panel of investigations were done that includes CBC, LFT, RFT, anticardiolipin antibodies, lupus anticoagulant, prothrombin time, activated partial thrombin time, and protein C serum level that were negative or within normal limits. Based on the clinical, histopathological, and laboratory findings, the diagnosis of vasculopathic disease of skin, possibly livedoid vasculopathy secondary to venous insufficiency was made.

LV is a rare cutaneous vasculopathy, with an approximate incidence of 1:100,000. Females are more frequently affected than males.^{4,5} It is common in age group of 15 to 50 years old. LV is expedited by cold weather, prolonged walking, dependent position and chemical contact. Sporadically they are accompanied or preceded by livedo reticularis. An association with Raynaud's phenomenon, acrocyanosis and lipodermatosclerosis is recognized. Other auto immune diseases identified in concomitance with LV are Systemic lupus erythematosus, scleroderma, mixed and undifferentiated connective tissue diseases, polyarteritis nodosa, Sjogren's syndrome and rheumatoid arthritis.⁴ Usually dependent sites of the legs

are affected, and there is a bilateral involvement. It is divided into primary LV (idiopathic) and the secondary LV, which is associated with chronic venous hypertension or hypercoagulable states in 50% of patients. The causes of hypercoagulable states include antiphospholipid syndrome, protein C and S defects, factor V Leiden mutation, prothrombin mutations, hyperhomocysteinemia, antithrombin III deficiency, and sticky platelet syndrome.⁶⁻⁹ The pathogenesis is not known but it is thought to be due to local defect (primary LV) or systemic defect (secondary LV) in coagulation pathway with formation of fibrin thrombi within the dermal blood vessels.

Hallmark histopathological finding in case of LV is the absence of true vasculitis, fibrinoid material deposition in the vessel lumen, and hyalinized walls of the vasculature together with infarction of tissue. Distinctive findings on biopsy are concurrent intravascular deposition of fibrin and thrombosis occluding dermal blood vessels, segmental hyalinization along with proliferation of endothelium. There is only slight infiltration of lymphocytes around vessels.³ In early stage the distinguishing histopathologic feature is fibrin deposition in vessel wall and lumen of small vessels eventuating in their partial or complete occlusion. Minimal perivascular infiltrate of inflammatory cells is visualized. In atrophic lesions, histopathologically it is characterised by thinned out epithelium and sclerotic dermis. Walls of dermal vessels are thickened and their intima is hyalinized. Endothelial proliferation is seldom seen.

The main differential diagnosis of leg ulcers includes chronic venous ulcers, leukocytoclastic vasculitis, pyoderma gangrenosum, cutaneous polyarteritis nodosa, factitious dermatitis that were easily ruled out in our case.³ Sickle cell disease and hydroxyurea related leg ulcers can also mimic LV. Porcelain white scars in the setting of venous disease but without punctate ulcerations should be considered an unrelated syndrome. Venous ulcers (VU) is the main differential diagnosis in our case. VU are located above the medial malleolus similar to LV, however, VU tends to become larger, shallow with a border that is typically irregular, the bed is covered by a yellow fibrinous exudate, and lacks the other characteristic features of LV.^{10,11} PAN is onerous to differentiate clinically. Clinical characteristics attributed to PAN are tender subcutaneous nodules which ulcerate in due course of time. Histopathology of PAN divulges deep dermal vessel occlusion, extravasation of granulocytes around the vessels moreover the essential point of difference between PAN and LV is, PAN responds favorably to steroids while LV doesn't.¹²

The risk factors for chronic venous insufficiency in our patient include the age, female gender, obesity and hypertension. LV is a formidable disease to treat and treatment is thus challenging for the dermatologist. A conglomerate of treatment options exist. However

the current approach is based on drugs that stimulate endogenous fibrinolytic activity, inhibit thrombus formation or cause vasodilatation.² Multiple treatments have been proposed, that includes antiplatelet drugs like low-dose aspirin, dipyridamole and pentoxifylline. To mitigate pain, the use of Hyperbaric oxygen and intravenous immunoglobulin is recommended as it enhances perfusion by impeding vasoconstriction caused by thromboxane and endothelin. Some studies have also investigated the use of anticoagulant drugs such as warfarin, unfractionated heparin, or low molecular weight heparin, all of which have been found to help with pain relief and hasten healing. Anabolic steroids like danazole and stanazole; and nifedipine and fibrinolytics like tissue plasminogen activator, danazol, phenformin, ethylestrenol are other treatment options.

LV is an uncommon dermatopathy, that can potentially be idiopathic or may emerge by virtue of vascular coagulopathy resulting in occlusion of superficial dermal microvasculature. Ruling out hypercoagulable states and autoimmune disorders is an essential part of the disease work up.

Conflict of Interest

The authors declare that there is no conflict of interest.

Source of Funding

None.

References

1. Murphy S, Boneparth A, Pappert A, Moorthy LN. A pediatric case of atrophie blanche secondary to livedoid vasculopathy. *Ann Paediatr Rheum.* 2016;5(3):79–84.
2. Tubone MQ. Livedoid vasculopathy associated with peripheral neuropathy: a report of two cases. *Anais Bras de Dermatologia.* 2013;88(6):227–9.
3. Criado PR, Rivitti EA, Sotto MN, Valente NY, Aoki V, Carvalho JF, et al. Livedoid vasculopathy: an intriguing cutaneous disease. *Anais*

Bras Dermatologia. 2011;86(5):961–77.

4. Vasudevan B, Neema S, Verma R. Livedoid vasculopathy: A review of pathogenesis and principles of management. *Indian J Dermatol Venereol Leprol.* 2016;82(5):478–88. doi:10.4103/0378-6323.183635.
5. Okada E, Nagai Y, Ishikawa O. A case of widespread livedoid vasculopathy with pain but no systemic symptoms. *Acta Derm Venereol.* 2008;88(3):298–9. doi:10.2340/00015555-0413.
6. Alavi A, Hafner J, Dutz JP, Mayer D, Sibbald RG, Criado PR, et al. Livedoid vasculopathy: An in-depth analysis using a modified Delphi approach. *J Am Acad Dermatol.* 2013;69(6):1033–42. doi:10.1016/j.jaad.2013.07.019.
7. Alesa D, Hawsawi KA, Alahmadi BS, and DIA. Livedoid vasculopathy: A case report and review of literature. *Int J Med Res Prof.* 2018;4(1):475–6. doi:10.21276/ijmrp.2018.4.1.099.
8. Herrero C, Guilbert A, Mascaró-Galy JM. Livedo reticularis de las piernas: Metodología de diagnóstico y tratamiento. *Actas Dermosifiliogr.* 2008;99(8):598–607. doi:10.1016/S1578-2190(08)70327-5.
9. Criado PR, Rivitti EA, Sotto MN, Valente N, Aoki V, Carvalho JF, et al. Livedoid vasculopathy: an intriguing cutaneous disease. *Ann Bras Dermatol.* 2011;86(5):961–77. doi:10.1016/j.autrev.2010.11.008.
10. Keller MS, Lee J, Webster GF. Livedoid Thrombotic Vasculopathy Responding to Doxycycline Therapy. *J Clin Aesth Dermatol.* 2008;1(4):22–4.
11. Callen JP. Livedoid vasculopathy: what it is and how the patient should be evaluated and treated. *Arch Dermatol.* 2006;142(11):1481–2. doi:10.1001/archderm.142.11.1481.
12. Kerk N, Goerge T. Livedoid vasculopathy - current aspects of diagnosis and treatment of cutaneous infarction. *J Dtsch Dermatol Ges.* 2013;11(5):407–10. doi:10.1111/ddg.12064.

Author biography

Siva Saumendra Sahoo, Consultant Pathologist

Sujata Panda, Consultant Pathologist

Shushruta Mohanty, Assistant Professor

Cite this article: Sahoo SS, Panda S, Mohanty S. Livedoid vasculopathy –Letter to editor. *IP J Diagn Pathol Oncol* 2022;7(1):79–82.