



## Original Research Article

## Utility of FNAC in diagnosis of thyroid lesions and to correlate histopathological studies

M Ruchika Reddy<sup>1</sup>, S Rajyalakshmi<sup>1,\*</sup>, V Indira<sup>1</sup>, M Hima Bindu<sup>2</sup>,  
C Mallikarjuna Reddy<sup>2</sup>

<sup>1</sup>Dept. of Pathology, Malla Reddy Institute of Medical Sciences, Hyderabad, Telangana, India

<sup>2</sup>Dept. of Microbiology, Malla Reddy Institute of Medical Sciences, Hyderabad, Telangana, India



## ARTICLE INFO

## Article history:

Received 27-09-2021

Accepted 13-11-2021

Available online 28-02-2022

## Keywords:

FNAC

Sensitivity

Specificity

Diagnostic Accuracy

Histopathology

## ABSTRACT

**Introduction:** The Incidence and prevalence of Thyroid lesion is gradually increasing and has become common among women. Thyroid cancer is most common cancer of endocrine system and occurs in all age groups including children. Fine needle aspiration cytology is the first line diagnostic method of Thyroid nodules and is rapid, cost effective and a minimally invasive procedure. Therefore it is widely accepted and more thyroid cases are diagnosed at an early stage. The aim of this study is to assess the Diagnostic accuracy of FNAC by correlating its results with histopathological findings.

**Materials and Methods:** FNAC procedure was performed on 50 patients with thyroid swellings under aseptic conditions after taking consent of the patient. The results obtained by FNAC were compared with Histopathological findings.

**Results:** Out of 50 cases, 47 were female and 3 were male. The age of presentation ranged from 16 to 71 years in our study with the mean age being 43.5. Most of cases were of Nodular goiter (23%) followed by Multi Nodular goiter(21%) followed by Hashimoto thyroiditis (18%). Sensitivity of our study was 73.91% and Specificity of our study was 80.95% and diagnostic accuracy was 75%.

**Conclusion:** Awareness and understanding of thyroid lesions is of great importance as most of these disorders can be treated medically or by surgical intervention. FNAC, which is simple, minimally invasive and rapid procedure, has low false positive rate for diagnosis of thyroid malignancy at an early stage. It can be used as first line method in assessing the nature of lesion.

This is an Open Access (OA) journal, and articles are distributed under the terms of the [Creative Commons Attribution-NonCommercial-ShareAlike 4.0 License](https://creativecommons.org/licenses/by-nc-sa/4.0/), which allows others to remix, tweak, and build upon the work non-commercially, as long as appropriate credit is given and the new creations are licensed under the identical terms.

For reprints contact: [reprint@ipinnovative.com](mailto:reprint@ipinnovative.com)

### 1. Introduction

Thyroid is a butterfly shaped gland present in the anterior part of neck. Neck swelling is a common clinical presentation of which thyroid swellings are the most common. They carry significant morbidity and mortality if not treated appropriately.

The incidence and prevalence of thyroid lesion is gradually increasing and has become common among women. Thyroid cancer is most common cancer of

Endocrine system and occurs in all age groups including children. Thyroid cancer is the fastest growing cancer in both men and women The prevalence is 3%-7% by palpation and 17%-19% by high resolution ultrasound.<sup>1</sup> The prevalence of thyroid cancer is more common in South India than in North India.<sup>2</sup> The prevalence of goiter is more than 40 million in India with more than 2 billion globally.<sup>3</sup> According to recent studies, India is expected to have highest number of cases by the year 2020 after US.<sup>4</sup>

The majority of clinically diagnosed cases are non-neoplastic, therefore it is very important to differentiate between neoplastic and non neoplastic lesions. Most

\* Corresponding author.

E-mail address: [mani.makani@gmail.com](mailto:mani.makani@gmail.com) (S. Rajyalakshmi).

isolated swellings are benign, but it is difficult to exclude malignancy without excision and histological examination.

Fine needle aspiration cytology (FNAC) is the first line diagnostic method in diagnosing Thyroid nodules. It is rapid, cost effective and minimally invasive procedure and it has excellent patient compliance. FNAC is particularly suitable in thyroid where an incisional biopsy may present problems. The lesions in thyroid are varied and they range from simple inflammation to neoplasm.<sup>5</sup> FNAC helps to categorize these lesions. It has been estimated that only 5% are malignant which require immediate intervention. The anaplastic and poorly differentiated lesions can be planned for palliative radiotherapy or chemotherapy.<sup>6</sup> Therefore, it is widely accepted and more thyroid cases are diagnosed at an early stage. It helps to distinguish benign and malignant lesions thereby reducing burden of surgical intervention and increases scope of medical management.<sup>7</sup>

Since there are very few studies comparing FNAC and histopathology for thyroid lesions in our geographical locality, we have performed this study to assess the sensitivity and specificity of FNAC by correlating its results with histopathological findings.

## 2. Materials and Methods

### 2.1. Inclusion criteria

All patients aged above 16 years and both sexes.

### 2.2. Exclusion criteria

Pregnant women and Patients with Parathyroid swellings.

This Diagnostic type of study was done both retrospectively and prospectively of 50 patients who presented with swelling in neck to the Department of General Surgery and Department of Pathology in Malla Reddy Institute of Medical Sciences, Telangana (India) during the period Jan 2019 to October 2019. This study was conducted after obtaining the approval from ethical committee and informed consent from the patients under study.

All patients were evaluated by thorough history and clinical examination. General diagnostic tests such as Random Blood Sugar, Lipid and Kidney profile, Complete Blood Picture, Erythrocyte Sedimentation Rate, tests for HIV, HBC and HCV was done for all of them.

For prospective cases, FNAC procedure was performed on the patients with Thyroid swellings in aseptic condition by using 24 gauge needle. The aspirated material was immediately transferred onto glass slides. Multiple smears were prepared and were fixed in ethanol with proper care and were later stained with Papanicolaou Stain. For retrospective cases, the records of patients who have undergone FNAC were collected from patients files.

Post operative thyroidectomy specimens were preserved and sent for histopathological examination.

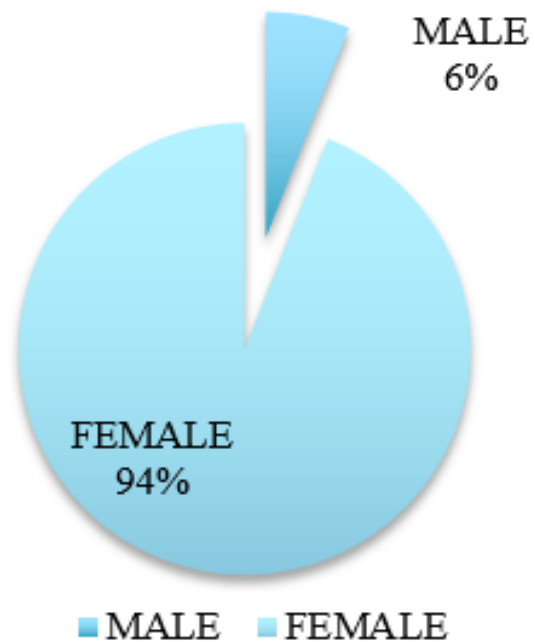
Histopathological examination was done after thyroidectomy specimens and sections of the specimens were obtained and placed on glass slides and chemical fixation was done by formalin and dehydration is obtained by treating the specimen with alcohol. Clearing was done to impart transparency and staining was done by haematoxylin and eosin. The results obtained by FNAC were compared with histopathological findings.

### 2.3. Statistical analysis

Descriptive analysis was done in Microsoft Excel using pie graphs, bar charts and tables.

## 3. Results

Out of the total 50 patients in the study who presented with thyroid swelling, 45 underwent surgical excision. 47 (94%) of the total patients were female and 3 (6%) were male (Figure 1). The female to male ration was 15.3:1.



**Fig. 1:** Gender distribution of patients

The age of the patients ranged from 16 to 71 years in our study with the mean age being 43.5 years. The peak age of incidence was seen in third decade i.e between 23 – 36 years. This was followed by the age between 37-43 years and 44 – 50 years (Figure 2)

Out of 50 cases, 49 (98%) were palpable on clinical examination, while only 1 (2%) was non palpable (Table 1).

In our study most of the cases were of Nodular goitre (23%) followed by Multi Nodular goitre(21%) followed by Hashimoto thyroiditis (18%).

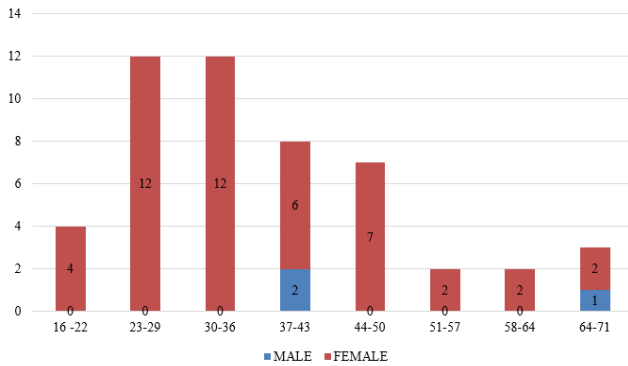


Fig. 2: Age-wise distribution of the patients

Table 1: Categorization of swellings

Title	Number	Percentage
Palpable swellings	49	98%
Non-palpable swellings	1	2%

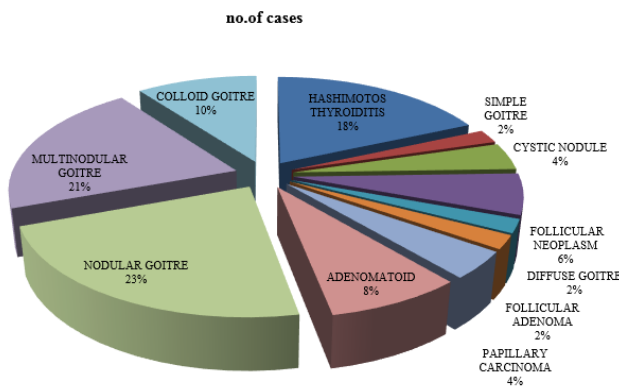


Fig. 3: Type of swellings

Among Benign lesions majority were Nodular goitre.(23%) and among the Malignant lesions majority were of Papillary Carcinoma. (4%). All the malignant cases diagnosed by FNAC were confirmed as malignant by histopathological examination implying 100%correlation.

Out of the total 11 cases of nodular goitre as identified by FNAC, only 3 of them correlated with the histopathological findings, while 8 of them did not correlate with HPE. Out of 10 multinodular goitre in our study, 5 (50%) were identified by HPE also, while 5 (50%) did not correlate. 4 of Hashimoto's thyroiditis were identified by both FNAC and HPE while 5 (55%), FNAC did not correlate with HPE findings. However, follicular neoplasms, follicular adenoma and papillary carcinoma were identified by both FNAC and HPE (Table 2). Among the unrelated cases, more number of the HPE cases were follicular adenoma and adenomatous goitre.

The sensitivity of FNAC was 73.91%, while it was 80.95% specific. The positive predictive value of FNAC was

80% and the negative predictive value was 73% (Table 3)

#### 4. Discussion

In our study female: male ratio was 15.3:1 and majority of patients were in age group 21-30years. The findings were comparable to the studies of Aramani et al.<sup>8</sup> Sengupta et al observed a female: male ratio of 4:1,<sup>9</sup> Khageswar Rout et al observed 2.3:1<sup>10</sup> and Guhamallick et al reported 2.3:1,<sup>11</sup> all of which was lower than our observations.

In our study, most common cases were of Solitary Thyroid Nodule -(23% ) followed by Multi Nodular Goitre -(21%), which were similar to study conducted by Tonape et al<sup>12</sup> who reported 42.85% solitary nodule and 17.14 multinodular goitre. Bhansali et al reported an incidence of 38.2% of colloid goitre.<sup>13</sup>

Among benign, most of the cases (23%) were of Nodular Goitre and among malignant (4%) were of Papillary Carcinoma. In our study, all malignant cases identified by FNAC (follicular or papillary) were proven to be malignant by histopathological examination indicating 100%correlation. 7 cases were diagnosed as suspicious of malignancy by FNAC, which on histopathology were confirmed to be benign. This is in contrary to results obtained by other studies like Selvaggi et al.<sup>14</sup> Therefore, it is reasonable to consider patients with suspicious FNAC results.

100% correlation was seen for the cases of Follicular Neoplasm, Follicular Adenoma,Papillary Neoplasm. Among Benign lesions, highest correlation was obtained for Follicular Adenoma (100%) followed by Adenomatoid Goitre (50%) and Multi Nodular goitre (50%). Forty four percent correlation was seen in the cases of hashimoto thyroiditis and twenty seven percent cases was seen in cases of nodular goitre.

No corelation was seen in cases of simple goitre, cystic nodule, diffuse goitre and colloid goitre (0%).

The value of any Diagnostic test depends in its ability to detect presence of disease when it is present (Sensitivity) and absence of disease when it is not present (Specificity).Sensitivity andSpecificity of FNAC in diagnosing type of lesion irrespective of benign or malignant, gender and age is 96% and 5%respectively.

Sensitivity and Specificity of FNAC in diagnosing type of lesion irrespective of benign and malignant within age group of 40 years is 65% and 36%.

Sensitivity and Specificity of FNAC in differentiating benign and malignant lesions in our study is 73.91% and 80.95% respectively. Diagnostic accuracy is 75%. Positive predictive value is 80% and Negative predictive value is 73%. These results were corroborated by other studies as described in Table 4.

**Table 2:** Table showing percentages of individual lesions:

S.No.	Type of lesion	Correlation	Percentage	Non correlation	Percentage
1	Nodular goitre	3	27.27%	8	72.7%
2	Multinodular goitre	5	50%	5	50%
3	Hashimotos thyroiditis	4	44%	5	55%
4	Simple goitre	0	0	1	100%
5	Cystic nodule	0	0	2	100%
6	Follicular neoplasm	3	100%	0	0
7	Diffuse goitre	0	0	1	100%
8	Follicular adenoma	1	100%	0	0
9	Papillary carcinoma	2	100%	0	0
10	Adenomatoid goitre	2	50%	2	50%
11	Colloid goitre	0	0	5	100%

**Table 3:** Diagnostic accuracy of FNAC in differentiating benign and malignant lesions:

Sensitivity	73.91%
Specificity	80.95%
Positive predictive value	80%
Negative predictive value	73%

**Table 4:** Comparison of Sensitivity and Specificity of FNAC in diagnosing thyroid lesions with other studies

Study	Yr of study	Sensitivity	Specificity	Accuracy	Positive predictive value	Negative predictive value
Bagga et al <sup>7</sup>	2010	66%	100%	96.2%	100%	96%
Moose et al	2010	77.7%	97.67%	96.9%	82.1%	94.6%
Hathila et al <sup>15</sup>	2016	87.5%	96.15%	95%	77.7%	98.03%
Presentstudy	2019	73.91%	80.95%	75%	80%	73%

## 5. Conclusion

FNAC is very safe, cost effective, quick procedure with great patient compliance and is accepted across the world as gold standard for screening of thyroid lesions. But it has its own limitations like it depends on efficiency and skill of performing expert as well as experience of Pathologist interpretation of the aspirate in forming definitive diagnosis. Therefore careful procurement, appropriate sample preparation and accurate interpretation by pathologists is necessary. An appropriate diagnosis can be offered when all these steps are taken into consideration.

## 6. Conflict of Interest

The authors declare that there is no conflict of interest.

## 7. Source of Funding

None.

## References

- Jha A, Sinha A. A Study to evaluate the size of thyroid nodules as an indication of malignancy. *Academia J Surg.* 2020;3(1):16–20. doi:10.47008/ajs/2020.3.1.4.
- Indu E, Mathew A, Mathew. Rising thyroid cancer incidence in Southern India; An Epidemic of overdiagnosis. *J Endocrine Soc.* 2017;1(5):480–7.
- Shahsn J. goitreandgoitrogenesis -some insights. *J Assoc Phys India.* 2000;48(1):13–7.
- Ekathaann john /TNN; What ails thyroid cancer management in India (September-22-2016); 2016.
- Luck CP, Srirangaramasamy J, Balamurugan M, Arumugam B, padmavathy A, Revathy, et al. Evaluation of diagnostic accuracy of FNAC and correlation with histopathology in thyroid lesions. *Trop J Pathol Microbiol*;3(2):96–101.
- Yeung M, Serpell JW. Management of the solitary thyroid nodule. *Oncologist.* 2008;13(2):105–12.
- Bagga PK, Mahajan NC. Fine needle aspiration cytology of Thyroid swellings ;How useful and accurate is it? *Indian J Cancer.* 2010;47(4):437–42. doi:10.4103/0019-509X.73564.
- Aramani SS, Gururajaprasad C. A cytohistopathological correlation of thyroid lesions with critical evaluation of discordant cases: An experience at a tertiary care hospital. *Cytohistopathological Correlation Thyroid Lesions.* 2017;4(3):243–8. doi:10.21276/APALM.1154Shakuntala Sunil Aramani1\* and Gururajaprasad. C2.
- Sengupta A, Pal R, Kar S, Zaman FA, Sengupta S, Pal S, et al. Fine needle aspiration cytology as the primary diagnostic tool in thyroid enlargement. *J Nat Sci Biol Med.* 2011;2(1):113–8.
- Rout K, Ray CS, Behera SK, Biswal R. A Comparative Study of FNAC and Histopathology of Thyroid Swellings. *Indian J Otolaryngol Head Neck Surg.* 2011;63(4):370–2.
- Guhamallick M, Sengupta S, Bhattacharya NK, Basu N, Roy S, Ghosh AK, et al. Cytodiagnosis of thyroid lesions -usefulness and pitfalls. A study of 288 cases. *J Cytol.* 2008;25(1):6–9.
- Tonapet A, Shettyi, Lada, Batrag, Rege I. clinico- pathological correlation of thyroid swellings. *journal of medical science and clinical research.* 2016;4(12):14382–85.

13. Bhansalis K. Surgery of thyroid gland : The state of art. *Indian J Surg.* 1985;p. 217-27. **S Rajyalakshmi**, Associate Professor
  14. Bakhos R, Selvaggi SM, Dejong S, Gordon DC, Pitale SU, Hermann M, et al. fine needle aspiration of thyroid rate and causes of cytohistopathological discordance. *Diagn Cytopathol.* 2000;23(4):233-7. **V Indira**, HOD
  15. Hathila R, Patel S, Vaghela P, Makwana G, Parmar P. Cytology findings of the thyroid lesions with the histopathology findings correlation. *Int J Med Sci Public Health* ;5(4):642-6. **M Hima Bindu**, Professor
- C Mallikarjuna Reddy**, Professor

### Author biography

**M Ruchika Reddy**, Internee

**Cite this article:** Reddy MR, Rajyalakshmi S, Indira V, Bindu MH, Reddy CM. Utility of FNAC in diagnosis of thyroid lesions and to correlate histopathological studies. *IP J Diagn Pathol Oncol* 2022;7(1):13-17.