

Content available at: <https://www.ipinnovative.com/open-access-journals>

IP Journal of Diagnostic Pathology and Oncology

Journal homepage: <https://www.jdpo.org/>

Original Research Article

Study of clinico-pathological characteristics of colonic polyp seen at a tertiary care hospital in East India

Amar Kumar¹, Swati Sucharita Giri^{1,*}, Sneha Singh²¹Dept. of Pathology, Patna Medical College and Hospital, Patna, Bihar, India²Patna Medical College and Hospital, Patna, Bihar, India

ARTICLE INFO

Article history:

Received 29-04-2022

Accepted 30-04-2022

Available online 19-05-2022

Keywords:

Colonic Polyp
tubular adenoma
dysplasia

ABSTRACT

Introduction: Colorectal polyps are unusual growths of epithelial tissue projecting from the mucosa of the large bowel. This study aimed to evaluate the frequency of histological pattern of polyp among colorectal polypectomy specimen concerning age, sex, size, and site and histopathological features and associated dysplasia.

Materials and Methods: The study was done in the Pathology department in collaboration with the Gastroenterology Department on 115 patients. Biopsy was processed and histopathological features were studied with presence or absence of dysplasia.

Result: Most patients had constipation (40.87%) followed by rectal bleeding (40.00%) followed by pain abdomen and anemia. Male patients were 76(66.08%) followed by 39(33.91%) female patients. Among male patients most are of age range of 50-59yr (18.42%) and in females were of age range of 60-69yr. (25.64%). Grossly most polyp are of pedunculated shape (74.78%) followed by ulcerated type (13.04%) and least was of sessile appearance (12.17%). Most polyp were found in left side (descending colon: 40.87%) followed by rectum, ascending colon, sigmoid colon and transverse colon with least with caecum. Most Polyps size < 1 cm (90.40%) followed by size of polyp > 1 cm (9.60%). Regarding the histopathological evaluation of polyp we have reported tubular adenoma (53.91%) followed by hyperplastic polyp (19.13%) followed by tubulovillous adenoma (13.04%). Most of the polyp showed no dysplasia (94.64%) and dysplasia if seen both in tubular adenoma and tubulovillous adenoma.

Conclusion: Colonoscopy is the most important tool in the detection of colonic polyp because of premalignant nature.

This is an Open Access (OA) journal, and articles are distributed under the terms of the [Creative Commons Attribution-NonCommercial-ShareAlike 4.0 License](https://creativecommons.org/licenses/by-nc-sa/4.0/), which allows others to remix, tweak, and build upon the work non-commercially, as long as appropriate credit is given and the new creations are licensed under the identical terms.

For reprints contact: reprint@ipinnovative.com

1. Introduction

Colonic Polyp are unusual growths of epithelial tissue projecting from the mucosa of the large bowel. They may be classified according to their gross appearance (sessile or pedunculated), histopathological features (hyperplastic, adenoma, etc.), and behavior (benign or malignant). The biggest concern is their ability to progress into adenocarcinoma, through the adenoma to carcinoma

sequence due to genetic mutation.¹⁻³ The prevalence of colonic polyps in western population parallels the colorectal carcinoma rate and varies between 6.8% to as high as 22%. Prevalence rate in India also differs among regions with a range of 5.1% - 12%.^{4,5}

With the use of Colonoscopy as an outpatient procedure to see inside of the colon and rectum and used in screening, diagnostic and therapeutic of rectal and colon diseases.⁶ Most of the colorectal carcinoma (80-90%) originates in association with polyp which progress to dysplasia and if untreated progress to adenocarcinoma

* Corresponding author.

E-mail address: amarkumarsah2009@gmail.com (S. S. Giri).

in situ and invasive adenocarcinoma.⁷ Early recognition of these polyps and colonoscopic polypectomy following histopathological examination are important for identifying the neoplastic type of the lesion for further patient management. This study aimed to evaluate the frequency of histological pattern of polyp among colorectal polypectomy specimen concerning age, sex, size, and site and with special emphasis on type of polyp and associated dysplasia.

2. Material and Methods

The study was done in the Pathology department in collaboration with the Gastroenterology Department on 115 patients in one year time who were sent for colonoscopy as per their clinical presentation. All data regarding demographical profile including age, gender & indication for colonoscopy was noted. Colonoscopies were done on these patients and if polyp seen were excised and sent to pathology department in 10% neutral buffer formalin container. A total of 115 polyps were sent for histopathological study. All the biopsy specimen was put in 10% neutral buffer formalin for 24 hours for fixation.

The biopsies were grossly examined with emphasis on size, external surface, and cut surface. These findings were recorded and the representative bits were given. The tissue was processed and was cut into five-micron sections. Slides were stained with Haematoxylin-Eosin stain. The colonoscopic findings were obtained from the patient's record file and histopathological forms. The histopathological features were studied by Pathologist and types the polyps were reported based on histology and presence or absence of dysplasia.

Patient data were entered in Microsoft Excel and descriptive data analysis was done. Data regarding the location of the polyp, number of polyp and morphological details including presence and absence of stalk and histology of the polyps were recorded. Details regarding the presence of dysplasia were also noted.

2.1. Inclusion criteria

Patients who went through Colonoscopy with polyp removal were only incorporated in this study.

2.2. Exclusion criteria

Patients having inflammatory bowel disease or previously diagnosed follow up cases of colon malignancy were excluded from this study.

3. Result

The present study was done on 115 colonic biopsy were received by Department of Pathology from the gastroenterology Department. Most of the patient had come to Gastro department having clinical presentation like

constipation (40.87%) followed by rectal bleeding (40.00%) followed by pain abdomen and anemia. The majority of biopsies were of male patients 76(66.08%) followed by 39 (33.91%) female patients. Among male patients most were in age range of 50-59yr (18.42 %) and in females most of the patients were of age range of 60-69yr. (25.64%)

Colonoscopic examinations were done for these patients and following gross features were noted like polyp appearance, size and site of the lesions are noted. Most polyp are of pedunculated shape (74.78%) followed by ulcerated type (13.04%) and least was of sessile appearance (12.17%). In respect to site of the lesion , most of the polyp were found in left side (descending colon: 40.87%) followed by rectum (24.35%) then by ascending colon (13.91%) and sigmoid colon(8.70%) and transverse colon (6.96%) and lastly by caecum (5.22%). Regarding the size of polyp most of the Polyps size were less than 1 cm (90.40%) followed by size of polyp by more than 1 cm (9.60%).

Regarding the histopathological evaluation of polyp we have reported tubular adenoma (53.91%) followed by hyperplastic polyp (19.13%) followed by tubulovillous adenoma (13.04%). The lesser commoner were Juvenile polyp (11.30%) and retention polyp (2.61%).

Most of the polyp showed no dysplasia (94.64%). The dysplasia were seen more in adenomatous polyp showing high grade dysplasia in form of nuclear stratification and broadening of nuclei with equal proportion both in tubular adenoma and tubulovillous adenoma.

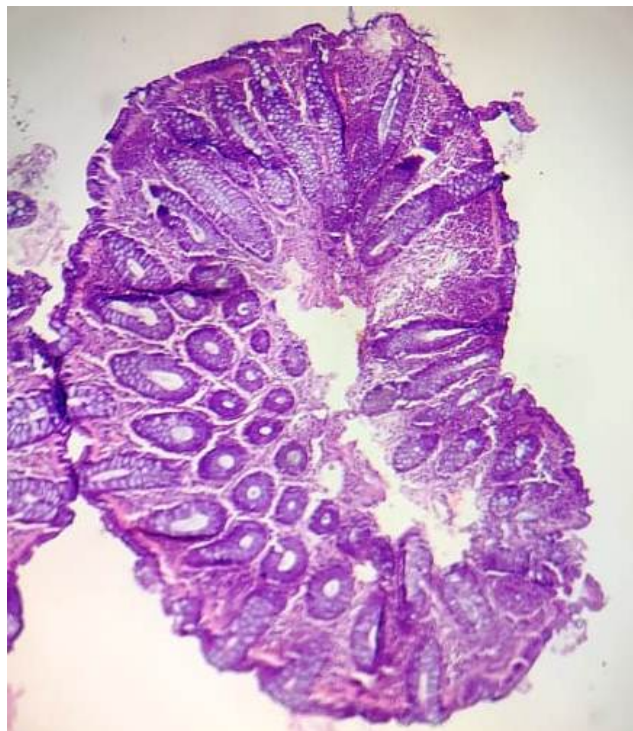

Fig. 1: Showing an adenomatous polyp with tubular architecture (H&E Stain 100X).

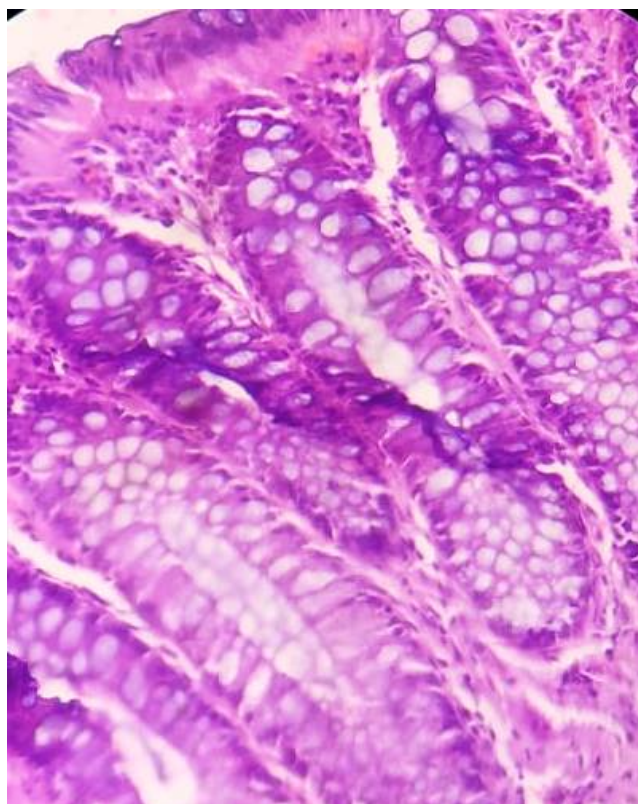


Fig. 2: Showing tubular configuration of gland with nuclear palisading and stratification with apical mucin (H&E Stain 400X).

4. Discussion

Among carcinoma in the western population, colorectal carcinoma stands fourth in the list. In India, the incidence of colorectal carcinoma is on rise, and importance of prevention and screening strategies should be focused. Colonoscopy has become most effective screening modalities because recognition and endoscopic removal of the colorectal polyp using colonoscopy can reduce the incidence of colorectal cancer by up to 90 percentage.⁸

In our study we had majority of male patient with age group of 50-59 yrs age group. This is in par with study by Rahul et al showed median age of the cases was 57.6 years which is slightly lower than in a study done by Jain M et al in which median age was 61.1 years.⁹ However other studies include studies by Kumar et al and an Amarapurkar et al showed polyp detection in mostly younger patients.^{10,11}

The majority of biopsies were of male patients 76 (66.08%) followed by 39 (33.91%) female patients. Male predominance was observed similar to Tony et al, Yousuf et al and Lee et al.¹²⁻¹⁴ Even studies conducted by Albasri A et al and Al Rashed et al from Saudi and Kuwait showed male predominance.^{15,16} but Nouraie M et al showed female predominance in their study.¹⁷

In our study most of the patient had come with clinical presentation like constipation (40.87%) followed by rectal bleeding (40.00%) followed by pain abdomen and anemia. Lorn et al study showed diarrhoea and abdominal pain as the most important causes for colonoscopy.¹⁸ In study conducted by Bafandeh Y et al showed blood in stool, change in bowel habits, and abdominal pain as most important causes for colonoscopy. Seo et al and Cheon et al both reported rectal bleeding followed by abdominal pain and diarrhoea in their study for colonoscopy.^{19,20}

Among gross features we have encountered 74.8 percentage of polyp in colonoscopy which appeared pedunculated type of polyp followed by ulcerated type (13.04%) and least were of sessile nature (12.17%). Rahul et al study showed morphologically sessile polyps were more commonly seen (77.3%) and around (22.7%) only had a stalk and were pedunculated.²¹ But Jain M et al showed only 45% of the polyps was pedunculated.⁹ Our study showed concordance with Dipika et al study which showed Out of 168 polyps, 118 polyps were pedunculated and 50 were sessile.²²

In our study most of the polyp were in descending colon (40.87%) followed by rectum (24.35%) then by ascending colon (13.91%) and sigmoid colon (8.70%) and transverse colon (6.96%) and lastly by caecum (5.22%). Albasri A et al found 36.6% of polyps in sigmoid colon, followed by 21% in rectum. In other study rectum (49.7%) was the second most commonest site followed by a sigmoid colon (15.6%) which is in concordance with the studies done by Tony et al, Wickramasinghe et al and Kumar et al.^{10,21,22} But most of the studies showed Rectum followed by sigmoid as most common site for polyp formation.

With regard to size of polyp 90.40 percentage of polyp size less than 1 cm followed by 9.60 percentage of polyp of more than 1 cm.²³ Similar study findings by Rahul et al showed that most polyps (75.8 %) were smaller in size < 1 cm, while only 6.3% polyps were > 2 cm & remaining 17.9% polyps were between 1-2 cm.²¹ Asim Qureshi et al study showed that the mean size of polyps were mostly from 0.2 cm-1. 2cm.²⁴ Also Jain M et al showed 93.3 % of the polyps were pedunculated.⁹

Among histopathological features we reported most of polyp to be tubular adenoma (53.91%) on histopathology followed by Hyperplastic polyp (15.65%) followed by tubulovillous adenoma (13.04%) then by Peutz Jegher polyp (3.48%) and least with Retention polyp (2.61%). Rahul et al and Basnet et al showed most were tubular adenoma in morphology followed by tubulovillous in nature.^{21,22} Chondulo et al and Bafandeh Y et al also showed tubular adenoma to be commonest on histology.^{12,25} The incidence of tubular adenoma reported by Beigh et al. Xianghuayiet et al and Marques et al was 46.67 %, 58.6%, and 42.6% respectively, which was close to 53.91% found in our study.²⁶⁻²⁸ While Jain et al,

Table 1: Age and Gender wise Distribution of Cases.

Age Group	Female		Male		Total	Percentage
0-9	5	12.82%	4	5.26%	9	7.83%
10-19	0	0.00%	4	5.26%	4	3.48%
20-29	2	5.13%	12	15.79%	14	12.17%
30-39	4	10.26%	8	10.53%	12	10.43%
40-49	8	20.51%	6	7.89%	14	12.17%
50-59	6	15.38%	14	18.42%	20	17.39%
60-69	10	25.64%	13	17.11%	23	20.00%
70-79	4	10.26%	12	15.79%	16	13.91%
80-90	0	0.00%	3	3.95%	3	2.61%
Total	39	100.00%	76	100.00%	115	100.00%

Table 2: Showing clinical features for which patient were subjected for Colonoscopy.

Clinical presentation	Number	Percentage
Pain Abdomen	11	9.57%
Malena	01	0.87%
Diarrhea	03	2.61%
Constipation	47	40.87%
Rectal Bleeding	46	40.00%
Routine Check Up	01	0.87%
Anemia	06	5.22%
Total Cases	115	100.00

Table 3: Showing macroscopic description of Colonic Polyp.

Endoscopic appearance	Number	Percentage
Pedunculated	83	74.78%
Sessile	14	12.17%
Ulcerated	15	13.04%
Total Cases	115	100.00

Table 4: Showing different location of Polyp in the colon.

Location of biopsy site	Number	Percentage
Caecum	06	5.22%
Descending Colon	47	40.87%
Rectum	28	24.35%
Ascending Colon	16	13.91%
Sigmoid	10	8.70%
Transverse Colon	08	6.96%

Table 5: Showing Colonic Polyp with relation to the size.

Size of the polyp	Number	Percentage
Less than 1 cm	113	90.40%
More than 1 cm	12	9.60%

Table 6: Showing different Histopathological types of Colonic polyp.

Histological types	Number	Percentage
Hyperplastic Polyp	22	19.13%
Juvenile	13	11.30%
Retention Polyp	03	2.61%
Tubular Adenoma	62	53.91%
Tubulovillous Adenoma	15	13.04%

Table 7: Showing Dysplasia with relation to number of Colonic polyp.

Dysplasia	Number	Percentage
Absent	106	94.64%
Present	06	5.36%

Albasri et al and Wickramasinghe et al studies showed that the commonest histopathological type of polyp were tubulovillous adenoma (33.5%) followed by tubular adenoma (24.5%).^{9,15,29}

Majority of cases in our study most polyp showed no dysplasia (94.64%) followed by 5.36% of polyp showing high grade dysplasia in form of nuclear stratification and broadening of nuclei. Kumar et al, Wisedopas et al and Mbakop et al also showed in their studies that non-neoplastic polyp constituted a major number of cases (83%, 50% and 87.5%) which is in concordance with our study.^{10,30,31} Our study showed low percentage of dysplasia (5.36%) which was present in equal proportion both in tubular adenoma and tubulovillous adenoma. Similar findings showed in Rahul et al study that high grade dysplasia was seen around 5.8% of polyps but were commonly seen in tubulovillous adenomas then tubular adenomas and also serrated polyps.²¹ Qureshi et al found that a higher rate of dysplasia was associated with villous (50%) and tubulovillous (62.1%) compared to tubular type (7%).²⁴ Albasri et al concluded that the polyp with villous morphology (95.7%) and tubulovillous (66.7%) structures were strongly associated with high grade dysplasia.¹⁵

5. Conclusion

Colonoscopy is the most important tool in the detection of colonic polyp. In our study most patients had clinical presentation like constipation and rectal bleeding which is most commonly seen in right and left side colorectal carcinoma. Most of the polyps were pedunculated and seen in the left side of colon (descending colon and rectum) which were seen in other previous studies. The histopathological patterns seen in our study were tubular adenoma. High grade dysplasia was rarely seen in our reported polyp cases.

6. Conflict of Interest

The authors declare no relevant conflicts of interest.

7. Source of Funding

None.

References

- Hill MJ, Morson BC, Bussey HJR. Aetiology of adenoma-carcinoma sequence in large bowel. *Lancet*. 1978;1(8058):245–7.
- Cho KR, Vogelstein B. Genetic alterations in the adenoma-carcinoma sequence. *Cancer*. 1992;70(6):1727–31.
- Leslie A, Carey FA, Pratt NR, Steele RJC. The colorectal adenoma-carcinoma sequence. *Br J Surg*. 2002;89(7):845–60.
- Rickert RR, Auerbach O, Garfinkel L, Hammond EC, Frasca JM. Adenomatous lesions of the large bowel: An autopsy survey. *Cancer*. 1979;43(5):1847–57. doi:10.1002/1097-0142(197905)43:5<1847::aid-cnrc2820430538>3.0.co;2-1.
- Paspatis GA, Papanikolaou N, Zois E, Michalodimitrakis E. Prevalence of polyps and diverticulosis of the large bowel in the Cretan population. An autopsy study. *Int J Colorectal Dis*. 2001;16(4):257–61. doi:10.1007/s003840100304.
- Makaju R, Amatya M, Sharma S, Dhakal R, Bhandari S, Shrestha S, et al. Clinico-Pathological Correlation of Colorectal Diseases by Colonoscopy and Biopsy. *Kathmandu Univ Med J*. 2017;58(2):173–8.
- Patil MV, Rathod U, Deshmukh M, Margam S, Kalgutkar AD. Spectrum of gastrointestinal polyps: A tertiary care hospital experience of five years. *Indian J Pathol Oncol*. 2018;5(4):656–62.
- Ferlay J, Soerjomataram I, Dikshit R, Eser S, Mathers C, Rebelo M, et al. Cancer incidence and mortality worldwide: sources, methods and major patterns in GLOBOCAN 2012. *Int J Cancer*. 2015;136(5):E359–86. doi:10.1002/ijc.29210.
- Jain M, Vij M, Srinivas M, Michael T, Venkataraman J. Spectrum of colonic polyps in a South Indian Urban cohort. *J Dig Endosc*. 2017;8:119–22.
- Kumar N, Anand BS, Malhotra V, Thorat VK, Misra SP, Singh SK, et al. Colonoscopic polypectomy. North Indian experience. *J Assoc Physicians India*. 1990;38(4):272–4.
- Amarapurkar AD, Nichat P, Narawane N, Amarapurkar D. Frequency of colonic adenomatous polyps in a tertiary hospital in Mumbai. *Indian J Gastroenterol*. 2016;35(4):299–304.
- Bafandeh Y, Daghestani D, Esmaili H. Demographic and anatomical survey of colorectal polyps in an Iranian population. *Asian Pac J Cancer Prev*. 2005;6(4):537–40.
- Tony J, Harish K, Ramachandran TM, Sunilkumar K, Thomas V. Profile of colonic polyps in a southern Indian population. *Indian J Gastroenterol*. 2007;26(3):127–9.
- Lee BG, Shin SH, Lee YA, Wi JH, Lee YJ, Park JH, et al. Juvenile Polyp and Colonoscopic Polypectomy in Childhood. *Pediatr Gastroenterol Hepatol Nutr*. 2012;15(4):250–5. doi:10.5223/pghn.2012.15.4.250.
- Albasri A, Yosef H, Hussainy A, Bukhari S, Alhujaily A. Profile of Colorectal Polyps: a Retrospective Study from King Fahad Hospital, Madinah, Saudi Arabia. *Asian Pac J Cancer Prev*. 2014;15(6):2669–73. doi:10.7314/apjcp.2014.15.6.2669.
- Rashed RA, Amri SA. Colonic polyps: Experience from King Khalid University Hospital. *Ann Saudi Med*. 1996;16(2):180–3.
- Nourae M, Hosseinkhah F, Brim H, Zamanifekri B, Smoot DT, Ashktorab H, et al. Clinicopathological Features of Colon Polyps from African-Americans. *Dig Dis Sci*. 2010;55(5):1442–9.
- Lorn D, Lewis J, Kochman M. Colon cancer: detection and prevention. *Gastroenterol Clin N Am*. 2002;31(2):595–86.
- Seo JK. Therapeutic colonoscopy in children: endoscopic snare polypectomy and juvenile polyps. *Seoul J Med*. 1993;34(4):285–94.
- Cheon KW, Kim JY, Kim SW. Solitary juvenile polyps and colonoscopic polypectomy in children. *J Korean Pediatr Soc*. 2003;46(3):236–41.
- Yadav R, Ganesh P, Shanmuganathan S, Koushik AK. Profile of colonic polyps in a tertiary care centre in south India. *Int J Adv Res*. 2019;7(10):1238–42. doi:10.21474/IJAR01/9948.
- Basnet D, Makaju R, Gurung RB, Dhakal R. Colorectal Polyps: A Histopathological Study in Tertiary Care Center. *Nepalese Med J*. 2021;4(1):414–8.

23. Lee BG, Shin SH, Lee YA, Wi JH, Lee YJ, Park JH, et al. Juvenile polyp and colonoscopic polypectomy in childhood. *Pediatr Gastroenterol Hepatol Nutr.* 2012;15(4):250–5.
24. Qureshi ASA, Shihi AZ, Shalaby A. A retrospective study of clinicopathological characteristics of colonic polyps in adults seen at a tertiary care centre. *J Pak Med Assoc.* 2017;67(1):12–4.
25. Chandolu PK, Venkatakrishnan L, Vidhyalakshmi S. Clinicopathological profile of colorectal polyps: retrospective analysis from tertiary care center in Southern India. *Int J Res Med Sci.* 2019;7(9):3396–401.
26. Beigh A. Spectrum of colorectal lesions on colonoscopic biopsies: a histopathological study in a Tertiary care hospital. *Int J Med Sci Clin Interv.* 2017;4(3):2750–8.
27. Xianghua et al ; histological subtypes and polyp size are associated with synchronous colorectal carcinoma of colorectal serrated polyps :a study of 499 serrated polyps. *Am J cancer Res.* 2015;5(1):363–74.
28. Mirzaie AZ, Maryam A, Roozbeh MM, Maryam K. The frequency of gastrointestinal polyps in Iranian population. *Iran J Pathol.* 2012;7(3):183–9.
29. Wickramasinghe DP, Samaranyaka S, Lakmal C, Mathotaarachchi S, Lal CK, Keppetiyagama C, et al. Types and patterns of colonic polyps encountered at a tertiary care center in a developing country in South Asia. *Anal Cell Pathol (Amst).* 2014;p. 248142. doi:10.1155/2014/248142.
30. Wisedopas N, Thirabanjasak D, Taweewisit M. A retrospective study of colonic polyps in King Chulalongkorn Memorial Hospital. *J Med Assoc Thai.* 2005;88(4):36–41.
31. Mbakop A, Ndam EN, Pouaha J, Sosso M, Tzeuton C, Biwole SM, et al. [Anatomopathological aspects of colorectal polyps in Cameroon]. *Arch Anat Cytol Pathol.* 1991;39(4):158–61.

Author biography

Amar Kumar, Tutor

Swati Sucharita Giri, Tutor

Sneha Singh, Senior Scientific Officer

Cite this article: Kumar A, Giri SS, Singh S. Study of clinico-pathological characteristics of colonic polyp seen at a tertiary care hospital in East India. *IP J Diagn Pathol Oncol* 2022;7(2):89-94.