

Content available at: <https://www.ipinnovative.com/open-access-journals>

IP International Journal of Ocular Oncology and Oculoplasty

Journal homepage: <https://ijooo.org/>

## Review Article

# Animal induced ocular injuries: A brief review

Rajendra Prakash Maurya<sup>1,\*</sup>, Vibha Singh<sup>1</sup>, Shankar Narayan A<sup>1</sup>, Shivangi Singh<sup>2</sup>,  
Syeed Mehbub Ul Kadir<sup>3</sup>, Kartika Anand<sup>4</sup>, Virendra P Singh<sup>1</sup>

<sup>1</sup>Regional Institute of Ophthalmology, Institute of Medical Sciences, Banaras Hindu University, Varanasi, Uttar Pradesh, India

<sup>2</sup>Motilal Nehru Medical College, Prayagraj, Uttar Pradesh, India

<sup>3</sup>Sheikh Fazilatunnesa Mujib Eye Hospital and Training Institute, Gopalganj, Dhaka, Bangladesh

<sup>4</sup>Dept. of Ophthalmology, Rohilkhand Medical College and Hospital, Bareilly, Uttar Pradesh, India



## ARTICLE INFO

### Article history:

Received 10-01-2022

Accepted 25-01-2022

Available online 07-02-2022

### Keywords:

Ocular injury

Animal

Cow

Bull horn

Dog bite

Cat scratch

Globe rupture

## ABSTRACT

Eye injuries constitute a significant cause of avoidable global blindness. Animal-related injuries are an increasing public health issue worldwide. The interaction of a man with animals occurs in various situations, and the danger associated with it are underestimated and also there are underreported wounds. Animal-induced ocular injuries are often severe and may lead to visual impairment, blindness and cosmetic disfigurement. Animal-related ocular injuries are classified according to the geographical distribution, type of animal, its behavior and availability in the community. This article reviews current literature and discusses the mechanism and severity of animal inflicted ocular and adnexal injuries in humans and various management techniques.

This is an Open Access (OA) journal, and articles are distributed under the terms of the [Creative Commons Attribution-NonCommercial-ShareAlike 4.0 License](https://creativecommons.org/licenses/by-nc-sa/4.0/), which allows others to remix, tweak, and build upon the work non-commercially, as long as appropriate credit is given and the new creations are licensed under the identical terms.

For reprints contact: [reprint@ipinnovative.com](mailto:reprint@ipinnovative.com)

## 1. Introduction

Eye injury is the leading cause of mono-ocular visual disability and blindness.<sup>1,2</sup> Most ocular injuries occur in developing countries.<sup>3</sup> Literature reported that young children are more vulnerable to ocular trauma.<sup>4</sup> Eye is one of the most important organs affected as a consequence of animal attack. Animal-related injuries (ARI) differ according to animal type, their availability in the community, and their activity with humans. For example, cattle and dogs are the most common domestic animal worldwide, especially in India and hence is the most common cause of ARI in India. Especially an injury by a bull or cow is more common in rural India.<sup>5</sup> Similarly Camel related ocular injuries are more common in Saudi Arabia where it is the most commonly raised domestic

animal. Camel bite comprises 77% of all animal-related injuries there.<sup>6</sup>

Similarly, children are most commonly encountered with dog bites. Children being naturally curious about the environment around them may interact with animals more frequently and unknowingly. An American study found that approximately 50% of children suffer a dog bite during their childhood.<sup>7</sup> Most of the time, animal-related ocular injuries are complex and grievous type. Bilateral ocular trauma due to animal attacks has been reported.<sup>8,9</sup>

## 2. Domestic Animal Induced Ocular Trauma

Domestic animals can cause accidental ocular trauma like dogs, cats, cattle, camel, etc.

\* Corresponding author.

E-mail address: [mauryarp\\_bhu@yahoo.com](mailto:mauryarp_bhu@yahoo.com) (R. P. Maurya).

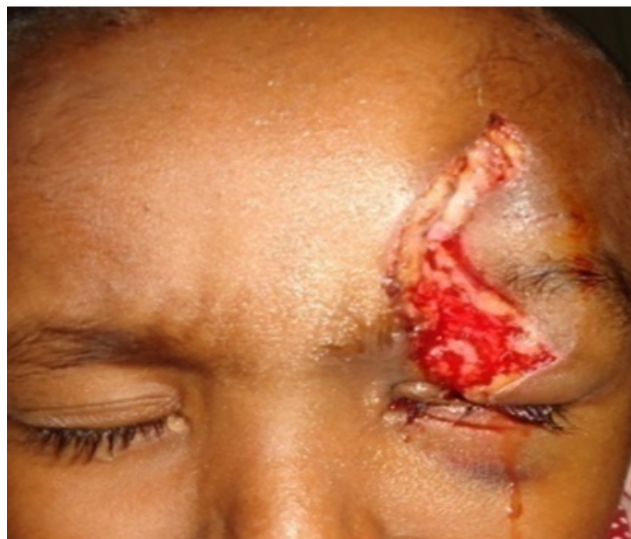### 2.1. Dog bite-related ocular injuries

The potential source of animal-related injuries in humans are dogs, and they are also common household pet. Since the number of people who adopting dogs have increased, there have been increase in the number of dog bite cases over the past two decades. In the United States, nearly 50 % of the household contains at least one dog.<sup>10</sup> There is a risk of polymicrobial infection and transmission of rabies due to dog inflicted injuries.

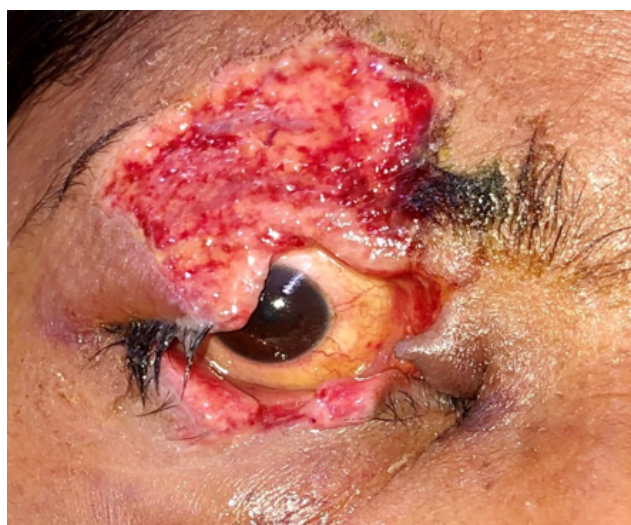Dog bites causes an approximately 4.5 million human injuries in the United States yearly.<sup>11,12</sup> The dog owners or persons familiar with the dog are victims of dog bites in most cases (72%-94%).<sup>13-15</sup> There have been reports suggesting that most dog bite-related ocular injuries occur in unprovoked circumstances.<sup>16,17</sup> However, Reisner reported that 77% of dog injuries occur in provoked situations.<sup>18</sup> Young children are more vulnerable to dog bites than adults.<sup>13,17</sup> Young children usually sustain dog inflicted wounds in an indoor setting with a familiar dog after self-initiated interaction with the dog. At the same time, adults and teenagers are more likely to be attacked in the outer environment by an unfamiliar dog without voluntary interaction.<sup>10,18</sup>

The most common dog breed responsible for fatal bite and ocular injuries<sup>17</sup> is Pitbull's, as they are among one of the highly aggressive dog breeds.<sup>19,20</sup> Other aggressive dog breeds causing injuries are German shepherds, Doberman pinchverus, Bulldogs, Huskies and Akitas etc.<sup>14,15,21</sup> In young children, dogs prefer the oculo-facial area such as eyelids, globe, lips, nose and cheek, head and neck for biting.<sup>14,15,21</sup> In contrary, teenagers and adults have dog bite injuries in extremities.<sup>22</sup> This difference is due to unique features of young children such as large head, underdeveloped motor skills, lack of fearfulness and poor judgement capability make them more vulnerable to oculo-facial injuries.<sup>17,23</sup> The mechanism of tissue damage from dog inflicted injuries include abrasion, laceration, puncture wound, avulsion and crush injuries.(Figures 1, 2 and 3)<sup>22-24</sup> Eppley found that 90% of dog bite injuries are combination of both laceration and crush elements.<sup>23</sup> About 4-20% of dog bite injuries involve the eye and periocular area.<sup>9,25</sup> Typical dog inflicted ocular injuries are eyelid and periocular laceration with involvement of canaliculi, levator aponeurosis, lacrimal gland.<sup>11,26,27</sup> High incidence of dog bite related canicular injury has been reported in children.<sup>17,25,28</sup> Dog bites resulting in orbital fractures and globe injury are pretty uncommon. Injury caused by large breed dog may lead to orbito-facial fracture.<sup>22,29</sup> Recent studies reported that facial fractures are present in 1.5% of dog bite cases.<sup>17,26</sup> Open globe injuries after a dog bite are infrequent due to the protection of the globe by blink reflex. Hobat-Wilner and Manchester M reported cases of corneoscleral perforation by upper canine teeth.<sup>21,30</sup>

The Management of dog bite wounds includes an aggressive saline lavage with debridement of devitalized tissue, along with tetanus and antibiotic prophylaxis. Passive immunization with rabies immunoglobulin is also recommended along with proper meticulous wound repair. For preventing dog bite injuries, children should not be left unsupervised around a dog.



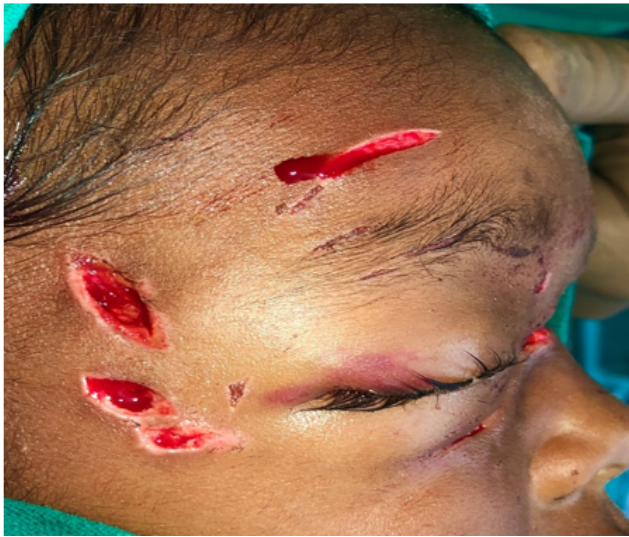**Fig. 1:** Photograph of young child having dog bite injury showing large lacerated wound involving left upper eyelid, eyebrow and forehead.



**Fig. 2:** Dog bite related severe laceration of both eyelid of right eye.

### 2.2. Cat induced ocular injuries

Domestic cats are common household pet worldwide. Cat related human injuries are mainly caused by claw or teeth.



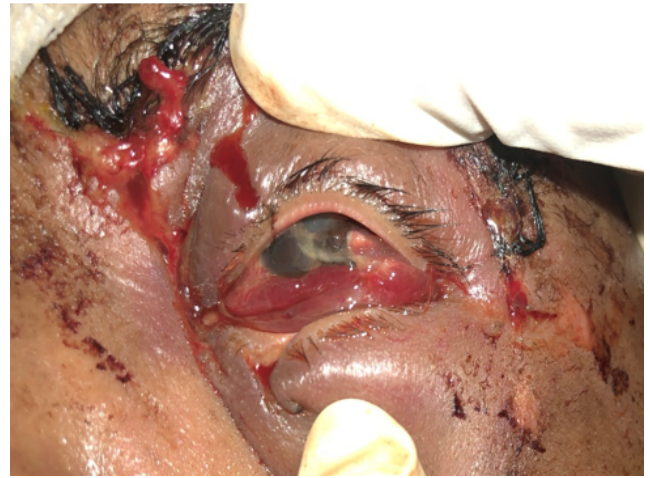**Fig. 3:** Photograph of young boy having dog bite injury showing multiple oculo-facial laceration & puncture wound

Cat scratch inflicted ocular injuries are relatively rare, and published case reports are scanty. Cariello et al. reported that 0.4% of ocular injury victims attending the emergency department were due to cat bites and cat scratches.<sup>31</sup> Young children are prone to cat scratch inflicted injury.(Figure 4) Several cases of cat-scratch-inflicted corneal laceration have been reported from USA 32-34 and France.<sup>32</sup> Cat inflicted open globe injury in children ranged from 1.2%<sup>33</sup> to 2.5%.<sup>34</sup> Cat induced full-thickness corneal laceration has been reported by Chang and Peiris et al.<sup>35,36</sup> Two cases of scleral perforation with eyelid laceration without corneal laceration due to cat bite has been reported.<sup>37,38</sup>

The poor prognostic factors in cases of cat inflicted ocular injuries are necrotic wound edges, secondary microbial keratitis, associated hypopyon and posterior segment involvement<sup>39</sup>. *Pasteurella multocida*, a gram-negative coccobacillus, is the commonest infective microorganism associated with animal inflicted wounds. Among them, 60-80% were cat scratch wounds.<sup>39,40</sup> An extensive literature search yielded two case of two cases of *Pasteurella keratitis*, one case of a corneal abscess, and one case of *Pasteurella multocida* endophthalmitis after cat-inflicted injury has been reported.<sup>32,38,41,42</sup> Hence, antimicrobials like penicillin, ampicillin, piperacillin and fluoroquinolones should be administered to protect against secondary microbial infection and permanent vision loss. In addition to antibiotic, tetanus and rabies prophylaxis are routinely recommended in all animal inflicted wounds.

### 2.3. Cattle induced ocular injuries

Cattle and bulls are commonly domesticated animals worldwide. Since ox, cow, and buffalo are docile compared to the bull hence bull can easily be raged. Humans can



**Fig. 4:** Photograph showing left eye multiple laceration of lower eyelid and periocular area with globe rupture due to cat claw injury.

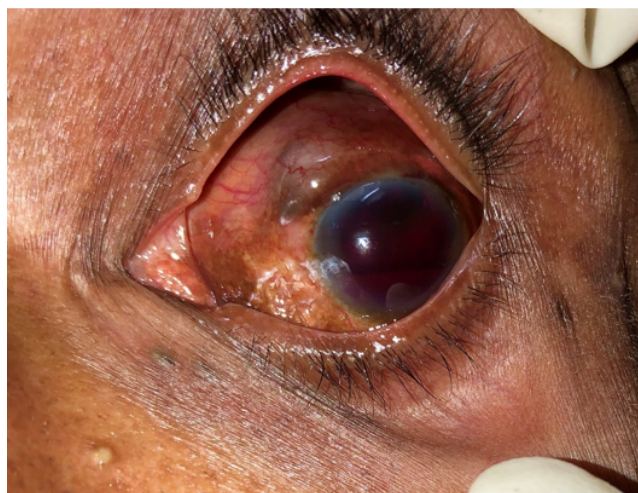
suffer from cattle induced injury either accidentally or due to intentional attack. Eye injuries could be caused by cattle's horns, hoof and tail.(Figures 5, 6 and 7 ) Victims of cow-related injury are usually cow rearers, butchers, dairy farmers and dealers who sell the animals.<sup>43,44</sup>

Bulls are used in a rural area for forming work in agriculture dependent countries. Bull sports or bullfighting events are common in western countries like Spain, Portugal, France, the United Kingdom, etc. in India, "Jallikattu", is a popular sporting event in the Tamil Nadu state during the Pongal festival where participants attempt to stop running bulls.<sup>45</sup> The Bull may become harmful and aggressive at any time for no apparent reason.<sup>46</sup> Bull attack may result in either blunt trauma or penetrating trauma by the horn (bull gore injury). Another way of bull induced trauma could be head butting, direct contact by the body of a bull, throwing on the ground, and bull trampling.<sup>47</sup> Victims of a bull induced ocular injury are usually elderly males, and the reported mean age is 49.3 years.<sup>48</sup>

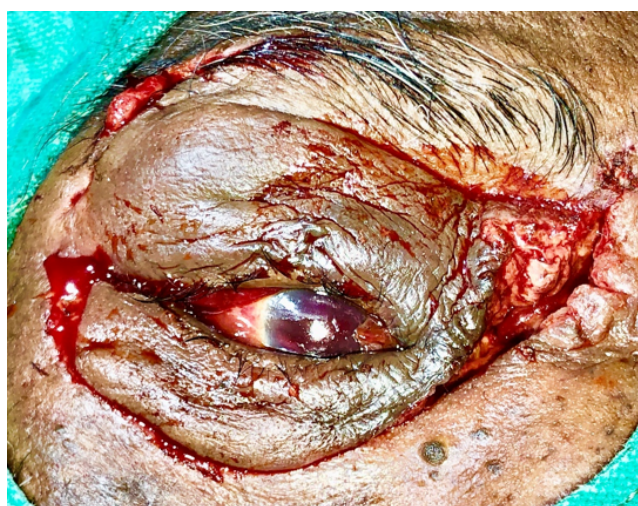Cow horn injury may cause periorbital injury, abdominal injury, anorectal injuries and vulvovaginal damage.<sup>49-51</sup> Cow horn ocular injuries are usually severe and result in monocular blindness.

A study conducted in Switzerland found that 3.1% of all hospitalized ocular trauma cases were due to cow horn injury.<sup>43</sup> Cow horns are usually pointed but not sharp; their forceful impact could lead to severe corneoscleral laceration or globe rupture.<sup>52</sup> Helbig et al. reported that of all open globe injuries, 5% were caused by cow horn attack.<sup>44</sup> Maurya et al. reported a rare case of subconjunctival dislocation of fractured posterior chamber intraocular lens caused by cow horn injury.<sup>50</sup> Scleral rupture with phacocele due to cow horn injury has also been reported.<sup>51</sup> The most common site of indirect scleral rupture is superonasal quadrant,<sup>53</sup> followed by superotemporal quadrant<sup>50</sup> which

is supported by the anatomy of orbit and mechanism of cow horn injury.



**Fig. 5:** Cow horn injury causing occult supero-nasal scleral rupture with hyphaema left eye.

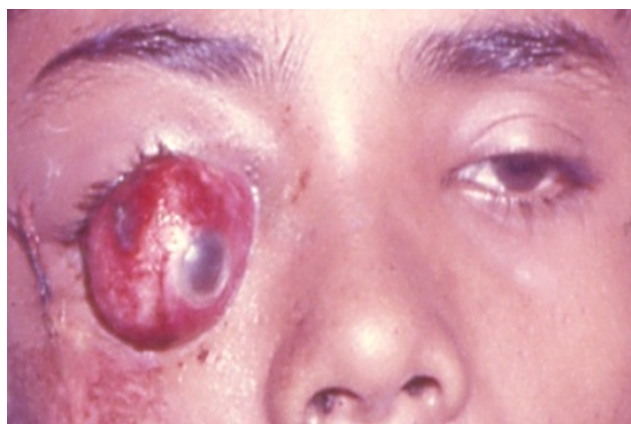

**Fig. 6:** Cow hoof injury causing right eye periocular laceration with closed globe injury.

#### 2.4. Camel related ocular injuries

Camels are domestic animals commonly seen in Asia, Africa, and Arabian countries and are an important source of milk, food, transport, and racing competitions.<sup>54</sup> Camels are considered quiet and obedient animals, but male camels become irritable, highly unpredictable, and aggressive in the rutting season from December till March. The people close to camels and their caregivers are more vulnerable to camel related injuries (CRI).

Camel related human injuries are quite rare. The majority of animal related injuries in Arabian countries are due



**Fig. 7:** Avulsion of the right globe due to Cow horn injury

to camel bite.<sup>55</sup> Camel bites might result in serious life-threatening injuries, including head injury, cervical injury, neurovascular injuries and maxillofacial fractures.<sup>56,57</sup> Camel bite can cause serious puncture/penetrating wounds, deep lacerations and crushing injuries. This complex nature of camel bite injury is due to its unique dentition and strong jaw which exerts high pressure leading to serious injuries.

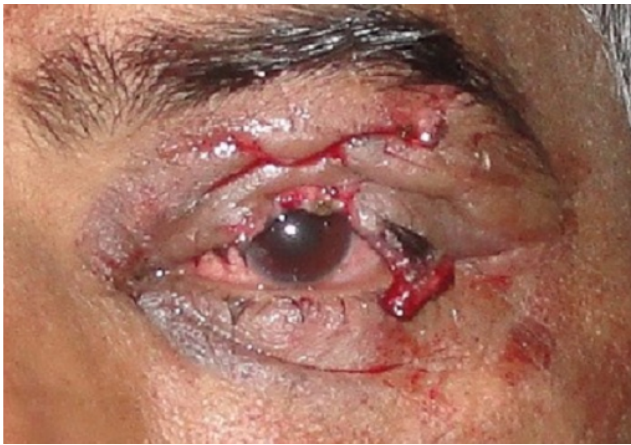A mature camel has 34 teeth including four very sharp and long canines responsible for a puncture wound and deep laceration and six incisor teeth of the lower jaw lead to large cut wounds.

Several camel related ocular injuries have been reported in the literature. Albazei AI reported a ruptured globe with eyelid laceration due to CRI, which was managed surgically with the final visual outcome to the perception of light.<sup>58</sup> However, Bolack K et al. reported a case of camel bite resulting in severe oculofacial injury where a patient had extensive corneal laceration with the expulsion of intraocular content.<sup>54</sup> They were not able to salvage the globe, and thus evisceration was performed.

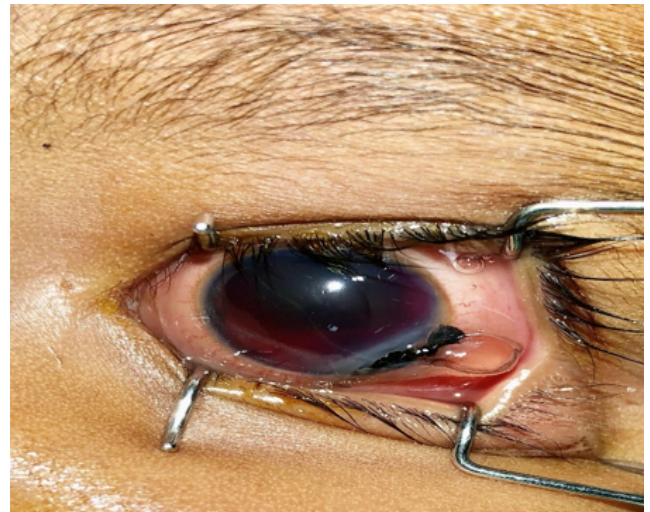That's why camel caregivers need to be educated about the risk of camel bite, and extreme care should be taken while dealing with male camels especially during the breeding season.

### 3. Non-Domestic Animal Induced Ocular Trauma

Non-domestic animals causing ocular injuries include birds, bears, monkeys, jackals, fox, snakes, insects, etc.(Figure 8) The ocular injuries sustained by the victims varied from adnexal injury to open globe injury, lid laceration and is also complicated with retained intraocular foreign body, rabies infection, phthisis bulbi. Some patients also required evisceration of the involved eye. Most of the time, the visual outcome was poor.



**Fig. 8:** Monkey bite causing left upper eyelid laceration involving lid margin



**Fig. 9:** Bird (crow) pecking injury in young boy showing corneal laceration with prolapse of uveal tissue and vitreous.

### 3.1. Ocular injury due to bird attack

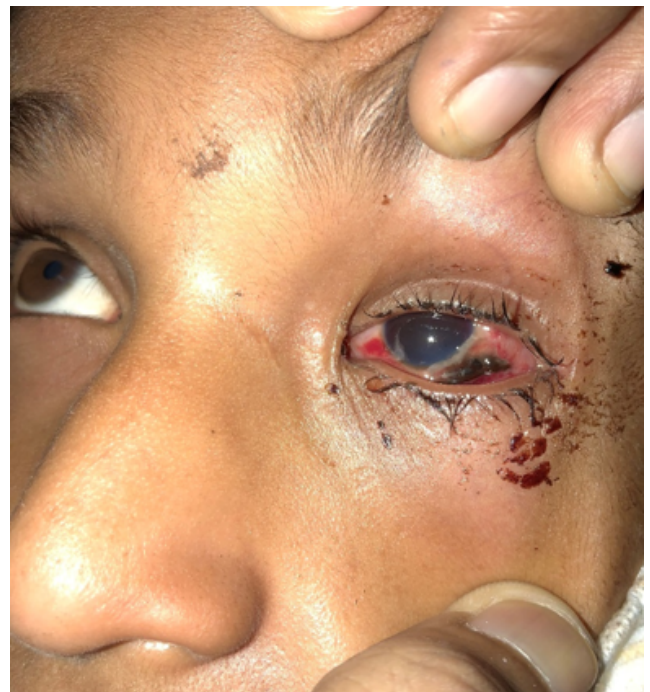Ocular injuries caused by bird are extremely uncommon, with very few cases reported in the literature. Common birds responsible for human injury are hens, eagles, owls, roosters, bats, ostriches, mynah, magpies, sparrows etc.<sup>59–67</sup> Most of the birds use their beaks and claws as attacking weapons.<sup>59,68</sup> Young children are at higher risk of bird's attack with or without provocation due to the curiosity of children to explore the living creature.<sup>61</sup> Birds are rarely dangerous to a human being, they attack mainly in the breeding season and show quite aggressive behavior during that time to safeguard their young.<sup>59,64,69</sup> The most vulnerable site of the attack is face and eyes. The literature reported that iris color, shiny cornea, and eyeball movements attract birds for attacking.<sup>60,70</sup>

Although ocular injuries due to the pecking of birds are uncommon but sometimes could lead to severe visual impairment.<sup>59,67,71,72</sup> Bird peck can damage cornea, sclera, lens, and zonules.(Figures 9 and 10)

Visual prognosis of bird attacks related to ocular injury depends on the extent /zone of globe injury and associated post-traumatic complications. Injury caused by birds with small or straight beaks (e.g. sparrow) results in small corneal perforation,<sup>72</sup> while birds with large beaks such as *Ardea alba* (Egret) would lead to severe open globe injury/globe rupture.<sup>73</sup> Lens capsule rupture may lead to traumatic cataract.<sup>74</sup>

Several post-traumatic complications of bird pecking open globe injuries had been reported in the literature, such as retinal detachment, traumatic aniridia, post-traumatic endophthalmitis and phthisis bulbi.<sup>59,65,75</sup> Ono T et al. reported a rare case of panophthalmitis caused by *E Coli* infection after pecking by *A. alba*.<sup>73</sup> Tobatabaei SA et al. reported endophthalmitis in 10% of patients having penetrating globe injury caused by bird pecking.<sup>76</sup>

Many authors recommended early surgical repair with broad-spectrum topical and intravitreal antibiotics in high-risk patients after bird attack injuries.<sup>59,75</sup>



**Fig. 10:** Young boy having scleral tear due to attack by hen peck.

### 3.2. Ocular injury due to bear mauls

Injuries due to bear mauling are infrequently reported in the literature. Bear attacks are common on the upper extremity, but a high percentage are on the oculo-facial

area and head.<sup>77</sup> Table-1 showed pattern of bear maul injury after review of 252 cases reported in various articles from India and Nepal due.<sup>77-82</sup> Bear mauling wound commonly involved the face (81-96%) and head (54.7%). Wounds by claws, paws and a combination of both due to bear attacks can present in extensive sharp and blunt injuries and may associate with underlying bone fractures. Most patients are young and middle-aged (96%) because of their outdoor work near the forest, hunting wild animals, hikers and campers in the mountain. Male (73-96%) is common victim.<sup>78-80</sup> Most injuries (92.5%) occur due to sudden encounters followed by 7% provoked and 0.5% predatory encounters.<sup>79</sup> The facial bones (e.g. zygoma) (27%) are commonly involved, followed by the frontal bone of the skull (6%).<sup>78,79</sup> Oculofacial injuries include forehead (19%), Eyelid (31%), Globe (13%), Nose (27%), cheek (38%), lower face 934%), and ear (11.5%). The reported ruptured globe is in 9.6% of cases,<sup>78</sup> and the avulsion of the globe is in 1.9% of cases.<sup>79,83</sup> Injuries involving soft tissue injuries (100%) like punctures lacerations with or without actual tissue loss is usually associated with bone fractures (19%) and visceral (27%) injuries (e.g. brain, eye)<sup>79,83,84</sup> The treatment plan includes repairing the extensive soft-tissue defects (deep laceration) according to the criteria of esthetic reconstructive surgery, reconstructing the bone fractures, and preventing the post-treatment infections. Life-threatening injuries are promptly requiring resuscitative measures. Patients should evaluate for the oculofacial area, head, chest, abdomen, or skeletal injuries. According to the WHO regimen, rabies vaccination should give all bear attacks injuries. A single dose of tetanus toxoid may be given depending on the immune status of the patient.<sup>77,78,81,82</sup> Wounds due to large animal bites are considered to be dirty or contaminated. Surgical toileting and debridement are an essential part of the treatment.<sup>77-79</sup> The Management of bear mauling injury often require a multidisciplinary approach and may need multi-staged secondary surgery to treat the secondary defects. Postoperative infections, wound defect, graft loss, blindness, eyelid deformity, facial disfigurement are common complications.

### 3.3. Ocular injury due to insect

Although insect bite injury is a rare occurrence, caused mainly by hymenopteran insects can result in significant ocular alterations in humans.<sup>85</sup> Hymenoptera is an order of insects consisting of bees, wasps, sawflies, and ants.<sup>86</sup> Stings of the insect cause tissue oedema and inflammation due to toxic effects and tissue injury. The usual ocular features comprise toxic keratopathy, corneal oedema, corneal decompression, conjunctival hyperaemia,<sup>87</sup> anterior uveitis, optic neuritis, toxic scleritis, endophthalmitis, glaucoma, cataract, and eyelid swelling with inflammation.<sup>86,88,89</sup> In a study of 5 cases

**Table 1:** Distribution of the demographic profile and involved body parts of the injured patients due to bear attacks

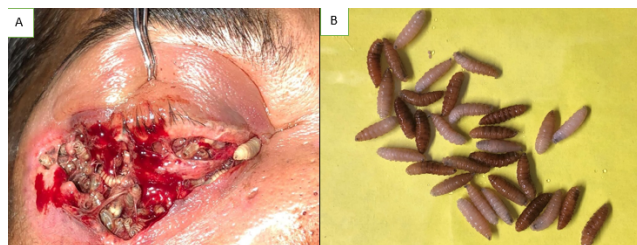
Parameter	No	%
<b>Age groups :</b>		
≤30 years	38	15%
31-60 years	199	79%
>60 years	19	7.5%
<b>Gender:</b>		
Male	198	78.5%
Female	54	21.5%
<b>Involving body parts:</b>		
Face	201	79.7%
Head	124	49%
Upper Extremity	51	20%
Lower Extremity	32	12.7%
Others (Chest, Abdomen)	23	9%

of ocular injury due to bee stings, significant corneal oedema was reported, which resolved spontaneously in three patients after removal of stingers; among the other two, one presented for permanent corneal decompensation and the other developed early cataract with raised intraocular pressure.<sup>89</sup> The management includes conservative treatment to eliminate allergic reactions, inflammation, and infections. Topical Antibiotics, topical steroid, and topical cycloplegic often need to prevent the possibility of permanent corneal damage and intraocular complications.<sup>89,90</sup> The systemic steroid is recommended to treat severe allergic reactions and anaphylaxis. Oral antihistamine is not routinely mentioned in the literature.<sup>90</sup>

The insect delivers their venom by stinging their victims.<sup>88</sup> Massive envenomation can cause death due to immediate hypersensitivity reactions, causing anaphylaxis. The estimated lethal dose is nearly 20 stings/kg in most mammals.<sup>91</sup> Urgent consultation with an Ophthalmologist is essential to manage insect bite patients. The removal of bee or wasp stingers is controversial. 90% of a bee's venom is delivered within the first 30 seconds after the sting. Ideally, the insect stinger should be removed at a slit lamp or under an operating microscope, making sure to extract all parts of the stinger. Wasp stings may have a worse prognosis than others sting for ocular alterations.<sup>90,92</sup> Definitive surgery may require depending on the ophthalmic feature after removal of stings.

Ophthalmomyiasis is a rare occurrence, caused by infestation of ocular and orbital tissues with larvae (maggots) of dipterous fly. The condition is more frequent in warm and humid climates of tropical and subtropical countries. Ophthalmomyiasis may involve eyelid, conjunctiva & superficial periocular tissues (ophthalmomyiasis externa) and orbit / eyeball (ophthalmomyiasis interna). Common predisposing factors are poor personal hygien, lack of self care and neglected fungating & necrotic wound of ocular trauma

and malignancy.<sup>93,94</sup> In orbital myiasis invasion of large number of larvae rapidly destroy orbital tissue. Maurya et al reported a rare case of orbital myiasis caused by invasion of larvae of flesh fly in young child having neglected eyelid trauma. (Figure 11)<sup>95</sup> Farahavash reported a case of bilateral subretinal ophthalmomyiasis in 70 year females.<sup>96</sup> Mechanical removal of maggots after immobilizing them, regular dressing & wound debridement and systemic antibiotics are the main treatment of ophthalmomyiasis. Oral ivermectin administration minimizes the inflammation and excessive surgical debridement.



**Fig. 11: A:** photograph of a case of Orbital myiasis in adult male having right lower eyelid laceration due to fall after alcohol intoxication showing multiple maggots crawling in crater of lacerated wound; **B:** multiple maggots after mechanical removal.

### 3.4. Reptiles induced ocular trauma

Out of the three case reports concerning with reptile-induced ocular trauma, all three were snake induced, with two involving viper bites to medial canthus<sup>97</sup> and eyelid,<sup>98</sup> and one diamond rattlesnake venom exposure.<sup>99</sup> The Visual outcome is usually good if there is no envenomation and is usually associated with full recovery in venom exposure cases.

## 4. Conclusion

The ocular injuries caused by animals varies among the age group of presentation, geographical area of presentation, and even relates to interaction with the animals. There are obvious association with geographical area. For example, magpie related injuries are more common in Australia because magpie is more commonly found in Australia; similarly, camel induced ocular trauma is most common in Saudi Arab, where camels are in abundance. The paediatric age group is more commonly affected than adult populations, and the person in constant interaction with the animals are also involved.

## 5. Conflict of Interest

The authors have stated explicitly that there are no conflicts of interest in connection with this article.

## 6. Source of Funding

None.

## References

- Norbder E. Injuries as a public health problem in sub Saharan Africa: epidemiology and prospects for control. *East Afr Med J.* 2000;77(1):1–43.
- Maurya RP, Srivastava T, Singh VP, Al-Mujaini A, Mishra CP. The epidemiology of ocular trauma in Northern India: A teaching hospital study. *Oman J Ophthalmol.* 2019;12(2):78–83.
- Strahman E, Elman M, Daub E, Baker S. Causes of paediatric eye injuries. A population based study. *Arch Ophthalmol.* 1990;108(4):603–6. doi:10.1001/archoph.1990.01070060151066.
- Maurya RP, Singh VP, Yadav I, Singh MK, Mishra CP, Sen PR, et al. Profile of paediatric ocular trauma at a tertiary eye care centre in Northern India. *Indian J Clin Exp Ophthalmol.* 2015;1(2):76–83.
- Singh H, Mahant TS, Narula IM, Dhaliwal RS, Suri RK, Gujral JS, et al. Cattle horn injuries. *Aust N Z J Surg.* 1980;50(6):620–1.
- Janjua KJ, van den Berg AA. Animal injuries presenting to Riyadh Armed Forces Hospital: a survey. *Trop Doct.* 1994;24(2):84. doi:10.1177/004947559402400220.
- Yardley AM, Hoskin AK, Hanman K. Animal-inflicted ocular and adnexal injuries in children: a systematic review. *Surv Ophthalmol.* 2015;60(6):536–46. doi:10.1016/j.survophthal.2015.05.003.
- Maurya RP, Singh VP, Ul-Kadir SM, Das JK, Bosak S, Prajapat MK, et al. The study of simultaneous bilateral ocular trauma in Northern India: clinical presentation, epidemiology and patterns of injury. *Int Ophthalmol.* 2021;doi:10.1007/s10792-021-02104-5.
- Muen WJ, Bal AM, Wheelan S, Green F. Bilateral endophthalmitis due to dog bite. *Ophthalmology.* 2009;116(7):1420–1. doi:10.1016/j.ophtha.2009.02.016.
- Erickson BP, Feng PW, Liao SD, Modi YS, Ko AC, Lee WW, et al. Dog bite injuries of the eye and ocular adnexa. *Orbit.* 2019;38(1):43–50. doi:10.1080/01676830.2018.1470190.
- Weiss HB, Friedman DI, Coben JH. Incidence of dog bite injuries treated in emergency departments. *JAMA.* 1998;279(1):51–4. doi:10.1001/jama.279.1.51.
- Gilchrist J, Sacks JJ, White D. Dog bites: still a problem? *Inj Prev.* 2008;14(5):296–301. doi:10.1136/ip.2007.016220.
- Chen HH, Neumeier AT, Davies BW, Durairaj VD. Analysis of pediatric facial dog bites. *Craniofacial Trauma Reconstr.* 2013;6(4):225–32. doi:10.1055/s-0033-1349211.
- Schalamon J, Ainoedhofer H, Singer G. Analysis of dog bites in children who are younger than 17 years. *Paediatrics.* 2006;117(3):374–9.
- Lang ME, Klassen T. Dog bite in Canadian children: a five-year review of severity and emergency department management. *Can J Emerg Med.* 2005;7(5):309–14.
- Herman DC, Bartley GB, Walker RC. The treatment of animal bite injuries of the eye and ocular adnexa. *Ophthalmic Plast Reconstr Surg.* 1987;3(4):237–41.
- Prendes MA, Jian-Amadi A, Chang S, Shafel S. Ocular trauma from dog bites: Characterization, association and treatment patterns at a Regional Level I Trauma Center over 11 years. *Ophthalm Plast Reconstr Surg.* 2015;20(20):1–5.
- Reisner IR, Nance ML, Zeller JS, Houseknecht EM, Kassam-Adams N, Weibe DJ. Behavioural characteristics associated with dog bites to children presenting to an urban trauma centre. *Inj Prev.* 2011;17(5):348–53.
- Sacks JJ, Lockwood R, Hornreich J. Fatal dog attacks, 1989–1994. *Paediatrics.* 1996;97(6 Pt 1):891–5.
- Sacks JJ, Satin RW, Bonzo SE. Dog bite related fatalities from 1979 through 1988. *JAMA.* 1989;262(11):1489–92. doi:10.1001/jama.262.11.1489.
- Manchester M. Perforating eye injuries caused by dog bites acute Guillai-barrie syndrome. *J R Soc Med.* 1990;83(Med):332–4.
- Srefenopoulos PK, Tarantzopoulou AD. Facial bite wounds: management update. *Int J Oral Maxillofac Surg.* 2005;34(5):464–72.

23. Eppley BL, Schleich AR. Facial dog bite injuries in children: treatment and outcome assessment. *J Craniofac Surg.* 2013;24(2):384–6.
24. Slonim CB. Dog note-induced canalicular lacerations: a review of 17 cases. *Ophthalm Plast Reconstr Surg.* 1996;12(3):218–22.
25. Gonnering RS. Ocular adnexal injuries and complications in orbital dog bites. *Ophthalm Plast Reconstr Surg.* 1987;3(4):231–5.
26. Wei LA, Chen HH, Hink EM. Paediatric facial fractures from dog bite injuries. *Ophthalm Plast Reconstr Surg.* 2013;29(3):179–82. doi:10.1097/IOP.0b013e3182880114.
27. Bergmann J, Lee K, Klein R, Slonim CB. Upper face and orbit “Degloving” dog bite injury. *Ophthalmic Plast Reconstr Surg.* 2009;25(1):44–46.
28. Burroughs JR, Soparkar CNS, Patrinely JR, Williams PD, Holck DEE. Periocular dog bite injuries and responsible care. *Ophthalm Plast Reconstr Surg.* 2002;18(6):416–9.
29. Tu AH, Giroto JA, Singh N. Facial fractures from dog bite injuries. *Plast Reconstr Surg.* 2002;109(4):1259–65.
30. Habot-Wilner Z, Desatnik H, Greenbaum A, Barequent IS. An intraocular injury from a dog bite. *Isr Med Assoc J.* 2006;8(1):67–8.
31. Cariello AJ, Moraes NS, Mitne S, Oita CS, Fontes BM, Melo LA. Epidemiological findings of ocular trauma in childhood. *Arq Bras Oftalmol.* 2007;70(2):271–5.
32. Algan M, George JL, Lion C. Corneal abscess caused by Pasteurella following cat scratch injury. *Bull Soc Ophthalmol Fr.* 1989;89(4):581–4.
33. Tok O, Tok L, Ozkaya D. Epidemiological characteristics and visual outcome after open globe injuries in children. *J AAPOS.* 2011;15(6):556–61.
34. Thompson CG, Kumar N, Billson FA, Martin F. The aetiology of perforating ocular injuries in children. *Br J Ophthalmol.* 2002;86(8):920–2.
35. Chang JH, Mills RA, Pater J, Crompton JL. Case series of cat-scratch-inflicted full-thickness corneal laceration and a review of the literature. *Clin Experiment Ophthalmol.* 2012;40(7):669–74.
36. Peiris TJ, Khouri AS. Cat-scratch penetrating globe injury with inadvertent fistula and hypotony. *Can J Ophthalmol.* 2017;52(1):e5–7.
37. Galloway NR, Robinson GE. Panophthalmitis due to Pasteurella septica. *Br J Ophthalmology.* 1973;57(3):153–5. doi:10.1136/bjo.57.3.153.
38. Yokoyama T, Hara S, Funakubo H, Sato N. Pasteurella multocida endophthalmitis after a cat bite. *Ophthalmic Surg.* 1987;18:520–2.
39. Weber DJ, Wolfson JS, Swartz MN, Hooper DC. Pasteurella multocida infections. Report of 34 cases and review of the literature. *Med (Baltimore).* 1984;63(3):133–54.
40. Kizer KW. Epidemiologic and clinical aspects of animal bite injuries. *JACEP.* 1979;8(4):134–41. doi:10.1016/s0361-1124(79)80339-1.
41. Ho AC, Rapuano CJ. Pasteurella multocida keratitis and corneal laceration from a cat scratch. *Ophthalmic Surg.* 1994;24(5):346–8.
42. Sylvester DA, Burnstine RA, Bower JR. Cat-inflicted corneal laceration: a presentation of two cases and a discussion of infection-related management. *J Pediatr Ophthalmol Strabismus.* 2002;39(2):114–7.
43. Goldblum D, Frueh BE, Koerner F. Eye injuries caused by cow horns. *Retina.* 1999;19(4):314–7. doi:10.1097/00006982-199907000-00008.
44. Helbig H, Iseli HP. Traumatic rupture of the globe caused by cow horns. *Eur J Ophthalmol.* 2002;12(4):304–8. doi:10.1177/112067210201200409.
45. Nagarajan S. Patients presenting with bull-related injuries to a southern Indian emergency department. *West J Emerg Med.* 2020;21(6):291–4. doi:10.5811/westjem.2020.5.47212.
46. Butterwick DJ, Meeuwisse WH. Bull riding injuries in professional rodeo: data for prevention and care. *Phys Sportsmed.* 2003;31(6):37–41.
47. Shriyan SV, Mani UA, Bhot FB, Sada EC, Ursekar R, Adake D, et al. Animal injuries: a case series of Bull induced injuries in India. *Adv J Emerg Med.* 2020;4(1):1–5.
48. Murphy CG, Mcguire CM, Malley O, Harrington N, P. Cow-related trauma: a 10-year review of injuries admitted to a single institution. *Injury.* 2010;41(5):548–50.
49. Ugboko VI, Olasoji HO, Ajike SO, Amole AO, Ogundipe OT. Facial injuries caused by animal in northern Nigeria. *Br J Oral Maxillofacial Surg.* 2002;40(5):433–7.
50. Maurya RP, Bhushan P, Singh VP, Singh MK, Kumar P, Yadav I, et al. Traumatic subconjunctival dislocation of fractured posterior chamber intraocular lens by cow horn injury. *J Clin Exp Ophthalmol.* 2005;6(1). doi:10.4172/2155-9570.1000399.
51. Maurya RP, Kumar P, Yadav I, Bhushan P, Singh VP, Singh MK, et al. Cow horn injury causing sclera rupture with subconjunctival dislocation of cataract lens. *Med Res Chron.* 2005;2(1):56–60.
52. Ibrahim OA, Olusanya BA. Occupational cow horn eye injuries in Ibadan. *Annals Med Health Sci Res.* 2014;204(6):959–61. doi:10.4103/2141-9248.144926.
53. Bueso S, Frances S, Valle D, Troyano J. Ocular rupture associated with lens dislocation to the subconjunctival space. *Arch Soc Esp Oftalmol.* 2007;82(10):641–4. doi:10.4321/s0365-66912007001000009.
54. Balac K, Al-Ali MA, Abu-Zidan FM, Mahmoud TA. Globe rupture caused by a camel bite. *Trauma Case Rep.* 2019;21:100202. doi:10.1016/j.tcr.2019.100202.
55. Janjua KJ, Van Den Berg, Aa. Animal injuries presenting to Riyadh Armed Forces Hospital: a survey. *Trop Dpct.* 1994;24(2):84. doi:10.1177/004947559402400220.
56. Abu-Zidan FM, Ho E, Hefny AF, Bashir MO, Branicki F. Camel bite injuries in United Arab Emirates: a 6-year prospective study. *Injury.* 2012;43(9):1617–20. doi:10.1016/j.injury.2011.10.039.
57. Al-Ali, Hefny MA, F A. Head, face and neck camel-related injuries: Biomechanics and severity. *Injury.* 2019;50(1):210–14. doi:10.1016/j.injury.2018.11.029.
58. Albazei AI, Ahmed OA, Ali NM, Alselaimey RM, Alreshidi SO. Poor outcome in camel-related eye trauma with rupture globe. *Int Med Case Rep J.* 2021;14:219–22. doi:10.2147/IMCRJ.S305158.
59. Ayanniyi AA, Monsudi KF, Danfulani M, Jiya PY, Balarabe HA. Uniocular blindness in a six-year old boy following penetrating eye injury from a domestic hen peack. *J R Soc Sh Rep.* 2013;4(2):9. doi:10.1258/shorts.2012.012025.
60. Muller L, Kohnen T. Scleral and corneal laceration with iris prolapse caused by an eagle claw. *Graefes Arch Clin Exp Ophthalmol.* 2005;243(4):377–7.
61. Kovach L, Maguluri J, Recchia S, M F. Subclinical endophthalmitis following a rooster attack. *JAAPOS.* 2006;10(6):579–80. doi:10.1016/j.jaaos.2006.08.007.
62. Wiwatwongwana D, Ausayakun S, Chaidaroon W, Wiwatwongwana A. Bat attack: an unusual cause of keratouveitis. *Graefes Arch Clin Exp Ophthalmol.* 2012;250(7):1109–10. doi:10.1007/s00417-011-1739-0.
63. Chaudhry IA, Al-Sharif AM, Hamdi M. Severe ocular and periocular injuries caused by an ostrich. *Ophthalm Plast Reconstr Surg.* 2003;19(3):246–7.
64. Levitz LM, Carmichael TR, Nissensbaum M. Severe ocular trauma caused by an ostrich. *Br J Ophthalmol.* 2004;88(4):591. doi:10.1136/bjo.2003.029116.
65. Young AL, Cheng LL, Rao SK. Corneal laceration with total but isolated aniridia caused by a pecking injury. *JCRS.* 2000;26(9):1419–21. doi:10.1016/s0886-3350(00)00365-5.
66. Horsburg BJ, Stark DJ, Harrison JD. Ocular injuries caused by magpies. *Med J Aust.* 1992;157(11-12):756–9. doi:10.5694/j.1326-5377.1992.tb141277.x.
67. Collin JR. Ocular perforating injury caused by sparrow. *BMJ.* 1975;3(5982):520–1.
68. Kronwith S, Hankin D, Lipkin P. Ocular injury from a rooster attack. *Clin Pediatr.* 1996;23:219–20.
69. Chimi M, Cm CO. Pecking injury of the eye by a hen: a case report. *J Coll Med.* 2002;7(1):33–4.
70. Gray R, Thompson J, Macrae D, Couch J. Pecking injury of the eye. *N Engl J med.* 1988;319:1021–2. doi:10.1056/NEJM198810133191521.
71. Abdullah HA, Alkhalifa SK. Ruptured Globe due to a bird attack. *Case Rep Ophthalmol.* 2016;7(1):112–4.



72. Al-Sharif EM, Alkharashi AS. An unusual case of penetrating eye injury caused by a bird: A case report with review of the pertinent literature. *Saudi J Ophthalmol.* 2019;33(2):196–9. doi:10.1016/j.sjopt.2018.12.007.
73. Ono T, Abe K, Mori Y, Nejima R, Iwasaki T, Aihara M, et al. Escheria coli Panophthalmitis after pecking by a Great Egret (*Ardea alba*). *Case Rep Ophthalmol.* 2020;11:466–72. doi:10.1159/000509340.
74. Buschmann W. Preserving injured lenses by microsurgical management of capsule wounds. Indications, technique, results and problems. *Klin Monbl Augenheilkd.* 1990;196(5):329–33. doi:10.1055/s-2008-1046186.
75. Baskaran P, Ramakrishnan S, Dhoble P, Gubert J. Traumatic endophthalmitis following a crane picking injury- an unusual mode. *GMS Ophthalmol Cases.* 2016;p. Doc01. doi:10.3205/oc000038.
76. Tabatabaei SA, Soleimani M, Behrouz MJ. Bird attack ocular injuries. *Retina.* 2018;38(5):945–50.
77. Geetha NT, Shivakumar HR, Amarnath PU, Kumar B, Kirthikumar R. Bear Maul Injuries in Maxillofacial Region: Our Experience. *J Maxillofac Oral Surg.* 2012;11(4):420–4.
78. Patil SB, Mody NB, Kale SM, Ingole SD. A review of 48 patients after bear attacks in Central India: Demographics, management and outcomes. *Indian J Plast Surg.* 2015;48(1):60–5. doi:10.4103/0970-0358.155267.
79. Shah AA, Mir BA, Ahmad I, Latoo S, Ali A, Shah BA, et al. Pattern of bear maul maxillofacial injuries in Kashmir. *Natl J Maxillofac Surg.* 2010;1(2):96–101. doi:10.4103/0975-5950.79208.
80. Frank RC, Mahabir RC, Magi E, Lindsay RL, Haas WD. Bear maulings treated in Calgary, Alberta: Their management and sequelae. *Can J Plast Surg.* 2006;14(3):158–62. doi:10.1177/229255030601400301.
81. Singh AK, Dulal S, Mayya J. A Rare case of bear attack on the face and the treatment in college of medical sciences. *JCMS Nepal.* 2015;11(2):31–3.
82. Bhandari K, Haque IB, Khanal B, Joshi S. Maxillofacial Injuries in Bear, Tiger, and Jackal Attacks. *Craniofacial Trauma Reconstruction Open.* 2019;3:1–5.
83. Roka YB, Roka N, Shrestha M, Puri PR, Adhikari HB. Penetrating head injury with bilateral eye avulsion due to Himalayan bear bite. *Emerg Med Aust.* 2012;24(6):677–9. doi:10.1111/1742-6723.12007.
84. Ram R. Maxillofacial Injuries due to Bear Mauling. *J Maxillofac Oral Surg.* 2011;10(1):85–94. doi:10.1007/s12663-010-0126-4.
85. Arcieri ES, França ET, Oliveria HBD, Ferreira LDA, Rocha EJ, et al. Ocular lesions arising after stings by hymenopteran insects. *Cornea.* 2002;21(3):328–30.
86. Mayhew PJ. Why are there so many insect species? Perspectives from fossils and phylogenies. *Biological Rev.* 2007;82(3):425–54. doi:10.1111/j.1469-185X.2007.00018.x.
87. Gilboa M, Gdal-On M, Zonis S. Bee and wasp stings of the eye. Retained intralenticular wasp sting: A case report. *Br J Ophthalmol.* 1977;61(10):662–4. doi:10.1136/bjo.61.10.662.
88. Rde CZI, Piñierfía-Gonsálvez JF, Montañó C, Rodríguez C. Optic neuritis after a bee sting. *Invest Clin.* 2013;54(2):180–5.
89. Siddharthan KS, Raghavan A, Revathi R. Clinical features and management of ocular lesions after stings by hymenopteran insects. *Indian J Ophthalmol.* 2014;62(2):248–51.
90. Rai RR, Gonzalez-Gonzalez LA, Papakostas TD, Siracuse-Lee D, Dunphy R, Fanciullo L, et al. Management of Corneal Bee Sting Injuries. *Semin Ophthalmol.* 2017;32(2):177–81. doi:10.3109/08820538.2015.1045301.
91. Fitzgerald KT, Flood AA. Hymenoptera stings. *Clin Tech Small Anim Pract.* 2006;21(4):194–204. doi:10.1053/j.ctsap.2006.10.002.
92. Duff-Lynes SM, Horn EP. Ocular Bee Injuries. *EyeWiki.* 2021; Available from: [https://eyewiki.org/Ocular\\_Bee\\_Injuries](https://eyewiki.org/Ocular_Bee_Injuries).
93. Maurya RP, Mishra D, Bhushan P, Singh VP, Singh MK. Orbital Myiasis :Due to Invasion of Larvae of Flesh Fly (*Wohlfahrtia Magnifica*) in young child: rare presentation. *Case Reports Ophthalmol Med.* 2012;p. 371498. doi:10.1155/2012/371498.
94. Tomy RM, Prabhu PB. Ophthalmomyiasis externa caused by *Musca domestica* in a case of orbital metastasis. *Indian J Ophthalmol.* 2013;61(1):671–3. doi:10.4103/0301-4738.119318.
95. Maurya RP, Yadav I, Singh VP, Singh MK, Bhushan P. Orbital Myiasis (*Dermatobia Hominis*) Complicating secondary squamous cell carcinoma of medial rectus muscle. *J Clin Exp Ophthalmol.* 2015;6(1):404. doi:10.4172/2155-9570.1000404.
96. Farahvash MS, Alami HZ. Orbital ophthalmomyiasis interna posterior: report of a case with severe visual loss. *Arch Iran Med.* 1998;2:38–41.
97. Gupta M, Sharma P, Jain A, Solanky J, Sharma KK, Basu S, et al. Unusual site of snake bite. *Trop Doc.* 1995;25(3):134–5.
98. Kleinman DM, Dunne EF, Taravella MJ. Boa Constrictor Bite to the Eye. *Arch Ophthalmol.* 1998;116(7):949–50.
99. Troutman WG, Wilson LE. Topical ophthalmic exposure to rattlesnake venom. *Am J Emerg Med.* 1989;7(3):307–8. doi:10.1016/0735-6757(89)90177-0.

## Author biography

**Rajendra Prakash Maurya**, Associate Professor

**Vibha Singh**, Junior Resident

**Shankar Narayan A**, Junior Resident

**Shivangi Singh**, Senior Resident

**Syed Mehbub Ul Kadir**, Assistant Professor

**Kartika Anand**, Junior Resident

**Virendra P Singh**, Professor

**Cite this article:** Maurya RP, Singh V, Narayan A S, Singh S, Ul Kadir SM, Anand K, Singh VP. Animal induced ocular injuries: A brief review. *IP Int J Ocul Oncol Oculoplasty* 2021;7(4):335-343.