

Content available at: <https://www.ipinnovative.com/open-access-journals>IP International Journal of Forensic Medicine and
Toxicological SciencesJournal homepage: <http://www.ijfmts.com/>

Original Research Article

An autopsy study of ligature mark in 634 cases of suicidal hanging

Dinesh Rao^{1,*}¹Dept. of Forensic Medicine, The Oxford Medical College, Hospital & Research Centre, Bangalore, India

ARTICLE INFO

Article history:

Received 09-12-2021

Accepted 18-12-2021

Available online 21-01-2022

Keywords:

Suicidal Hanging

Ligature Material

Asphyxia

Suspension

Slip Knot

Hanging Types

Age

Sex

Typical Hanging

Ligature Mark

ABSTRACT

Background: In All Cases of Suspension Deaths, The Study of Ligature Mark form the Important Aspect of External Examination During Autopsy. The Character of Ligature Mark of Self Suspension is not well-defined.

Objective: To Understand the Characteristic features of Ligature Marks in suicidal Hanging.

Materials and Methods: The parameters studied were gender of victim, Knot Type and Its Position, the ligature mark with reference to its site, level, number, continuity and its Shape. Only Suicidal Hanging were included in the study.

Results: In Partial Hanging, The Major Position of the Ligature Mark, in 86% [n-153] cases was across the Thyroid Cartilage and was Nearly Horizontal in the Front. Whereas, In Complete Hanging Majority of the Ligature Mark, 92% [n-420], were situated above the Thyroid Cartilage. In 81% [n-369] of cases of Complete Hanging and 73% [n-130] of Partial Hanging, the Ligature Mark was Incomplete. In 38% [n-68] of Partial Hanging the Ligature Mark was Limited to the Front of the Neck whereas in 13% [n-59] of Complete Hanging it was limited to the Front of Neck. The Petechial Hemorrhages in Ligature Mark due to Complete hanging were Absent. A Slip Knot was used on 97.73% [n-620] of suspensions. In 78% [n-494] of Suspension the Position of the Knot was situated over the [Typical Hanging] Nape of Neck.

Conclusion: This Study Highlights the Importance of Characteristic Features of Ligature Mark in Suicidal Hanging, with particular reference to Complete and Incomplete Hanging. The High Number of Cases Studied adds up to the Relevance of the Study.

This is an Open Access (OA) journal, and articles are distributed under the terms of the [Creative Commons Attribution-NonCommercial-ShareAlike 4.0 License](https://creativecommons.org/licenses/by-nc-sa/4.0/), which allows others to remix, tweak, and build upon the work non-commercially, as long as appropriate credit is given and the new creations are licensed under the identical terms.

For reprints contact: reprint@ipinnovative.com

1. Introduction

Hanging is a Form of Mechanical Asphyxia, wherein the Constriction of the Neck is from a Ligature Encircling the Neck, the Constricting Force being the Weight of the Body [Whole Body weight or Mere Weight of the Head.¹ Hanging is a common method of suicide in which a person applies a ligature to the neck and brings about unconsciousness and then death by suspension or partial suspension. Hanging is a common suicide method. The materials necessary for suicide by hanging are readily available to the average

person, compared with firearms or poisons. In Canada, hanging is the most common method of suicide,² and in the U.S., hanging is the second most common method, after self-inflicted gunshot wounds.³ In the United Kingdom, where firearms are less easily available, in 2001 hanging was the most common method among men and the second most commonplace among women (after poisoning).⁴

Ligature marks on the neck are found in hanging and ligature strangulation. It is also well-known fact that discontinuity along the course of the ligature mark is another important criterion while describing ligature mark of hanging or strangulation.^{5,6} Authors have mentioned that hanging mark almost never completely encircles the

* Corresponding author.

E-mail address: draaforensic@yahoo.com (D. Rao).

neck.⁴⁻⁹ Authors have reported that hanging mark is situated obliquely across the circumference of neck.⁵⁻¹⁰ Where suspension point is low, the pull on the rope is almost at right angle to the axis of the body, so the resulting mark may be almost horizontal. However, exceptions occur if the suspension point is low, a horizontal mark may be produced which can be confused with strangulation. In strangulation, the mark is usually horizontal and will not show any rising peak to a suspension unlike hanging.

Ligature mark is a vital evidential piece to assess the cause of death, ligature mark depends on the nature and position of the ligature used, and the time of suspension of body after death. Ligature mark is found as pressure mark on the neck underneath the ligature.¹¹

Ligature mark is a pressure mark on the neck underneath the ligature produced due to application of Constricting Force. Initially it appears as a pale groove which on drying becomes yellowish brown parchment like.^{12,13}

In all cases of Hanging Deaths, autopsy surgeon often comes across cases when the only principle external sign present is the ligature mark on the neck. It is easy to diagnose hanging in the presence of the characteristic features of their ligature mark, which are Typically situated opposite to the Knot or Point of Suspension. However, atypical ligature marks are also seen wherein the Knot Marks and Ligature Marks are Situated over Different Regions of Neck along with Multiple Ligature Marks, causing difficulty in diagnosing hanging and Ligature strangulation. The distinction between the two types is very important because any Misinterpretation would lead to Disastrous Consequences and An Innocent may be Punished. Hence, in All Suicidal Hanging it is always important to Study and understand the Ligature Mark to Confirm the Suicidal Act and rule out foul Play. It is also essential to rule out Strangulation. Hence, this Study is done to Draw maximum information on the Ligature Mark from High Number of Cases so as to better Understand the Character of Ligature Mark in Suicidal Hanging.

TOTAL OF 9684 AUTOPSIES CONDUCTED DURING THE PERIOD 2009-2020

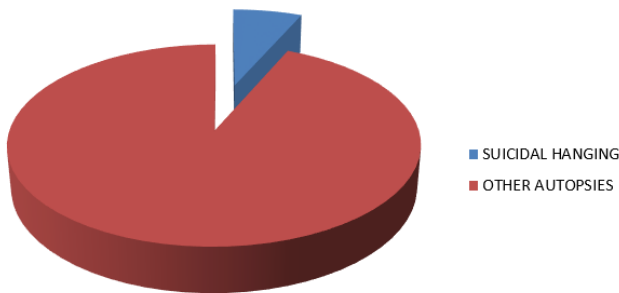


Fig. 1: The total suicidal hanging studied during the 2009-2020.

SEX DISTRIBUTION

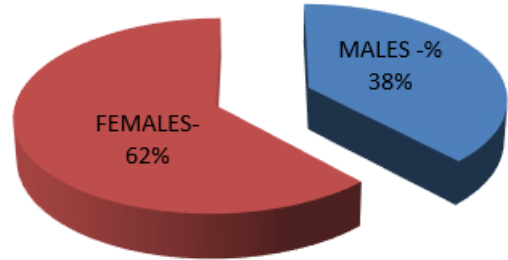


Fig. 2: Sex distribution in suicidal hanging.

HANGING TYPES

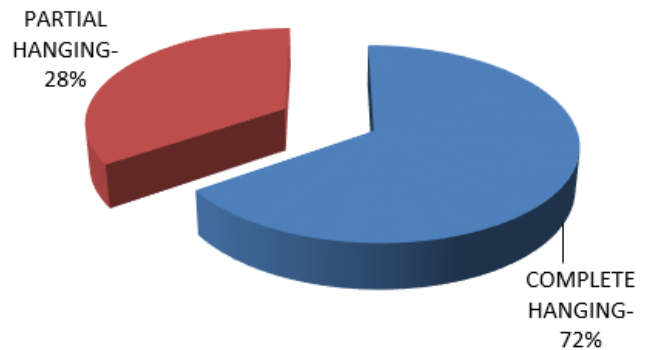


Fig. 3: Types of suicidal hanging.

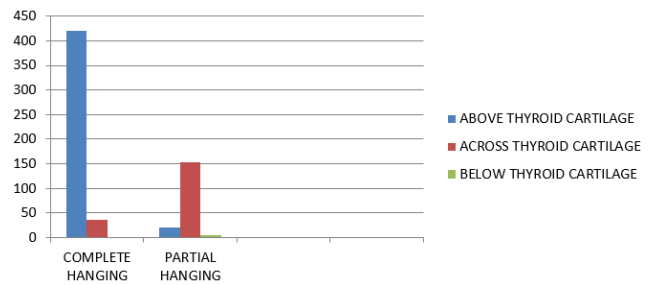


Fig. 4: The position of ligature mark in suicidal hanging.

TYPES OF KNOT

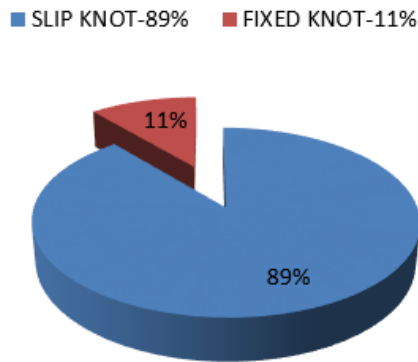


Fig. 5: Types of knots in suicidal hanging

POSITION OF THE KNOT

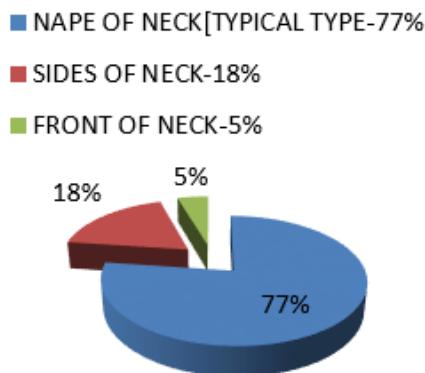


Fig. 6: Different position of knots in suicidal hanging.

2. Materials and Methods

These Prospective study was conducted between 2009 and 2020 at various regions, Kingston & Bangalore. A total of 9684 Autopsies were conducted of which Suicidal

Hanging contributed to 6.5% (n — 634) of cases. Autopsies were conducted with enmasse removal of Cranial Cavity Brain, Thoracic and Abdominal Organs and the neck was the last to be dissected after Exploring all the body Cavities. External findings of the ligature mark were described, photographed and sketched along with Taping of the Mark to correlate with the Possible Suspension Material. Internal findings of the neck studied layer by layer dissection of the neck. For Understanding of the Ligature Mark of Front of Neck, the Neck was Virtually divided into Three, considering the Thyroid Cartilage as Midline. Tapes were Used to Measure the Length of Ligature Mark along the Circumference of the Neck. Magnifying Glass Used to

Table 1: haracters of ligature marks in suicidal hanging.

Sl no	Ligature Mark	Complete Hanging-456	Partial Hanging-178
01	Damage to Skin[Grooving]	98% [n-447]	29% [n-52]
02	Intact Skin	1.3% [n-06]	28.1%[n-50]
03	Hemorrhages at the Margins	NIL	6.2% [n-11]
04	Incomplete Mark, Only 75% of Circumference.	81% [n-369]	73%[n-130]
05	Complete Mark	19% [n-87]	27%[n-48]
06	Oblique	99%[n-451]	86%[n-153]
07	Horizontal	01%[n-05]	14%[n-25]
08	Knot Mark	03%[n-14]	05%[n-09]
09	Multiple Ligature Mark with slippage of Ligature.	1.5%[n-07]	1%[n-02]
10	Only Limited to Front of Neck	13%[n-59]	38%[n-68]
11	Friction Burn of Ligature Mark	95.4%[n-435]	25.8%[n-46]
12	Self Inflicted Nail Marks over Neck and Chin	0.5%[n-02]	Nil

Understand the Skin Changes over the Ligature Mark. The parameters studied were gender of victim, Knot Type and Its Position, the ligature mark with reference to its site, level, number, continuity and its Shape. The findings were recorded both in the Post-Mortem Report and the Same were Analyzed during the Period of Study. At Times Black and White Photography used to understand the Diffuse Ligature marks because this helped to differentiate the Dark and Pale regions arising out of Skin changes as a result of Neck Compression. All Data Obtained in Each Suicidal Hanging were Documented Separately in a Standard Format and the same were Analysed at the end of the Study.

3. Results

This Prospective Study was carried out during the period 2009 to 2020. A total of 9684 cases were Autopsied during this period of Study [Figure 1]. A Total of 634 cases were studied during the period of 11years. Suicidal Hanging contributed to 6.5% [n-634] of the Cases. Males accounted for 38% cases [n-240] [Chart no 02] and Females accounted for 62% cases [n-394]. Complete Hanging contributed to 71.9% of cases [n-456] and Partial Hanging in 28.1% of cases [n-178] [Figure 3].

In Partial Hanging, the Position of Ligature Mark in 86% [n-153] cases was across the Thyroid Cartilage and was Nearly Horizontal in the Front. In 12% [n-21] of cases the Ligature Mark was situated Above the Thyroid Cartilage and was Oblique. In Only 2% [n-4] of cases the Ligature

Mark was situated Below the Thyroid Cartilage and was Oblique in Shape.[Figure 4] In complete Hanging,92% [n-420]of cases the Ligature Mark was Situated Above the Thyroid Cartilage and was Oblique in Shape, only in 08%[n-36]of cases the Ligature Mark was situated across the Thyroid Cartilage. In None of the cases The Ligature Mark was situated below the Thyroid Cartilage and the 99% of the Ligature mark was Oblique Shaped.[Figure 4]

In 98% of Complete Suspension, The Skin over the Ligature Mark Showed Heaping up of Epithelium at the Margins and in all cases of Suspension the Displaced Epithelium is Directed Upwards and Downwards. In 29% of Partial Hanging the Heaping of Epithelium and Displaced Epithelium was well appreciated.[Table 1] In 6.2% [n-11]cases of Partial Suspension there were Isolated Hemorrhages at the Margins. In none of the Cases of Complete Suspension, Hemorrhages were noted at the Margins of the Ligature Mark. [Table 1] In Complete hanging, 81% [n-369] of cases the Ligature Mark was Incomplete encircling of the Neck and comprised only 75% of the Circumference of the Neck. In 19%[n-87] the Ligature mark completely encircled the Neck, whereas in 13% [n-59] of cases the Ligature Mark was Limited to the Front of the Neck. In 03% [n-14] of cases Oval Shaped Contused Abrasions due to Knot Impressions were present. Multiple Ligature Mark & Slippage of Ligature Mark was observed in 1.5% [n-7] of the Suspensions. In 95.4% (n-435) of the cases in Complete suspension, the ligature mark showed Blackening of Skin (friction burn). Only 1.3% (n-06) of Hanging showed intact skin. Self Inflicted Nail Abrasion present in 0.5% [n-2] of the cases, and they were situated across the Neck and Chin region. [Table 1] In Partial hanging, 73%[n-130] of cases the Ligature Mark was Incomplete encircling the Neck and comprised only 75% of the Circumference of the Neck. In 27%[n-48] the Ligature mark completely encircled the Neck, whereas in 38%[n-68] of cases the Ligature Mark was Limited to the Front of the Neck. In 5,0% [n-9] of cases Oval Shaped Contused Abrasions due to Knot Impressions were present. Multiple Ligature Mark & Slippage of Ligature Mark was observed in 1% [n-02] of the Suspensions.[Table 1] In 25.8% (n-46) of the cases in Partial suspension, the ligature mark showed Blackening of Skin (friction burn). In 28.1% (n-50) of Hanging showed intact skin. Partial Hanging Reported No Cases of Self Inflicted Nail Abrasion over the Neck and Chin region.[Table 1] A Slip Knot was used on 97.73% of suspensions [Figure 5]. In 78% of Suspension the Position of the Knot was situated over the [Typical Hanging] Nape of Neck [Figure 6].

4. Discussion

This prospective study was conducted between 2009 and 2020. A total of 9684 cases were autopsied during this period, of which deaths due to hanging comprised 6.5% (n

— 634) of Autopsies. Similar studies conducted by Hassan et al.¹⁴ in a two-year period in Kuwait reported a total of 118 cases. In another study conducted by Kumar and Verma¹⁵ in Lucknow (India) a total of 4405 cases were autopsied in a five-year period of which Hanging contributed to 10% of cases. Dean et al.¹⁶ had studied on 229 cases. This Variations in the Number of Cases per Thousand Autopsies is possibly due to Regional Variations, Influence of Cultural and socioeconomic factors. Hence, the present study is Important for its high Number of Cases Studied as compared to other Studies, this makes it more Relavent & Unique in its Nature.

The present study also indicated the fact that 72% of the hangings were complete [n — 456], these results are close to the observations made by Sharma et al.¹⁷ and Saisudheer and Nagaraja,¹⁸ in their study, 68% and 64% of the cases respectively were due to Complete Hanging, however these observations are contrary to those made by Dean et al.¹⁶ They observed that 83.4% [n– 229] and 47.37% of their cases were due to Partial Hanging, all these observations highlight the regional influence, lifestyle and to a certain extent the type of residence.

In the present study females were the Major Victims comprising 62% [n-393] of cases and males contributing to 48% of Cases. These results are contrary to the claims made by Jayprakash and Sreekumar¹⁹ and Sharma et al.¹⁷ wherein, the male to female victim ratio was 2:1. However, their observations closely matched with the age group involved. The observations made by Kurtulus et al.,²⁰ Jayaprakash and Sreekumaran,¹⁹ Abd-Elwahab et al.,²¹ Suminska-Ziermann²² and Al Madni et al.²³ are more deviating as they found that the Males were more affected than females in the ratio 3:1. This wider variation in the sex group is possibly due to the cultural, religious, economic and lifestyle factors driving the individual to Suicidal Hanging. In the present study the most preferred knot was the Slip knot, contributing to 97.73% (n — 620) of cases. These results were contrary to those made by Sharma et al.¹⁷ wherein they had concluded 71% of their victims had fixed knot. The observation made by Saisudheer and Nagaraja¹⁸ was close to the observations made in the present study.

Hence, the type of knot determine the ligature mark and its continuity over the neck. In the present study, 78% (n — 494) of the victims had their knots over the Nape of the neck (typical hanging), Contrary to the views of Saisudheer and Nagaraja¹⁸ and Sharma et al.¹⁷ who had opined that 89% and 88% of the cases respectively, were Atypical Hanging [knot over the sides of neck]. This is an area which need to be Studied Furhter, the possibility of Psychological Factors influence cannot be ruled out. And the other possible factors like the victim tying the noose around his neck during the time of suspension and then jumping over it, and the other possibility is that the Changing Knot position after

suspension. The study highlights the influence of regional, religious, cultural, socioeconomic factors and demographic factors responsible for Suicidal Hanging. It also encourages further research into these factors so as to Understand Suicidal Hanging. In the present study, Majority of the Position of the Knot 77% (n — 488) of the victims Were situated over the Nape of the Neck and only 18% [n-114] over placed over the Sides of the Neck, this is Contrary to the Observations made by Saisudheer and Nagaraja¹⁸ and Sharma et al.¹⁷ who had opined that 89% and 88% of the cases respectively, were Atypical Hanging [knot over the sides of neck]. This is possibly due to the victim tying the noose around his neck during the time of suspension and then jumping over it, the other possibility is that the knot position changing after suspension during the terminal phases of hanging. In the Present Study the Situation of Ligature Mark in reference to the Thyroid Cartilage for both Complete Hanging and Partial Hanging was Made, hence this makes the Study Unique to other Studies wherein this Differentiation was not Observed. The majority of the ligature marks [92%] in complete Hanging were Situated Above the Thyroid Cartilage Whereas in Partial Hanging the Majority of Ligature Mark were Situated across the Thyroid Cartilage in 86% of cases. This Study differs and Varies with that of Study conducted by Saisudheer and Nagaraja¹⁸ & Sharma et al.¹⁷, Their Results show no differentiation on the Hanging Type, however, their results are also Contrary to those made in the present study.

The presence of ligature mark above the thyroid cartilage is due to the yielding soft tissue between upper bony margin of the jaw and the lower protruding thyroid cartilage besides the concentration of a larger force on small area of the neck. The angle of Mandible acts as the Resting Point and act as weight bearing in Suspensions, this are the major factors responsible for the Ligature Mark in High number [92%] of cases in Complete Hanging to be situated above the thyroid Cartilage. In the present study, 81% (n — 369) of the Complete Hanging & 73% [n-130] Of Partial Hanging Victims showed discontinuity (incomplete) in Ligature Marks, similar were the observations made by Jayprakash & Sreekumar¹⁹ and Saisudheer & Nagaraja.¹⁸ They had concluded that 78% and 82% of their victims, respectively showed incomplete ligature marks., though, the Hanging Type Specific Information was not available.

In the present study the most preferred knot was the Slip knot, contributing to 89% [n-564] of cases These results were contrary to those made by Sharma et al.¹⁷ wherein they had concluded 71% of their victims had fixed knot. The observation made by Saisudheer and Nagaraja¹⁶ was close to the observations made in the present study. In the present study Obliquity of the ligature mark present in 99% [n-45] and 86% [n-153] of the Complete and Incomplete Hanging Respectively, whereas Horizontal Ligature Marks was Noticed in 1% and 14% of Complete and Incomplete

Hanging, similar were the observations made by Jayprakash and Sreekumar²¹, however the Horizontal ligature mark was noted in Partial Hanging. The type of knot, continuity of mark and completeness of hanging are important in determining the ligature mark over the neck. In a Complete Hanging wherein the body is completely suspended with a slip knot the ligature mark will be oblique and continues without disruptions, whereas in fixed knot non continuity of the mark is common though Obliquity is maintained in Complete Hanging. In Partial Hanging with Slip knot the continuity is maintained but the mark is situated horizontally whereas in fixed knot with partial suspension horizontal mark is present over front of the neck and missing over the nape of the neck. Hence, the type of knot and type of suspension determine the ligature mark and its continuity over the neck. The morphology of the ligature mark highlighted that 98% (n — 447) & 29% [n-52] of the ligature mark in Complete and Incomplete Hanging Respectively, Table-1, showed grooving, contrary to the claims made by Saisudheer and Nagaraja¹⁸ wherein they had observed grooving in 54% of their cases. The possibility of not differentiating between Complete and Incomplete Hanging may be the possible reason for the similarity and contrasting results. In the present study a unique pattern was noticed with grooving that the grooving was associated with heaping up of the epithelium, Blackening, due to displacement of the superficial skin in a directional fashion. Majority of these displacements were toward the Margins of the Mark whereas in 1.4% and 24% of Complete and Incomplete Hanging Respectively, showed Intact skin. The displacement was due to the friction movement of the ligature against the skin surface of the neck during the process of decorticate and decerebrate rigidity during the process of Suspension by a ligature around the neck. This also indirectly confirms the ante mortem nature of Suspension, however further study in this area is required. The blackening or dark Brownish appearance of the displaced skin is possibly due to heat generated during the friction of ligature material against the skin surface. The author considers these observations as one of the factors in determining the ante mortem nature of hanging; these observations were not found in similar studies done elsewhere. The Present study also reported in 0.5% [n-02] cases their were Nail Marks [Scratch Abrasions] over the front of Neck and Chin, a strange observations in contrast to similar studies done elsewhere. the injuries resulting due to attempt of the victim to Ward of the Ligature Compression cannot be ruled out. Hence this Study with many unique observations has helped understand the Ligature Mark in Suicidal Hanging. It also at the same time indicates the need for Further Research to understand the varied incidences and characters in Suicidal Hanging.

5. Source of Funding

None.

6. Conflict of interest

None.

Acknowledgments

Legal medicine unit, Ministry of National security, Kingston Public Hospital, Roberts Funeral Home, Bureau of Special Investigation, SSIMS and TOMCH, Bangalore.

References

- Kannan K, Modi S. Jurisprudence and Toxicology; 2016. p. 475.
- After 50 student suicides, Andhra and Telangana govts wake up to looming crisis; 2017. Available from: [After50studentsuicides, AndhraandTelanganagovtswakeupto loomingcrisis](https://www.thehindu.com/news/national/karnataka/AndhraandTelanganagovtswakeupto loomingcrisis).
- Iqbal M. An autopsy study of suicidal hanging. *Int J Forensic Med Toxicol Sci*. 2018;6(3):108–12. doi:10.18231/ijfjmts.2021.023.
- Deepika K. Ragging leads to 15 suicides in 18 months; 2015. Available from: <https://www.thehindu.com/news/national/karnataka/ragging-leads-to-15-suicides-in-18-months/article7505345.ece>.
- Simpson K. Simpson's Forensic Medicine; 1997. p. 92–4.
- Knight B. Forensic Pathology; 1996. p. 361–89.
- Modi JP. Medical Jurisprudence & Toxicology, Butterworth's, India; 1988. p. 251–72.
- Nandy A. Principle of Forensic Medicine; 2000. p. 315–23.
- Reddy KSN, Devi KS. The Essential of Forensic Medicine & Toxicology; 2000. p. 283–95.
- Jason PJ, Anthony B, William S. Forensic Medicine-Clinical and Pathological Aspects; 2003. p. 266–9.
- Mariam A. Ligature mark on the neck;. *Professional Med J*. 2015;22(6):793–803. doi:10.29309/TPMJ/2015.22.06.1252.
- Vij K. Textbook of Forensic Medicine and Toxicology, principles and practice; 2009. p. 117–90.
- Dimmiaio VJ, Dimaio D, Asphyxia. CRC Press LLC. 2001.
- Hassan AE, Ghaleb D, Kotb SS, Agamy H, Kharoshah M. Suicidal hanging in Kuwait: retrospective analysis of cases from 2010 to 2012. *J Forensic Leg Med*. 2013;20(8):1118–39. doi:10.1016/j.jflm.2013.09.021.
- Kumar S, Verma A. A study of elderly unnatural deaths in medico-legal autopsies at Lucknow locality. *Med Sci Law*. 2013;54:127–31. doi:10.1177/00258024211026473.
- Dean DE, Kohler LJ, Sterbenz GC, Gillespie PJ, Gonzaga NS, Bauer LJ. Observed characteristics of suicidal hangings: an 11-year retrospective review. *J Forensic Sci*. 2012;57(5):1226–56. doi:10.1111/j.1556-4029.2012.02230.x.
- Sharma BR, Harish D, Sharma A, Sharma S, Singh H. Injuries to neck structures in deaths due to constriction of neck, with a special reference to hanging. *J Forensic Leg Med*. 2008;15(5):298–305. doi:10.1016/j.jflm.2007.12.002.
- Saisudheer T, Nagaraja TV. A study of ligature mark in cases of hanging deaths. *Int J Pharm Biomed Sci*. 2012;3(3):80–4.
- Jayaprakash S, Sreekumari K. Pattern of injuries to neck structures in hanging-an autopsy study. *Am J Forensic Med Pathol*. 2012;33(4):395–404. doi:10.1097/PAF.0b013e3182662761.
- Kurtulus A, Yonguc GN, Boz B, Acar K. Anatomopathological findings in hangings: a retrospective autopsy study. *Med Sci Law*. 2013;53(2):80–4. doi:10.1258/msl.2012.012030.
- Hassan AE, Ghaleb D, Kotb SS, Agamy H, Kharoshah M. Suicidal hanging in Kuwait: retrospective analysis of cases from 2010 to 2012. *J Forensic Leg Med*. 2013;20(8):1118–21. doi:10.1016/j.jflm.2013.09.021.
- Ziemann BS, B-Bogusawska E. Hangings in the material of Department of Forensic Medicine. *Arch Med Sadowej Kryminol*. 2000;63(4):267–71.
- Madni A, Kharoshah OM, Zaki MA, Ghaleb MK, S S. Hanging deaths in Dammam, Kingdom of Saudi Arabia. *J Forensic Leg Med*. 2010;17(5):265–73. doi:10.1016/j.jflm.2010.04.003.

Author biography

Dinesh Rao, Professor & HOD

Cite this article: Rao D. An autopsy study of ligature mark in 634 cases of suicidal hanging. *IP Int J Forensic Med Toxicol Sci* 2021;6(4):147-152.