

Content available at: <https://www.ipinnovative.com/open-access-journals>

IP Indian Journal of Orthodontics and Dentofacial Research

Journal homepage: <https://www.ijodr.com/>

Case Report

Managing impacted upper anterior teeth by orthodontic traction- Minimally invasive approach

Gaurav Gupta^{1,*}, D.K Gupta², Priyanka Gupta³, Parth Shah⁴, Kuldeep Singh Rana⁵, Neeraj Chandra⁶, Neelja Gupta⁷

¹Dept. of Pedodontics and Preventive Dentistry, Wisdom Dental Clinics, Jaipur, Rajasthan, India

²Wisdom Dental Clinics, Jaipur, Rajasthan, India

³Dept. of Pedodontics and Preventive Dentistry, RUHSCDS Govt Dental College, Jaipur, Rajasthan, India

⁴Saanchi Pediatric Hospital, Surat, Gujarat, India

⁵Dept. of Conservative and Endodontics, Government College of Dentistry, Indore, Madhya Pradesh, India

⁶Dept. of Pedodontics & Preventive Dentistry, Institute of Dental Sciences, Bareilly, Uttar Pradesh, India

⁷Dept. of Cosmetic & Esthetic Dentist, Wisdom Dental Clinics, Jaipur, Rajasthan, India



ARTICLE INFO

Article history:

Received 01-03-2022

Accepted 07-03-2022

Available online 31-03-2022

Keywords:

Impaction

Orthodontic traction

Surgical exposure

ABSTRACT

Interdisciplinary care for the management of impacted teeth provides exclusive method in treating patients. Careful diagnosis and planning is necessary to reach desired treatment goals. This case report attempts to highlight the importance of diagnosis and appropriate treatment plan for successful eruption of impacted upper anterior teeth, demonstrating the surgical exposure and orthodontic traction by placing hole in the crown of impacted teeth.

This is an Open Access (OA) journal, and articles are distributed under the terms of the [Creative Commons Attribution-NonCommercial-ShareAlike 4.0 License](https://creativecommons.org/licenses/by-nc-sa/4.0/), which allows others to remix, tweak, and build upon the work non-commercially, as long as appropriate credit is given and the new creations are licensed under the identical terms.

For reprints contact: reprint@ipinnovative.com

1. Introduction

A tooth that does not erupt completely in oral cavity is impacted teeth. This can be assessed through clinical and radiological findings. Abnormal eruption within dento-alveolar process may result into serious clinical manifestation and impactions.¹⁻³ Orthodontic intervention to bring back the impacted teeth into normal occlusion is important for long term function and stability.

The frequency of impaction of permanent teeth is as follows: lower 3rd molars, upper 3rd molars, upper canine, upper and lower 1st molar, upper and lower 2nd molar.^{2,3} The prevalence of impaction of permanent maxillary canine is 1-2% in the general population.^{4,5} Primary cause for impacted teeth are genetics,⁶ endocrinal deficiency, palatal clefts, irradiation, developmental abnormalities, dento-

maxillary disharmony, transverse growth deficiency of maxilla.⁷

One of the author showed that in forced eruption, the teeth could be erupted for the purpose of levelling the osseous defects, altering gingival margins and lengthening the clinical crown.⁸ This concept and its association with bone migration has been taken to treat the patient with multiple impacted teeth.^{9,10}

The purpose of this case report is to describe the successful management of multiple impacted teeth with combined surgical and orthodontic treatment, guiding the eruption of impacted teeth.

2. Case Report

A 15-year-old female patient reported to the clinic with chief complaint of missing teeth in upper front tooth region and wanted its correction. Her general physical

* Corresponding author.

E-mail address: dr.gauravgupta99@gmail.com (G. Gupta).

status was found to be normal with advance facial height and competent lips. Patient did not have any relatable past history or trauma. On intraoral examination she had clinically missing 13,21,22 and 23 with retained 53,63. Lower anterior crowding was also found. (Figure 1)

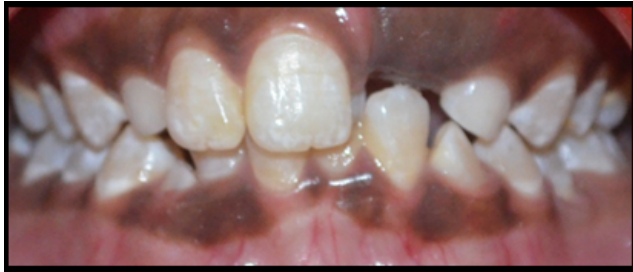

Fig. 1: Pre operative intraoral image

OPG revealed impacted 13,21,22 and 23 instead of missing teeth. The impacted lateral incisor was placed horizontally below impacted central incisor and canine away from path of eruption. (Figure 2)

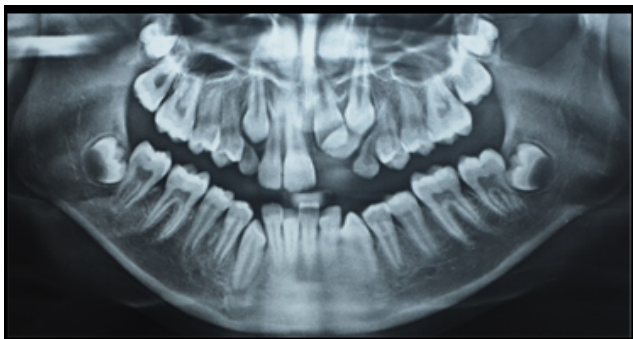


Fig. 2: OPG depicting impacted 13,21,22 and 23 teeth.

The following treatment options were there : removal of impacted teeth then giving removable partial denture later retaining with implant or bridge other option was extraction of few teeth followed with retraction of few and bringing them to occlusion. But we opted for sequential retraction and one time surgery.

Treatment objective included extraction of retained deciduous canines 53 and 63 then surgical exposure of impacted teeth followed by light orthodontic traction of left maxillary permanent central incisor then canine in place of lateral incisor and lateral incisor in place of canine as there was transposition then carrying enameloplasty to get them in level maintaining occlusion to obtain a pleasant smile.

Patient and her parents were explained about the treatment. Firstly, extraction of retained primary 53 and 63 was done and upper arch was bonded with stainless steel wire. (Figure 3)

On 2nd and 3rd visit healing at extraction site was checked with achievement of space for exposure of

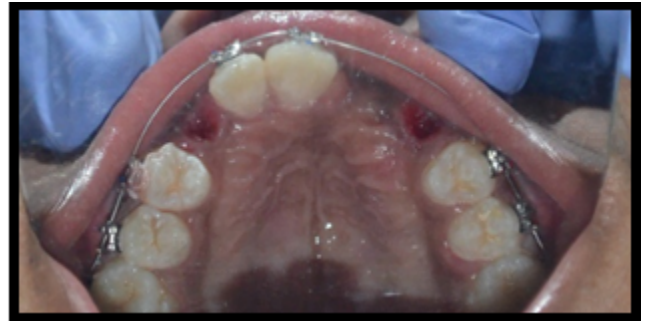

Fig. 3: Extraction of retained deciduous canines.

impacted teeth after 4 weeks.

On 4th visit surgical exposure of impacted teeth was done, tooth 21, 22 and 23 were exposed. During surgical exposure inadequate access for bonding on crown and also field was found to be contaminated with blood and saliva.

Consequently, a hole was drilled on 21,22 and 23 tooth's incisal edge away from dentin. Orthodontic stainless steel wires were inserted into the holes to increase reliability of traction procedure. Ligature wires were tied on attachments bonded on labial aspect of exposed teeth and flap was sutured back for application of traction forces. (Figure 4a,b)

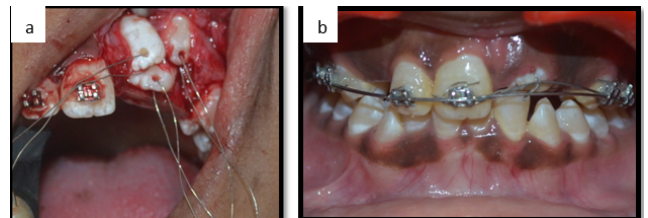


Fig. 4: a,b: Holes on incisal edge of exposed teeth with insertion of ligature wires.

After 21 and 22 appeared in oral cavity restoration was placed to fill the holes. It was observed that 22 was not at favourable eruption path and obstructed eruption of 23. (Figure 5)

Patient was called at periodic visits of 4-5 weeks to check for eruption of 13 and 23. It was found 13 erupted before 23, as there was still not proper space for eruption of 23. First retraction was done of left maxillary central incisor then canine in place of permanent lateral incisor and lateral incisor in place of canine due to transposition. (Figure 6a,b)

Later both maxillary permanent canine erupted into the oral cavity and alignment of teeth was done. (Figure 7)

Orthodontic attachments were removed after obtaining correct alignment of upper and lower arches providing with short period of retention in order to prevent relapse. (Figure 8a,b)

The gingival margin, attached gingiva were healthy and in occlusion. No pathological signs were found. After almost 2 years a pleasant smile was achieved.

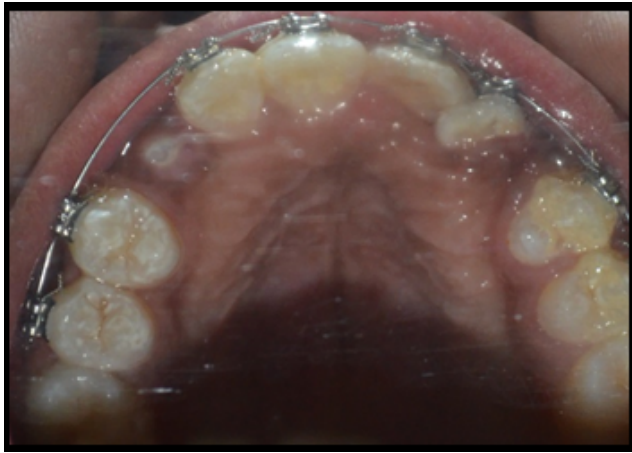

Fig. 5: Central and lateral incisor appeared in oral cavity.

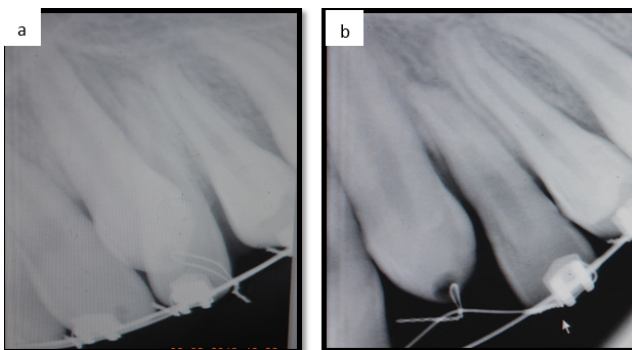


Fig. 6: a,b: Transposition of left maxillary lateral incisor and canine.

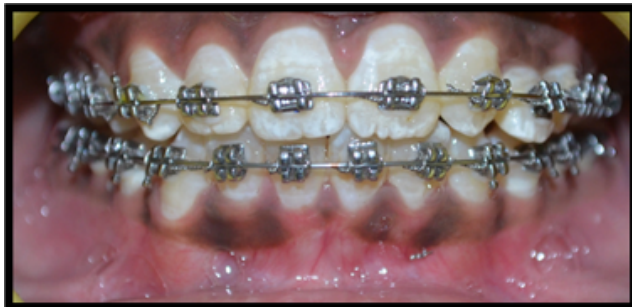

Fig. 7: Teeth alignment of the both arches.

3. Discussion

Dentists are frequently faced with anomalies of tooth during the gradual emergence of adult dentition. The impaction of maxillary incisor is mostly diagnosed clinically and radiographically at the early age, due to lack of eruption of anterior teeth cause parental concern during the early mixed dentition phase.¹¹ Studies have shown predilection of impaction in females as compared to males.¹²⁻¹⁴ In our case female patient has chief complaint of missing teeth

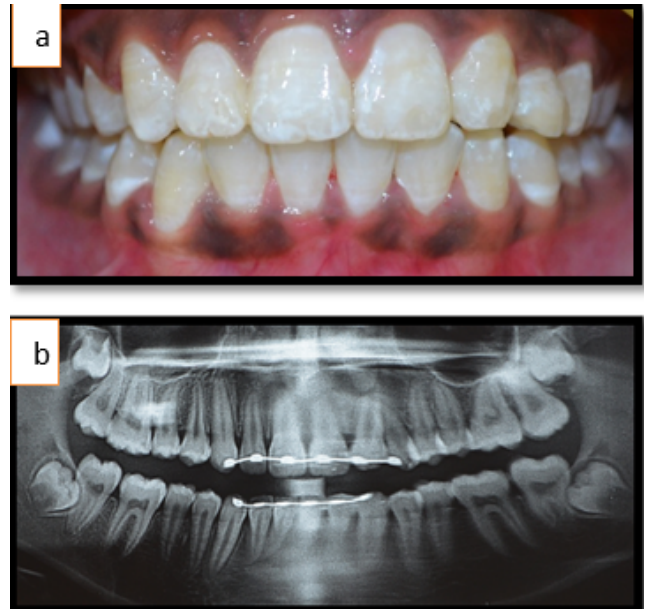


Fig. 8: a: Satisfactory alignment achieved. **b:** OPG depicting lingual retention and alignment of teeth.

and impaction was confirmed in clinical and radiological findings.

Surgical exposure and bringing the impacted tooth to its line of occlusion with the help of light orthodontic traction is the desirable approach.^{11,15,16} and was the option in our case too. The peculiarity in our case was the method of traction, drilling a hole in crown of impacted teeth rather than bonding attachment. This method was chosen after surgical exposure of impacted teeth due to inadequate access for bonding procedure. The only disadvantage of this procedure was the need for restoration of hole after achieving the desired traction.

After extraction of maxillary incisor, tooth placement with prosthetic, implant or auto transplantation of pre molar to maxillary incisor region may be one of the treatment.¹⁷ We opted for traction in our case, the periodontal ligament status of exposed central incisor, lateral incisor and canine after orthodontic treatment revealed the acceptable gingival margin eliminated the need for gingival re-contour surgery or other treatment option.

We should first determine if the impacted teeth could be successfully aligned in its proper position. It is important to plan when and how the impacted teeth should be moved to its final position maintaining occlusion. Designing and applying an ideal force relative to the centre of resistance of the tooth can be challenging task in impacted tooth that too multiple.^{1,18}

In this case we used ligature ties to apply light eruptive forces in order to avoid excessive amount of forces which can lead to root resorption. After sufficient eruption of impacted teeth in the mouth, these teeth were included in

aligning arches. Accurate and early diagnosis along with multidisciplinary approach permitted for the orthodontic traction of impacted teeth into normal alignment.

4. Conclusion

Satisfactory result was obtained with orthodontic traction of multiple impacted teeth and eventually restored the aesthetics of a young girl.

5. Conflict of Interest

The authors declare they have no conflict of interest.

6. Source of Funding

No financial support was received for the work within this manuscript.

References

- Conley RS, Boyd SB, Legan HL, Jernigan CC, Starling C, Potts C, et al. Treatment of a patient with multiple impacted teeth. *Angle Orthod.* 2007;77(4):735–41. doi:10.2319/081006-328.
- Pinho T, Neves M, Alves C. Impacted maxillary central incisor: Surgical exposure and orthodontic treatment. *Am J Orthod Dentofacial Orthop.* 2011;140(2):256–65. doi:10.1016/j.ajodo.2009.11.018.
- Jacoby H. The etiology of maxillary canine impactions. *Am J Orthod.* 1983;84(2):125–32. doi:10.1016/0002-9416(83)90176-8.
- Bedoya MM, Park JH. A review of the diagnosis and management of impacted maxillary canines. *J Am Dent Assoc.* 2009;140(12):1485–93. doi:10.14219/jada.archive.2009.0099.
- Bishara SE. Impacted maxillary canines: A review. *Am J Orthod Dentofacial Orthop.* 1992;101(2):159–71. doi:10.1016/0889-5406(92)70008-X.
- Vichi M, Franchi L. Eruption anomalies of the maxillary permanent cuspids in children with cleft lip and/or palate. *J Clin Pediatr Dent.* 1996;20(2):149–53.
- McConnell T, Hoffman DL, Forbes DP, Janzen EK, Weintraub NH. Maxillary canine impaction in patients with transverse maxillary deficiency. *ASDC J Dent Child.* 1996;63(3):190–5.
- Ingber JS. Forced eruption. I. A method of treating isolated one and two wall infrabony osseous defects-rationale and case report. *J Periodontol.* 1974;45(4):199–206. doi:10.1902/jop.1974.45.4.199.
- Ingber JS. Forced eruption: Part II. A method of treating nonrestorable teeth, Periodontal and restorative considerations. *J Periodontol.* 1976;47(4):203–16.
- Salama H, Salama. The role of orthodontic extrusive remodeling in the enhancement of soft and hard tissue profiles prior to implant placement: A systematic approach to the management of extraction site defects. *Int J Periodontics Restorative Dent.* 1993;13(4):312–33.
- Lin YT. Treatment of an impacted dilacerated maxillary central incisor. *Am J Orthod Dentofacial Orthop.* 1999;115(4):406–9. doi:10.1016/s0889-5406(99)70260-x.
- Manne R, Gandikota CS, Juvvadi SR, Rama HRM, Anche S. Impacted canines: Etiology, diagnosis, and orthodontic management. *J Pharm Bioallied Sci.* 2012;4(2):234–8. doi:10.4103/0975-7406.100216.
- Pankaj A, Akshay D. Management of impacted teeth in orthodontic practice. *J Clin Diagn Res.* 2011;5(4):894–8.
- Kokich VG. Surgical and orthodontic management of impacted maxillary canines. *Am J Orthod Dentofacial Orthop.* 2004;126(3):278–83. doi:10.1016/j.ajodo.2004.06.009.
- Macias E, De Carlos F, Cobo J. Post-traumatic impaction of both maxillary central incisors. *Am J Orthod Dentofacial Orthop.* 2003;124(3):331–8. doi:10.1016/s0889-5406(03)00305-6.
- Kuvvetli SS, Seymen F, Gencay K. Management of an unerupted dilacerated maxillary central incisor: A case report. *Dent Traumatol.* 2007;23(4):257–61. doi:10.1111/j.1600-9657.2005.00424.x.
- Czochrowska EM, Stenvik A, Album B, Zachrisson BU. Autotransplantation of premolars to replace maxillary incisors: A comparison with natural incisors. *Am J Orthod Dentofacial Orthop.* 2000;118(6):592–600. doi:10.1067/mod.2000.110521.
- Bansal N, Valiathan, Bansal F, Parkar. Management of multiple impacted teeth. *Contemp Clin Dent.* 2012;3(1):129–33.

Author biography

Gaurav Gupta, Senior Consultant  <https://orcid.org/0000-0003-3895-059X>

D.K Gupta, Senior Consultant

Priyanka Gupta, Senior Demonstrator

Parth Shah, Senior Consultant

Kuldeep Singh Rana, Assistant Professor

Neeraj Chandra, Senior Lecturer

Neelja Gupta, Senior Consultant

Cite this article: Gupta G, Gupta DK, Gupta P, Shah P, Rana KS, Chandra N, Gupta N. Managing impacted upper anterior teeth by orthodontic traction- Minimally invasive approach. *IP Indian J Orthod Dentofacial Res* 2022;8(1):50-53.