

Content available at: <https://www.ipinnovative.com/open-access-journals>

IP Indian Journal of Orthodontics and Dentofacial Research

Journal homepage: <https://www.ijodr.com/>

Original Research Article

Evaluation of mandibular condylar position in different malocclusion with Gelb's grid

Deepa Soni^{1,*}, Rohit Khanna¹, Tripti Tikku¹, Rana Pratap Maurya¹, Sneh Lata Verma¹, Kamna Srivastava¹¹Dept. of Orthodontics and Dentofacial Orthopedics, Babu Banrasi Das College of Dental Sciences, Lucknow, Uttar Pradesh, India

ARTICLE INFO

Article history:

Received 28-07-2022

Accepted 16-09-2022

Available online 27-10-2022

Keywords:

Gelb's grid

Condylar

Lateral cephalogram

Glenoid fossa

Malocclusion

ABSTRACT

Introduction: To assess condylar position using Gelb's grid in subjects with different malocclusion.**Materials and Methods:** Pre- treatment lateral cephalogram of 45 subjects (aged above 18yrs) were taken and equally divided in three groups, Group I(skeletal Class I malocclusion), Group II-(skeletal Class II malocclusion) and Group III (Class III malocclusion) based on three Cephalometric parameters (ANB, Yen angle and Wits appraisal). Condylar position in relation to glenoid fossa was assessed with Gelb's grid.**Results:** For Group I condyle was positioned normally (4,7) in 86.66% of subjects and was positioned posteriorly (5,8)13.33% of subjects. For Group II condyle was displaced posteriorly (5,8) in 86.66% of subjects and in normal position (4,7) for remaining subjects. For Group III subjects condyle was again found in posteriorly displaced 66.66% of subjects and normally positioned in rest of subjects.**Conclusion:** It can be suggested that the condylar position showed variability in three malocclusion groups. Class I malocclusion group with no skeletal discrepancy was associated with more symmetric normal condylar position than malocclusion groups with skeletal discrepancy (Class II and Class III).This is an Open Access (OA) journal, and articles are distributed under the terms of the [Creative Commons Attribution-NonCommercial-ShareAlike 4.0 License](https://creativecommons.org/licenses/by-nc-sa/4.0/), which allows others to remix, tweak, and build upon the work non-commercially, as long as appropriate credit is given and the new creations are licensed under the identical terms.For reprints contact: reprint@ipinnovative.com

1. Introduction

Mandibular condyle as well as glenoid fossa are important structures of temporomandibular joint (TMJ) that helps to sustain good occlusion and balanced stomatognathic system. Several factors like facial growth pattern, pathologic/functional alterations, decreased or increased muscular action, occlusal force and dental occlusion changes could affect TMJ morphology and pattern. As a result of these changes there is remodelling of articulating surfaces of condyle and glenoid fossa as an adaptation response. Many studies showed condyle and glenoid fossa are different in shape among patients with different malocclusions. Position of condyle in glenoid fossa

influences sagittal, transverse and vertical relationships of jaws which eventually contribute to development of various malocclusions.¹ Considering this, it can be stated that assessment of condyle position is important before starting treatment, concentric position of condyle is suggestive of normal subjects without TMJ disorders. Harold Gelb, in 1953, first described an Orthopaedic technique that correlates with the normal physiologic position of the mandibular condyle in the glenoid fossa.² Now a days there are so many imaging modalities available to visualize TMJ, and lateral cephalogram is one of them and it's taken routinely for orthodontic treatment. Hence the aim of this study was to assess condylar position using Gelb's grid in subjects with different malocclusion.

* Corresponding author.

E-mail address: ahanasoni92@gmail.com (D. Soni).

2. Materials and Methods

The study was carried out on pre-treatment Lateral Cephalogram of 45 patients (aged above 18yrs) who had come for treatment to our department for fixed Orthodontics treatment. The sample was equally divided into three groups, Group I (Class I skeletal malocclusion), Group II (Class II skeletal malocclusion) and Group III (Class III skeletal malocclusion) based on values of ANB, Yen angle and Wits appraisal.

2.1. Inclusion criteria

1. Subjects with aged above 18 years.
2. Pretreatment lateral cephalograms having full complement of permanent teeth up to 2nd molars.
3. Good quality lateral cephalograms with detectable contours of glenoid fossa.

2.2. Exclusion criteria

1. History of TMJ disorders or associated syndromes.
2. History of any TMJ injury or surgery.
3. History of having undergone Myofunctional, Orthopaedic, Orthodontic treatment.

2.3. Methodology

All the lateral cephalogram were hand traced by single operator. Following parameters were taken to confirm anteroposterior dysplasia (Figure 1).

ANB angle: Angle between point A to Nasion (N) and Nasion to point B³ (Figure 1a).

WITS Appraisal: Distance between perpendiculars drawn from point A and point B to functional occlusal plane⁴ (Figure 1b).

YEN angle: Angle between Sella to point M, and point M to point G⁵ (Figure 1c).

After dividing groups the condylar position was determined according to Gelb grid [Gelb H, Arnold G, 1959],² in maximum intercuspation.

1. To form the Gelb's grid draw a tangent to the roof of the fossa (line-1) and to eminentia (line-2), and drawing a third line half-way between these two lines. (Figure 2)
2. And draw two vertical lines, one vertical line drawn from the highest point of the roof of the articular fossa and another one from the point where the third line (the middle horizontal line) intersects the descending slope of eminence (Figure 3).
3. In this way divides the fossa into eight areas. The normal position of the condyle is Gelb's positions 4 and 7 (Figure 4).

The following condylar positions were considered in this study (Figure 5):

1. Normal position when the most part of the condyle occupied the 4 and 7 areas.
2. Posteriorly displaced when the most part of the condyle occupied the 5,8.
3. Anteriorly and inferiorly displaced when the most part of the condyle occupied the 6 and 7.

2.4. Statistical analysis

Collected data was tabulated and expressed in percentages for condylar position in respect to glenoid fossa and comprasion were made using TUKEY test with SPSS software.

2.5. Measurement reliability

Condylar position using Gelb's grid was assessed for 5 subjects again and there was no statistically significant difference between first and second measurement, hence measurements were considered to be reliable.

3. Observation and Result

Shows normal and mean values of ANB, YEN angle and Wits as obtained from sample for dividing the sample into Class I, Class II and Class III malocclusion.

Shows condylar position in respect toglenoid fossa in group I,II and III.

Shows intergroup comparison of condyle position in different malocclusion group.

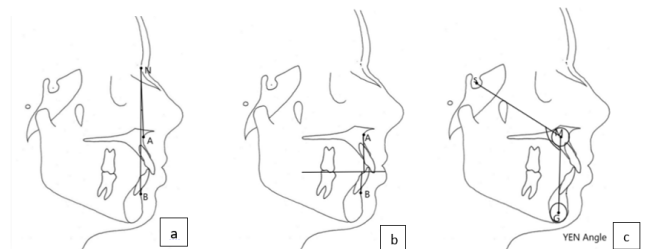


Fig. 1: Parameters used for sample distribution; **a:** ANB angle; **b:** WITS appraisal and **c:** YEN angle.

4. Discussion

Position of condyle in glenoid fossa influences sagittal, transverse and vertical relationships of jaws which eventually contribute to development of various malocclusions.¹ Diagnostic imaging could provide useful information on the TMJ structures. There are various imaging methods 2 dimensional (x-ray) and 3dimensional (CBCT) which are use to see the glenoid fossa and condylar relation, 3D imaging has its own benefits over 2D imaging (lateral cephalogram). However 3D imaging is not routinely taken for orthodontic treatment because it is expansive and high amount of radiation exposure. Lateral cephalogram

Table 1: Normal and mean values as obtained in study of ANB, YEN angle and Witsapprsal.

	ANB angle		YEN angle		Wits appraisal	
	Normal values obtained in study	Mean values obtained in study	Normal values obtained in study	Mean values obtained in study	Normal values obtained in study	Mean values obtained in study
Class I n = 15	0-2	2	117 to 123	117.25	-1.17+_1.9 (Male) -0.1+_1.77 (Female)	0.46
Class II n =15	>2	5.8	<117	114	>1(Male) >0(Female)	3.46
Class III n = 15	>0	-2.5	>123	132	<0	5.93

Table 2: Condylar position in respect toglenoid fossa in Group I, Group II and III.

group		N	Position			Total
			Normal (4,7)	Anterior (6,7)	Posterior (5,8)	
I	N	13	13	0	2	15
	%		86.7%	0.00%	13.3%	100.0%
II	N	2	2	0	13	15
	%		13.3%	0.00%	86.7%	100.0%
III	N	5	5	0	10	15
	%		33.3%	0.00%	66.7%	100.0%
Total	N	20	20	0	25	45
	%		44.4%	0.00%	55.6%	100.0%
P value						0.0001 S
Post hoc		1-2 0.0001 S	1-3 0.0001 S	2-3 0.432 NS		

Table 3: Inter group comparison of condyle position in respect to Gelb’s Grid.

Groups	P value
I vs II	0.0001
I vs III	0.0002
II vs III	0.432

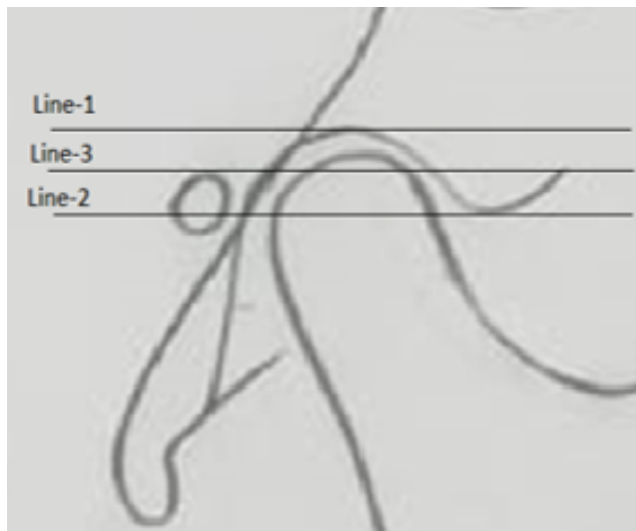


Fig. 2: Horizontal line to make Gelb’s grid.




Fig. 3: Vertical line to make Gelb’s grid




Fig. 4: Segments of Gelb's grid

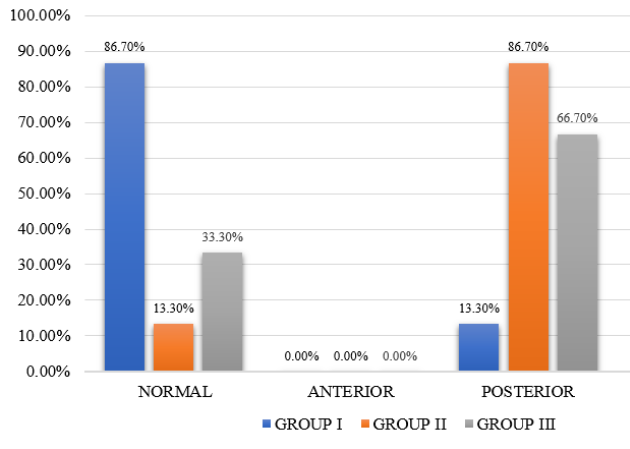


Fig. 5: Comparison of condylar position in Group I, Group II and Group III.

is routinely taken for orthodontic diagnosis hence no additional radiation exposure is needed, were taken for the present study. The limitations of a two-dimensional projection for therapeutic positioning of the condyle in relation to the fossa must be considered but this technique was chosen because of its easy availability. In present study we found that for Group I condyle was positioned normally (4,7) in 86.66% of subjects and was displaced posteriorly (5,8) 13.33% of subjects. For Group II condyle was displaced posteriorly (5,8) in 86.66% of subjects and in normal position (4,7) for remaining subjects. For Group III subjects condyle was again found in posteriorly displaced 66.66% of subjects and normally positioned in rest. On overall comparison we found statistically significant P value (0.0001). On inter group comparison, it was found that condylar position of Group I differed significantly with

Group II (P= 0.0001) and Group III(0.0001), however Group II and Group III did not differ significantly for condylar position.

The study was based on Gelb's description about condylar position in relation to glenoid fossa. In this study it was observed that 5, 8 position of Gelb's grid was more common in Class II and Class III while 4,7 (Anterior position) position was more common in Class I. Thus, we consider that the normal position of condyles should be in areas 4 and 7 (Figure 4). There are many studies in which position of condyle to glenoid fossa has been evaluated by various methods.

Amongst studies done on lateral cephalogram, Kikuchi et al found that the condyle in adolescent subjects showed a symmetrical anterior position relative to the glenoid fossa.⁶ Serra et al found condylar position was centric in maximum number of subjects in normal occlusion group using Gelb's grid on transcranial radiograph whereas displacement increased in subjects with open bite, over bite, posterior crossbite etc.⁷ Hedge et al did not show variation in condylar position in different malocclusion groups when assessed based on angular parameter. They did not find condylar position with respect to glenoid fossa.⁸ Wigal et al did his study on subjects with Class II malocclusion treated with Herbst appliance found significant positioning of condyle and glenoid fossa in compare to control group.⁹

Vankadara et al did his study on CBCT and states that centric position is most common position of condyle and 4,7 position is the most common according to Gelb's 4,7 grid. 4,7 position is found only 11.45% in angle's Class I cases.²

Kaur et al visualized and compared the position of condyle in the glenoid fossa for different occlusions using CBCT and found that 80% of the subjects exhibited superior-anterior position of the condyle.¹

Stasiuk et al found symmetric position of the condyle in 20% of subjects, out of which symmetric position is 17.65% subjects had on both sides and for class II malocclusion the most common position was 1/4 followed by 1/5 and for Group III 1/5 was most common and didn't observe 4/7 in any subject.¹⁰ According to authors the age dynamics of the aggravation of wrong position of TMJ head is clearly seen. Regardless of malocclusion, the number of patients with the correct position of the articular heads in 4/7 segment decreases from 20% to 5%. Symmetric position of condyle is most common in subjects with normal occlusion similar study was for other group with skeletal Class I malocclusion where no skeletal discrepancy existed. It can be suggested that condylar position showed variability in malocclusion groups. Further studies should be done on larger sample size and to compare condylar position between pre and post treatment radiographs after premolar extraction.

5. Conclusion

Class I malocclusion group with no skeletal discrepancy was associated with more symmetric normal condylar position than malocclusion groups with skeletal discrepancy (Class II and Class III).

6. Source of Funding

None.

7. Conflict of Interest

None.

References


1. Kaur A, Natt A, Mehra SK, Maheshwari K, Singh G, Kaur A, et al. Improved Visualization and Assessment of Condylar Position in the Glenoid Fossa for Different Occlusions: A CBCT Study. *J Contemp Dent Pract.* 2016;17(8):679–86.
2. Vankadara S, Akula B, Nissi K. Assessment and comparison of condylar position based on joint space dimensions and gelb 4/7 grid using CBCT. *J Indian Acad Oral Med Radiol.* 2021;33(1):6–11. doi:10.4103/jiaomr.jiaomr_232_20.
3. Hussels W, Nanda RS. Analysis of factors affecting angle ANB. *Am J Orthod.* 1984;85(5):411–23. doi:10.1016/0002-9416(84)90162-3.
4. Jacobson A. The Wits appraisal of jaw disharmony. *Am J Orthod.* 1975;67(2):125–38. doi:10.1016/0002-9416(75)90065-2.
5. Neela PK, Mascarhans R, Hussain A. A new sagittal dysplasia indicator: the YEN angle. *World J Orthod.* 2009;10(2):147–51.
6. Kikuchi K. association between condylar position, joint morphology and craniofacial morphology in orthodontic patients without TMJ disorders. *J Oral Rehabil.* 2003;30(11):1070–5. doi:10.1046/j.1365-2842.2003.01194.x.
7. Serra G. Evaluation of condylar position from transcranial projections in primary dentition. *Dentomaxillofac Radiol.* 2006;35(2):110–6.
8. Hegde SS, Revankar AV, Patil AK. Evaluating condylar position in different skeletal malocclusion patterns: a cephalometric study. *APOS Trends Orthod.* 2015;5(3):111–5. doi:10.4103/2321-1407.155837.
9. Wigal TG. Condyle /glenoid fossa changes of class II patients treated with the edgewise crowned herbst appliance in the early mixed dentition period. *Hong Kong Dent J;*2011(8):9–17.
10. Stasiuk AA. the evaluation of heads of TMJ position in patients with malocclusion. *N Arm Med J.* 2020;14(1):48–53.


Author biography


Deepa Soni, Post Graduate Student  <https://orcid.org/0000-0003-1961-9076>

Rohit Khanna, Professor and HOD  <https://orcid.org/0000-0002-3930-9238>

Tripti Tikku, Professor  <https://orcid.org/0000-0003-0054-8554>

Rana Pratap Maurya, Reader  <https://orcid.org/0000-0003-4708-9842>

Sneh Lata Verma, Reader  <https://orcid.org/0000-0002-9924-9521>

Kamna Srivastava, Reader  <https://orcid.org/0000-0001-9390-1454>

Cite this article: Soni D, Khanna R, Tikku T, Maurya RP, Verma SL, Srivastava K. Evaluation of mandibular condylar position in different malocclusion with Gelb's grid. *IP Indian J Orthod Dentofacial Res* 2022;8(3):161-165.