

Content available at: <https://www.ipinnovative.com/open-access-journals>

IP Indian Journal of Immunology and Respiratory Medicine

Journal homepage: <https://www.ijirm.org/>

Case Report

Polymyxin B infusion related respiratory arrest: A case report

Suresh Ramasubban¹, Subhajit Sen^{1,*}, M. Surya Kumar¹, Sanjay Bhaumik¹,
Debasis Rout¹

¹Apollo Multispeciality Hospitals, Kolkata, West Bengal, India



ARTICLE INFO

Article history:

Received 25-10-2021

Accepted 22-12-2021

Available online 31-12-2021

Keywords:

Respiratory failure

Polymyxin B

Neuromuscular blockade

ABSTRACT

A 73 years old male, known hypertensive on medication, with the history of SARS-CoV-2 infection nine months ago, presented to us with mucormycosis, he was treated with Liposomal amphotericin B initially. He developed acute kidney injury with recurrent pulmonary oedema requiring ICU admission and Haemodialysis. He later developed catheter related blood stream infection that grew Carbapenem resistant *Klebsiella pneumonia* and was started on Polymyxin B. However from day 3 of antibiotics he started to develop recurrent respiratory arrest with no apparent cause. He required a brief period of mechanical ventilation and was successfully weaned. He had recurrent such episodes with no apparent cause. After extensive work up and literature search it was diagnosed as Polymyxin B induced respiratory failure. Polymyxins were stopped, patient was discharged in a stable condition after five days of further observation and is currently on follow up with no such episode of dyspnoea.

This is an Open Access (OA) journal, and articles are distributed under the terms of the [Creative Commons Attribution-NonCommercial-ShareAlike 4.0 License](https://creativecommons.org/licenses/by-nc-sa/4.0/), which allows others to remix, tweak, and build upon the work non-commercially, as long as appropriate credit is given and the new creations are licensed under the identical terms.

For reprints contact: reprint@ipinnovative.com

1. Introduction

The Polymyxin group of antibiotics were introduced in the 1950's and were introduced into clinical medicine without the rigors of modern-day drug regulatory trials. Significant neurological and renal toxicity and advent of newer antibiotics pushed these drugs out of our therapeutic armamentarium. However, with increasing infection with multidrug-resistant organisms (MDRO) especially Carbapenemase producing Enterobacterales (CRE) and Carbapenem resistant *Acinetobacter baumannii* (CRAB) across the world, there has been a surge in the use of Polymyxins to treat such infections over the last decade or so.¹ A reduction in rate of nephrotoxicity with Polymyxins have been noted with its use over the last two decades. However, rates of neurotoxicity have not been well reported during this era of resurgence in Polymyxin use.² Herein, we

report an extremely rare occurrence of respiratory arrest following Polymyxin B administration.

2. Case Report

73 years old male with history of hypertension and COVID-19 infection (nine months ago) was admitted to the hospital for chronic sinusitis and underwent a right maxillectomy. Histopathological examination of tissue from right maxillary sinus revealed chronic inflammation with aseptate hyphae consistent with mucormycosis. There was no orbital or cerebral involvement noted on preoperative evaluation and his baseline creatinine was 1.3mg/dl. He was initiated on Liposomal Amphotericin B intravenously at 3mg/kg dose. He had severe infusion related rigors with the first three doses of the drug. On day four of infusion patient developed severe shortness of breath, chest discomfort and hypertension necessitating transfer to intensive care unit (ICU). Patient was noted to be in severe respiratory

* Corresponding author.

E-mail address: bingos.sen@gmail.com (S. Sen).

distress, unable to lie flat. Initial ECG obtained showed sinus tachycardia (Figure 1) Vitals parameters of the patient are listed in Table 1.

A diagnosis of acute pulmonary oedema, Hypertensive crisis, Acute Kidney injury (AKI) was made and patient initiated on diuretics and non-invasive ventilation. He responded well initially but continued to have oxygen requirements and increasing creatinine levels necessitating initiation of haemodialysis (HD) on day seven. His post hemodialysis Xray is shown in Figure 2. He developed new fever and SOB on day seven of ICU admission. HD Line related sepsis was diagnosed and blood cultures revealed CRE Klebsiella on day 13 admission. Klebsiella was sensitive only to Polymyxins.

At time of initiation of Polymyxin B therapy patient had stable vitals, no oxygen requirements and was able to lie flat.

On the third day of therapy with Polymyxin B infusion, patient developed sudden respiratory arrest. He became acutely unresponsive, bradypnoeic (RR of 8-10/min) with rapidly declining saturation to 30% followed by bradycardia with HR of 30/min. Patient was emergently intubated and ventilated with immediate restoration of vital signs. Over the next 30 minutes patient regained consciousness and was extubated to BiPAP. Over next few hours he was weaned off oxygen to room air. Investigation to this episode included a coronary angiogram, pulmonary angiogram and renal angiogram, all of which were normal. Neurological evaluation for seizures and myasthenia were negative. There was no evidence of pulmonary oedema clinically and radiologically. The only treatment given following this acute episode was ventilation for six hours, initially invasively and then non-invasively.

Over the next four days patient condition improved overall and on day seven of Polymyxin B therapy he had another episode of respiratory arrest with acute unresponsiveness, bradypnoea, desaturation to 10% spo₂ and bradycardia of 30/min. An ABG during this episode prior to intubation revealed. He was again emergently intubated and ventilated with immediate restoration of vital signs. Bronchoscopy, cranial MRI, chest X-ray, echocardiogram, electrocardiogram, and laboratory tests excluded pulmonary embolism, pneumothorax, airway congestion, electrolyte disturbance, and nervous system disease such as stroke and epilepsy.

After both the episodes, the patient on enquiry revealed that at the time of the crisis, he had acute breathing problems, couldn't breathe and speak and all this happened within 1-2 minutes.

A multidisciplinary board was formed to evaluate these episodes all the drugs that the patient took before respiratory distress. PMB was absolutely determined to be the cause of respiratory distress given that it is a drug that can induce neuromuscular blockade. Discontinuation of only Polymyxin B led to a rapid resolution and subsequently

there have been no episode of respiratory arrest/failure and patient is discharged home after 7 days of observation with follow up for a resolving non-oliguric AKI. A written consent was taken from the patient for using his clinical data and investigations on his follow up visit.

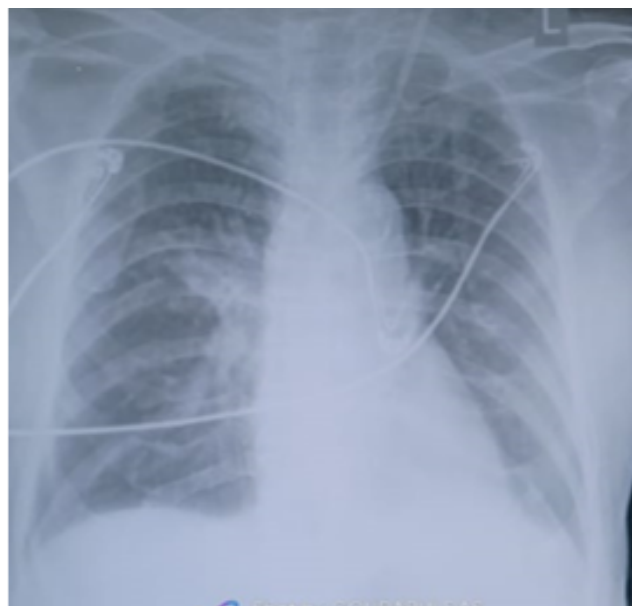


Fig. 1: Chest X-ray after two haemodialysis

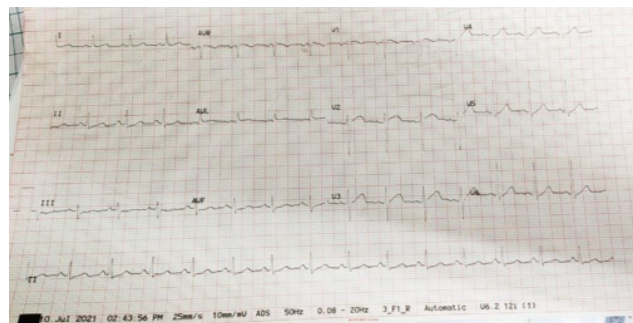


Fig. 2: Baseline ECG

3. Discussion

With the increasing burden of carbapenem resistant organism causing sepsis in the ICU, there has been a concomitant increase in the usage of Polymyxins.³ Polymyxins have become the drug of choice for infections due to Carbapenemase producing organisms at various sites in sepsis.

Respiratory arrest following respiratory muscle paralysis is a rare but potentially fatal complication of the use of Polymyxin.⁴ Our patient experienced sudden respiratory arrest twice, which required intubation and mechanical ventilation after Polymyxin B infusions, which was

Table 1: Clinical and laboratory data during episodes

Episode no	BP/PR	SpO2	Ur/Cr (mg/dl)	pH/pCO2/pO2/HCO3	NTproBNP	hsTropI
1	160/100 mm of Hg 134/min	99% wit 10lit of O2	130/5.4	7.28/28.8/98.4/13.3	21316	Not done
2	170/90 mm of Hg 122/min	92% with 15lit/min O2	206/6.7	7.19/46/101/16	29716	1338
3	150/100 mm of Hg 114/min	98% with 50% FiO2 on NIV	139/3.7	7.53/25.4/150.1/20.8	2154	112.2
4	160/90 mm of Hg 98/min	95% with 60% FiO2 AC/VC	94/3.9	7.19/65.5/72.5/24.5	1269	99.0

Naranjo Adverse Drug Reaction Probability Scale				
Question	Yes	No	Do Not Know	Score
1. Are there previous <i>conclusive</i> reports on this reaction?	+1	0	0	
2. Did the adverse event appear after the suspected drug was administered?	+2	-1	0	
3. Did the adverse reaction improve when the drug was discontinued or a <i>specific</i> antagonist was administered?	+1	0	0	
4. Did the adverse event reappear when the drug was re-administered?	+2	-1	0	
5. Are there alternative causes (other than the drug) that could on their own have caused the reaction?	-1	+2	0	
6. Did the reaction reappear when a placebo was given?	-1	+1	0	
7. Was the drug detected in blood (or other fluids) in concentrations known to be toxic?	+1	0	0	
8. Was the reaction more severe when the dose was increased or less severe when the dose was decreased?	+1	0	0	
9. Did the patient have a similar reaction to the same or similar drugs in <i>any</i> previous exposure?	+1	0	0	
10. Was the adverse event confirmed by any objective evidence?	+1	0	0	
TOTAL SCORE:				

Modified from: Naranjo CA et al. A method for estimating the probability of adverse drug reactions. *Clin Pharmacol Ther* 1981; 30: 239-245.

Fig. 3: Naranjo adverse drug reaction probability scale

consistent with the neurotoxicity of Polymyxin B. The Naranjo Adverse Drug Reaction Probability Scale score in our patient was 9 (Figure 3), which indicated a definite relationship between the administration of PMB and respiratory arrest. The case is limited with the unavailability of arterial blood gas prior to the first event as he was emergently intubated on presentation, however the second episode clearly shows a type-2 respiratory failure.

The most common side effects of the Polymyxins are seen in the renal and neurological systems.^{5,6} Neurological side effects mainly include dizziness, weakness, facial and peripheral paraesthesia, vertigo, visual disturbances, confusion, ataxia and neuromuscular blockade, which can lead to respiratory failure or respiratory arrest. The incidence of neurotoxicity is about 7% in earlier literature with paraesthesia's being the main toxicity.⁷ Acute respiratory failure due to a neuromuscular blockade is very rare and there are only about 34 cases reported so far. The proposed mechanism is a non-competitive presynaptic blockade of acetylcholine release at the neuromuscular junction. Majority of these cases have been reported before 1970s, in the last 10 years, 3 cases have been reported.⁸

The risk factors for neuromuscular failure and respiratory arrest with Polymyxin use is the presence of renal failure.⁹ In previous studies, majority of the patients had renal failure. Concomitant drug therapy also is a major risk factor for Polymyxin related neuromuscular failure.¹⁰ In previous case reports, use of other neurotoxic drugs like aminoglycosides, anaesthetic agents and corticosteroids have been implicated.

The risk of neurotoxicity is not dose dependent or directly linked to any time window following administration.¹¹ Complications can happen after one dose or even after 45 days. Nearly all cases are reversible, and they resolve over a few hours to a few days. In our case, both episodes resolved within six hours.

Since more and more cases of acute neuromuscular blockades are being reported and with increasing prevalence of CRE infections there needs to be more clarity about the utilization of Polymyxins, their dosing in renal failure and therapeutic drug monitoring. Antibiotic stewardship and use of Novel BL-BLI agents to treat CRE, especially in renal failure may be an option to prevent such near fatal cases.

4. Conclusions

Although rare, drug induced respiratory failure should be considered as a cause for respiratory failure when other common causes are excluded. Polymyxin B is an important drug associated with respiratory failure. As use of drugs like Polymyxin B are re-emerging in current clinical conditions, clinicians must be aware of this not so common side effect of Polymyxin B.

5. Acknowledgement

Dr. Shantunu Panja, Consultant ENT surgeon, Apollo Multi-speciality Hospital in this publication.

6. Conflict of Interest

The authors declare no conflict of interest.


7. Source of Funding

None.

References

1. Falagas ME, Kasiakou SK. Colistin: The revival of Polymyxins for the management of multidrug-resistant gram-negative bacterial infections. *Clin Infect Dis*. 2005;40(9):1333–41. doi:10.1086/429323.
2. Fekety FR, Norman PS, Cluff LE. The treatment of gram-negative bacillary infections with colistin. The toxicity and efficacy of large doses in forty-eight patients. *Ann Intern Med*. 1962;57:214–29. doi:10.7326/0003-4819-57-2-214.
3. Nation RL, Li J. Colistin in the 21st century. *Curr Opin Infect Dis*. 2009;22(6):535–43. doi:10.1097/QCO.0b013e328332e672.
4. Pohlmann G. Respiratory arrest associated with intravenous administration of Polymyxin B sulfate. *JAMA*. 1966;196(2):181–3.
5. Lee C, Chen D, Nagel EL. Neuromuscular block by antibiotics: Polymyxin B. *Anesth Analg*. 1977;56(3):373–7.
6. Timmerman JC, Long JP, Pittenger CB. Neuromuscular blocking properties of various antibiotic agents. *Toxicology*. 1959;1(3):299–304.
7. Lindesmith LA, Baines RD, Jr, Bigelow DB, Petty TL. Reversible respiratory paralysis associated with Polymyxin therapy. *Ann Intern Med*. 1968;68(2):318–27.
8. Koch-Weser J, Sidel VW, Federman EB, Kanarek P, Finer DC, Eaton AE, et al. Adverse effects of sodium colistimethate. Manifestations and specific reaction rates during 317 courses of therapy. *Ann Intern Med*. 1970;72(6):857–68. doi:10.7326/0003-4819-72-6-857.
9. Mendes CA, Cordeiro JA, Burdman EA. Prevalence and risk factors for acute kidney injury associated with parenteral Polymyxin B use. *Ann Pharmacother*. 2009;43(12):1948–55.
10. Pohlmann G. Respiratory arrest associated with intravenous administration of Polymyxin B sulfate. *JAMA*. 1966;196(2):181–3.
11. Zavascki AP, Goldani LZ, Cao G, Superti SV, Lutz L, Barth AL, et al. Pharmacokinetics of intravenous Polymyxin B in critically ill patients. *Clin Infect Dis*. 2008;47(10):1298–304.

Author biography

Suresh Ramasubban, Consultant Intensivist  <https://orcid.org/0000-0002-9874-0968>

Subhajit Sen, Post Doctoral Trainee  <https://orcid.org/0000-0001-8226-6678>

M. Surya Kumar, Junior Consultant. Critical Care

Sanjay Bhaumik, Consultant Neurology

Debasis Rout, Post Doctoral Trainee  <https://orcid.org/0000-0001-8391-1827>

Cite this article: Ramasubban S, Sen S, Kumar MS, Bhaumik S, Rout D. Polymyxin B infusion related respiratory arrest: A case report. *IP Indian J Immunol Respir Med* 2021;6(4):241–244.