



## Case Report

# Enamel hypoplasia: Esthetic rehabilitation

Aayushi Bangari<sup>1,\*</sup>, Anil Dhingra<sup>2</sup>, Aduaitka Anand<sup>2</sup>

<sup>1</sup>Hemvati Nandan Bahuguna Garhwal University, Srinagar, Uttarakhand, India

<sup>2</sup>Seema Dental College and Hospital, Rishikesh, Uttarakhand, India



### ARTICLE INFO

#### Article history:

Received 20-08-2022

Accepted 03-09-2022

Available online 07-10-2022

#### Keywords:

Exanthematous diseases

Nutritional deficiency

Congenital syphilis

Inflammation or Trauma during dental development

Chemical substances

and Idiopathic factors

### ABSTRACT

Due to their benefits, including immediate aesthetics, minimum invasion, cost effectiveness, adhesion to tooth structure, and chair side treatment options, direct anterior composite restorative procedures have been very popular in recent years. The most frequent reason for tissue loss in the aesthetic zone of the dentition is a severe damage to the dental hard tissue. The aesthetic restoration of maxillary central incisors with cracked incisal edges is difficult, difficult, and technique-sensitive. Success depends on the knowledge and abilities of the operator. It's crucial that the different hues are positioned with the appropriate thickness in addition to accurately recreating the anatomy. This case study demonstrates how to replicate the palatal structure of teeth that require aesthetic restoration using a putty index technique.

This is an Open Access (OA) journal, and articles are distributed under the terms of the [Creative Commons Attribution-NonCommercial-ShareAlike 4.0 License](https://creativecommons.org/licenses/by-nc-sa/4.0/), which allows others to remix, tweak, and build upon the work non-commercially, as long as appropriate credit is given and the new creations are licensed under the identical terms.

For reprints contact: [reprint@ipinnovative.com](mailto:reprint@ipinnovative.com)

## 1. Introduction

Enamel hypoplasia may be defined as an incomplete or defective formation of the organic enamel matrix of teeth.<sup>1,2</sup>

It is caused by the injury to the ameloblasts which includes nutritional deficiency, exanthematous diseases (e.g. measles, chickenpox, scarlet fever); congenital syphilis; hypocalcemia; birth injury, prematurity, Rh hemolytic disease; local infection or trauma; ingestion of chemicals (chiefly fluoride); and idiopathic causes.<sup>3</sup>

The enamel hypoplasia is an ectodermic disturbance, which is caused due to alterations in the organic enamel matrix, which can cause white flecks, narrow horizontal bands, lines of pits, grooves, and discoloration of the teeth varying from yellow to dark brwn. Enamel hypoplasia can be classified according to its degree of severity.

Enamel agenesis, enamel aplasia, and enamel hypoplasia are the three levels of severity.

Enamel hypoplasia can be influenced by hereditary causes related to autosomal dominant or recessive genes or X-linked, where both dentitions are affected.<sup>4-7</sup>

Enamel hypoplasia can also be traced to nutritional deficiencies, such as, exanthemata's diseases, hypocalcemia, congenital syphilis, inflammation or trauma during dental development, chemical substances, and idiopathic factors.

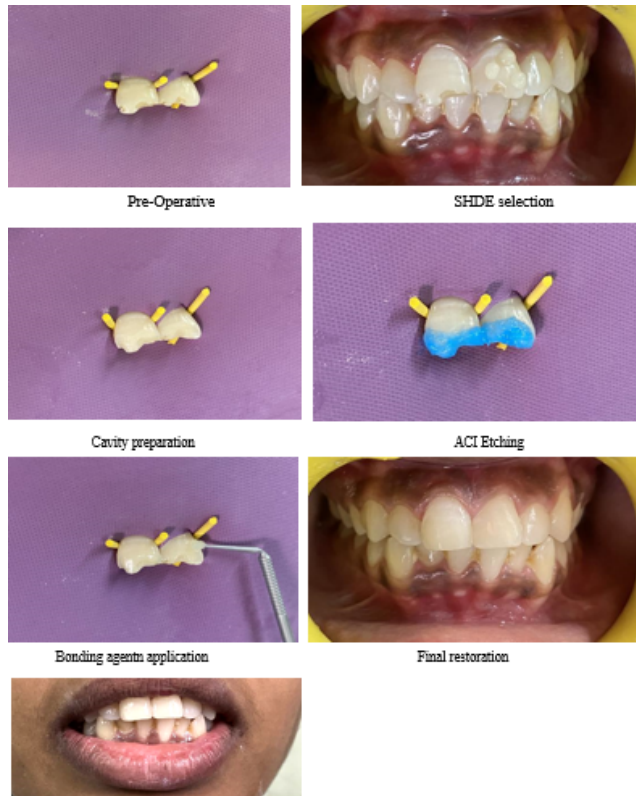
Hypoplasia can occur only during the enamel formation; consequently, if this tissue has completed its calcification, no defect can be produced. If the defect can be identified and localized, alongwith the state of development and the approximate age of the patient at that time, hypoplasia can be swiftly identified. There is no relationship between tooth crown height and the total time taken to form enamel owing to the fact that anterior crown formation is non-linear, as per Reid and Dean.<sup>7,8</sup>

\* Corresponding author.

E-mail address: [aayushibangari96@gmail.com](mailto:aayushibangari96@gmail.com) (A. Bangari).

## 2. Case Report

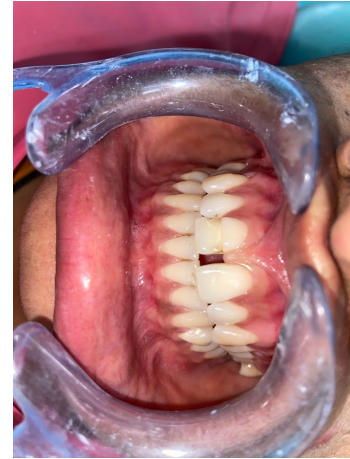A 16-year-old patient came to Seema Dental College and Hospital, Rishikesh. The patient complained of poor appearance of her anterior teeth. The patient was extremely self-conscious about the appearance of her anterior teeth and also had been bullied about her appearance.



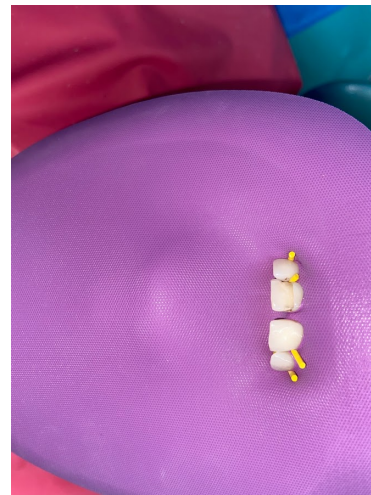**Fig. 1:**

Regardless of the restoration method used, the patient wished to restore her smile. According to the patient's medical history, she had a serious case of jaundice when she was between the ages of 2 and 4 years old. The fundamental cause of the variation in enamel formation may be jaundice. Enamel hypoplasia was determined to be severe in this particular case. The only teeth impacted were the maxillary central incisors. Although there was some tooth sensitivity in the hypoplasia-affected teeth, dental caries was not. A superfine diamond bur was used to roughen the facial enamel surfaces, between the lingual line angle and the facial line angle. For 30 seconds, 37% phosphoric acid was used to etch the enamel. Bonding agent (One Step) was applied in accordance with the manufacturer's recommendations after rinsing and drying, and it was then cured for 10 seconds using an LED curing device. Since resin composite has excellent handling characteristics and colour matching, it was chosen for the composite build-ups. In order to replicate the colour and translucency of genuine teeth, the composite was applied and polymerized

using a layering approach. Each layer received 40 seconds of face and lingual light curing for each layer. The gingival embrasure region was given extra consideration in order to create the required proximal contour. Using a low speed handpiece, polishing discs were utilised for meticulous polishing of coarse to fine grains.



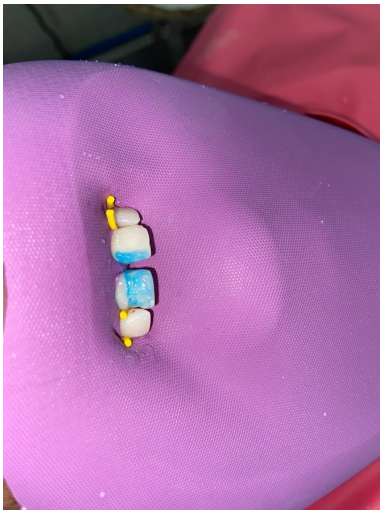**Fig. 2:** Pre-operative image



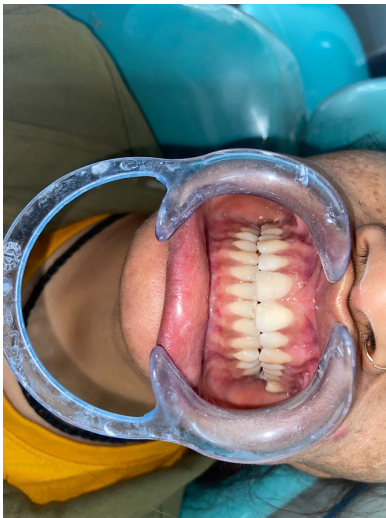**Fig. 3:** Rubber Dam isolation was done using flexidam

## 3. Case Report

A 16-year-old patient complained of brownish discoloration in the upper front tooth region and visited the department of conservative dentistry and endodontics. Additionally, a clinical examination revealed a maxillary central incisor enamel defect with rough surfaces and irregular limits that primarily affected the middle third of the crown. The patient disclosed a history of trauma to a permanent tooth caused by a car accident two years prior. The 11th tooth was found to be fractured and to have hypoplastic teeth during



**Fig. 4:**



**Fig. 5:** Post-operative view after the procedure

the intraoral examination. About half of the clinical crown length had enamel hypoplasia.

Tooth number 11 passed the vitality test. The clinical situation revealed that the best option in this case would be composite resin restoration because it was unable to restore function and appearance without the aid of a restorative procedure. On the irregularities, a minor enameloplasty was performed.

The shade A2 was taken into consideration as the beginning colour when the colour was measured using the Vitapan Classical scale (Vita Zahnfabrik, Bad Säckingen, Germany). The dental surface underwent acid etching using 35% phosphoric acid, followed by a 30-second rinse and paper towel drying.

The composite was added in increments and was light-cured after every layer, according to the manufacturer's

instructions.

#### 4. Discussion

With the right method, successful outcomes in aesthetic restorations can be obtained. The dentist must optimise the technique's several components, including the choice and use of the adhesive, the positioning of the composite resin, the design of the cavity preparation, and the method of polymerization.<sup>9,10</sup>

The association between several psychological features in kids and teenagers and the aesthetic changes caused by anterior teeth with enamel hypoplasia is a crucial component.<sup>11</sup>

Direct composite restorations can, nevertheless, yield a flawless, conservative aesthetic outcome when correctly completed.

The patient and her parents were pleased with the case report's outcome.<sup>2</sup>

#### 5. Source of Funding

None.

#### 6. Conflict of Interest

None.

#### References

- Judd PL, Casas MJ. Psychosocial perceptions of premature tooth loss in children. *Ont Dent.* 1995;72(8):22–3.
- Koroluk LD, Riekman GA. Parental perceptions of the effects of maxillary incisor extractions in children with nursing caries. *J Dent Child.* 1991;58(3):233–6.
- Alvares LC, de Souza Freitas J. Hypoplasia and hypocalcification of enamel. *Oral Surg Oral Med Oral Pathol.* 1969;28(1):73–5. doi:10.1016/0030-4220(69)90196-0.
- Anderson B. Developmental enamel defects-clinical descriptions and classification. *Am J Dis Child.* 1942;63:154–63.
- Winter GB, Brook AH. Enamel hypoplasia and anomalies of the enamel. *Dent Clin North Am.* 1975;19(1):3–24.
- Ruprecht A, Batniji S, Neweishi E. The incidence of enamel hypoplasia in the dental office. *J Can Dent Assoc.* 1984;50:900–2.
- Mehl A, Hickel R, Kunzelmann KH. Physical properties and gap formation of light-cured composites with and without 'softstart-polymerization'. *J Dent.* 1997;25(3-4):321–30. doi:10.1016/s0300-5712(96)00044-9.
- Carvalho RM, Yoshiama M, Brewer PD, Pashley DH. In vitro study on the dimensional changes of human dentine after demineralization. *Arch Oral Biol.* 1996;41(4):369–77. doi:10.1016/0003-9969(95)00115-8.
- Feilzer AJ, Dooren LH, De Gee A, and CLD. Influence of light intensity on polymerization shrinkage and integrity of restoration-cavity interface. *Eur J Oral Sci.* 1995;103(5):322–6. doi:10.1111/j.1600-0722.1995.tb00033.x.
- Davidson CL, Feilzer AJ. Polymerization shrinkage and polymerization shrinkage stress in polymer-based restoratives. *J Dent.* 1997;25(6):435–40. doi:10.1016/s0300-5712(96)00063-2.
- Peumans M, Van Meerbeek B, Lambrechts P, Vanherle G. Porcelain veneers: a review of the literature. *J Dent.* 2000;28(3):163–77. doi:10.1016/s0300-5712(99)00066-4.

**Author biography**

**Aayushi Bangari**, Post Graduate Student

**Anil Dhingra**, Professor and Head

**Aduaitka Anand**, Post Graduate Student

**Cite this article:** Bangari A, Dhingra A, Anand A. Enamel hypoplasia: Esthetic rehabilitation. *IP Indian J Conserv Endod* 2022;7(3):139-142.