

Content available at: <https://www.ipinnovative.com/open-access-journals>

IP Indian Journal of Conservative and Endodontics

Journal homepage: <https://www.ijce.in/>

Case Report

Endodontic management of biradicular mandibular canine and mandibular lateral incisor with a missed canal: A rare case report

S Advaita Narayan^{1,*}, Naveen Kumar V¹, Athul Babu Kurian¹, Shuruthi J¹

¹Dept. of Conservative Dentistry and Endodontics, Karpaga Vinayaga Institute of Dental Sciences, Chengalpettu, Tamil Nadu, India



ARTICLE INFO

Article history:

Received 02-05-2022

Accepted 10-06-2022

Available online 07-10-2022

Keywords:

Mandibular canine

Mandibular lateral incisor

Two canals

Two roots

Single canal

Root canal treatment

ABSTRACT

Endodontic treatment may sometimes fail due to complex morphological features of the teeth. Mandibular lateral incisor and canine usually contains one root with a single root canal. Two rooted mandibular canine with two canals are rare. This paper illustrates a case report of a biradicular mandibular canine and mandibular lateral incisor with two canals.

This is an Open Access (OA) journal, and articles are distributed under the terms of the [Creative Commons Attribution-NonCommercial-ShareAlike 4.0 License](https://creativecommons.org/licenses/by-nc-sa/4.0/), which allows others to remix, tweak, and build upon the work non-commercially, as long as appropriate credit is given and the new creations are licensed under the identical terms.

For reprints contact: reprint@ipinnovative.com

1. Introduction

Mandibular canines are the cornerstone of dental arch. Their long roots are useful for prosthetic support due to its proprioceptive properties which help in determining the occlusal guidance, hence preservation of mandibular canines are of importance.

Generally the root of the mandibular canine is wider labiolingually and narrower mesiodistally with straight or curved root tips. The most common form of mandibular canine is one canal with a single root (95.4%). Incidence for a biradicular mandibular canine ranges from 1.3%¹ - 6.2%.² 75.4% mandibular lateral incisors have a single canal, 24.6% reported with two canals.² Despite the low occurrence for an anatomical variation in the teeth, the clinician must have thorough understanding of both the internal and external anatomy of teeth to achieve a successful endodontic treatment.

This article will elaborate on the identification and endodontic management of mandibular canine with two

roots and two canals and a missed canal in the mandibular lateral incisors

2. Case Report

A 35 year old female patient was referred to the Department of Conservative Dentistry and Endodontics with a chief complaint of pain in her lower front tooth region for past one week. History of pain was sudden in onset, intermittent, sharp in nature and severe nocturnally. Pain was aggravated on mastication of hot and cold foods. Past dental history revealed root canal treated 42. On clinical examination 43 were affected by caries and 42 was root canal treated. Electric pulp testing done on tooth number 43 and 42 showed a spontaneous response. On radiographic findings of 42 and 43, radiolucency involving the enamel, dentin approximating the pulp with unusual root anatomy for 43 was revealed. On suspicion, A mesial shift technique revealed an additional lingual root by SLOB rule with a bifurcation present at middle third of the root for 43 and an additional canal was identified in 42 (Figure 1). Based on clinical and radiographic findings for 43, irreversible

* Corresponding author.

E-mail address: sadvaita@yahoo.com (S. Advaita Narayan).

pulpitis was diagnosed and for 42 a missed canal was identified following a root canal treatment was planned. Patient consent was obtained for the procedure after a thorough treatment explanation.

2.1. Management of 43

Under local anesthesia, after rubber dam placement an oval shaped access cavity was prepared for 43. Access cavity was modified to expose the two orifices buccally and lingually for 43. Location and negotiation of root canals were done with a size 10K-file (Dentsply M-Access K-Files) and a DG-16 probe for 43.

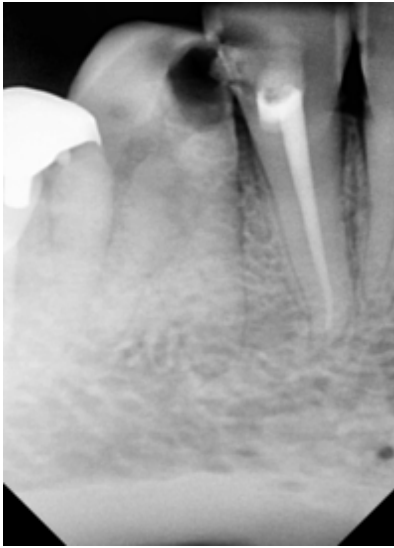

Fig. 1: Preoperative radiograph of mandibular canine and mandibular lateral incisor

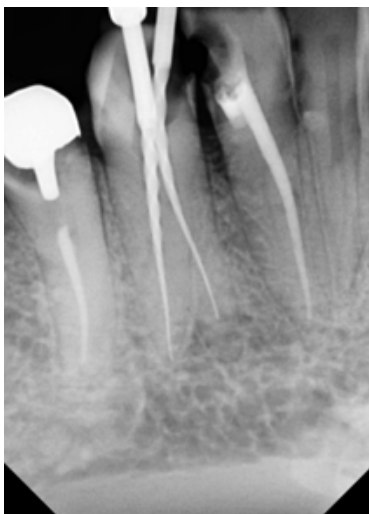

Fig. 2: Working length radiograph of mandibular canine.

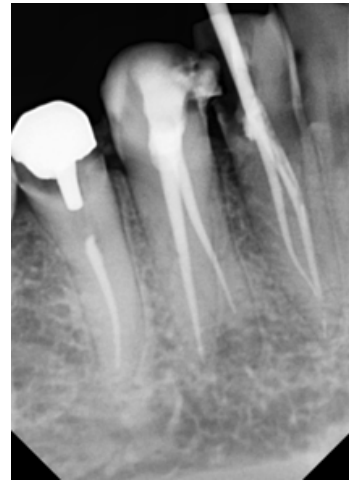


Fig. 3: Obturation radiograph of mandibular canine

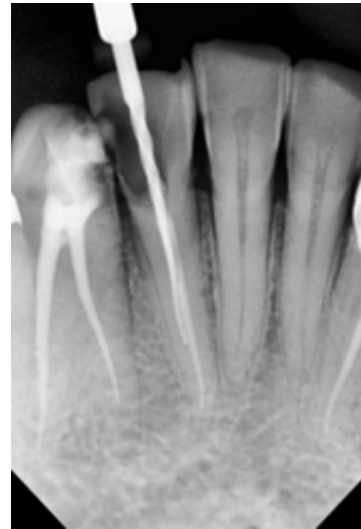

Fig. 4: Working length radiograph of mandibular lateral incisor

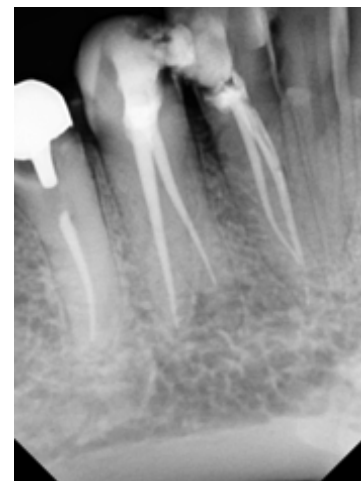

Fig. 5: Obturation radiograph of mandibular lateral incisor

Working length was established radiographically (Figure 2). Canals were prepared with ProTaper rotary system (Dentsply- Maillerfer, Ballaigues, Switzerland) till size F2 for each canal of 43. Irrigation was done with 2.5% of NaOCl between changes of instruments. Master apical cone was checked. Obturation for 43 was done on the same visit with 4% gutta- percha (Dentsply-Maillerfer, Ballaigues, Switzerland) using AH Plus Sealer (Dentsply)(Figure 3). A post endodontic restoration was done with composite resin following the Obturation.

2.2. Management of 42

Mandibular lateral incisor, 42, was also isolated with rubber dam following the local anesthetic administration of 42. Temporary restoration was removed. The access cavity prepared was ovoid in shape and was modified wider labiolingually. Lingual shoulders were removed to achieve a straight line access and to negotiate the additional canal present lingually (Vertucci's type 3 configuration).

Radiographically working length was determined for the additional canal (Figure 4). ProTaper rotary system (Dentsply- Maillerfer, Ballaigues, Switzerland) till size F1 for 42 was used to prepare the missed canal. Irrigation was done with 2.5% of NaOCl between change of instruments. Master apical cone was checked .Obturation for the additional canal was done on the same visit with 4% gutta-percha (Dentsply-Maillerfer, Ballaigues, Switzerland) using AH Plus Sealer (Dentsply) (Figure 5). A post endodontic restoration was done with composite resin following the Obturation.

3. Discussion

Missed canals are the most common etiology for the failure of root canal treatment, proper diagnosis and identification of canal morphology would help to achieve a successful outcome. The studies of Greene, Hess and Vertucci revealed 13%, 15% and 18% of two canals in single root of mandibular canines respectively.^{3,4} It has been reported that 15% of mandibular canines presented with two canals with one or two foramina.^{4,5} Soleymani et al. (2017)⁶ through his CBCT clinical studies reported 2.5% prevalence of mandibular canines with two roots and two canals. Mohammed Mashyakhy (2019)⁷ reported the prevalence of two roots and two canals of mandibular canines in the Saudi population as 2.7% and 9.3%. Caliskan et al. (1995)⁸ studied one hundred Turkish mandibular lateral incisor teeth using a clearing technique and found that 15.69% specimens had Vertucci Type III configuration. Shishir Singh et al.(2016) noted that Indian mandibular central incisors have 4% Vertucci Type III configuration.⁸

Developmental depressions are normally present on both mesial and distal surfaces of mid root of mandibular canine. On relative deepening of the depressions, occasionally two roots are formed buccally and lingually.⁹ Sharma

et al.(1998)¹⁰ and Versiani et al.(2011)¹¹ observed root bifurcations were present at cervical, middle and apical third of mandibular canines. If the bifurcation is located apically diagnosing and treating the case would be difficult. In the present case the two roots were suspected in the intraoral periapical radiograph as the buccal root was present slightly mesial to the lingual root, hence no exact superimposition of both roots in an angled radiograph.¹² The canals of both mandibular canine and lateral incisors were obturated with 4% gutta-percha (Dentsply-Maillerfer, Ballaigues, Switzerland) to preserve the pericervical dentin and the anatomical alteration.

Pre-operative radiographs with multiple angulations (20-25° or Clark's technique).¹³ Cone Beam Computed Tomography (CBCT) evaluates accurately in axial, sagittal and coronal planes if diagnosis couldn't be made using conventional radiographs,¹⁴ analysis of the periodontal ligament continuity in X-rays, efficient explorers, modified access opening involving buccolingual extensions, adequate illumination and usage of augmentative equipments such as magnifying loupes or endodontic microscope would help clinicians to identify additional canals.^{12,15,16}

4. Conclusion

Detailed awareness over tooth and root canal morphology, anatomical aberrations and minute radiographic interpretations may help in reducing failures in endodontic therapy despite the low incidence of extra canals in mandibular canines.

5. Source of Funding

None.

6. Conflict of Interest


None.

References

- Han T, Ma Y, Yang L, Chen X, Zhang X, Wang Y, et al. A study of root canal morphology of mandibular anterior teeth using cone beam computed tomography in a Chinese subpopulation. *J Endod.* 2014;40(9):1309–14. doi:10.1016/j.joen.2014.05.008.
- Barrett M. The internal anatomy of the teeth with special reference to the pulp and its branches. *Dent Cosmos.* 1925;67:581–92.
- Green D. Double canals in single roots. *Oral Surg Oral Med Oral Pathol.* 1973;35(5):689–96. doi:10.1016/0030-4220(73)90037-6.
- Vertucci FJ. Root canal anatomy of the mandibular anterior teeth. *J Am Dent Assoc.* 1974;89(2):369–71. doi:10.14219/jada.archive.1974.0391.
- Pineda F, Kuttler Y. Mesiodistal and buccolingual roentgenographic investigation of 7,275 root canals. *Oral Surg Oral Med Oral Pathol.* 1972;33(1):101–10. doi:10.1016/0030-4220(72)90214-9.
- Soleymani A, Namaryan N, Moudi E, Gholinia A. Root canal morphology of mandibular canine in an Iranian population: A CBCT assessment. *Iran Endod J.* 2017;12(1):78–82. doi:10.22037/iej.2017.16.


7. Mashyakh M. Prevalence of a Second Root and Canal in Mandibular and Maxillary Canines in a Saudi Arabian Population: A Cone-beam Computed Tomography Study. *J Contemp Dent Pract.* 2019;20(7):773–7.
8. Singh S, Pawar M. Root and canal morphology of mandibular incisors and canines in South Asian Indian population by canal staining and tooth clearing technique. *Endodontology.* 2016;28(2):148–53. doi:10.4103/0970-7212.195435.
9. Rotstein I, Ingle JJ. *Ingle's Endodontics.* USA: PMPH; 2019.
10. Sharma R, Pécora JD, Lumley PJ, Walmsley AD. The external and internal anatomy of human mandibular canine teeth with two roots. *Endod Dent Traumatol.* 1998;14(2):88–92. doi:10.1111/j.1600-9657.1998.tb00817.x.
11. Versiani MA, Pécora JD, Sousa-Neto MD. The anatomy of two rooted mandibular canines determined using micro-computed tomography. *Int Endod J.* 2011;44(7):682–7. doi:10.1111/j.1365-2591.2011.01879.x.
12. Malik A, Bansal P, Nikhil V, Singh D. Biradicular mandibular canine: A review and report of two cases. *Endodontology.* 2018;30(2):159–62. doi:10.4103/endo.endo_92_17.
13. Plascencia H, Cruz A, Gascón LG, Ramírez B, Diaz MB. Mandibular Canines with Two Roots and Two Root Canals: Case Report and Literature Review. *Case Rep Dent.* 2017;(4):1–9. doi:10.1155/2017/8459840.
14. Bhaskar A, Kumar R, Nawal RR, Talwar S. Demystifying the Complexity: A Case Report on the Management of Mandibular Canine with Two Roots. *Cureus.* 2020;12(2):e7072. doi:10.7759/cureus.7072.
15. Bawa P, Gaddalay S, Kale A. Mandibular Canine With Two Root Canals. *JMSCR.* 2017;05:22186–9. doi:10.18535/jmscr/v5i5.146.
16. Stojanac I, Premović M, Ramić B, Petrović L. Clinical Features and Endodontic Treatment of Two Rooted Mandibular Canines: Report of Four Cases. *Srp Arh Celok Lek.* 2014;142(9-10):592–6. doi:10.2298/sarh1410592s.

Author biography

S Advaita Narayan, Post Graduate Student  <https://orcid.org/0000-0001-5233-3972>

Naveen Kumar V, Professor  <https://orcid.org/0000-0002-7402-6348>

Athul Babu Kurian, Senior Lecturer

Shuruthi J, Senior Lecturer  <https://orcid.org/0000-0003-1731-5239>

Cite this article: Advaita Narayan S, Naveen Kumar V, Kurian AB, Shuruthi J. Endodontic management of biradicular mandibular canine and mandibular lateral incisor with a missed canal: A rare case report. *IP Indian J Conserv Endod* 2022;7(3):135-138.