

Content available at: <https://www.ipinnovative.com/open-access-journals>

IP Indian Journal of Anatomy and Surgery of Head, Neck and Brain

Journal homepage: <https://www.ijashnb.org/>

Case Report

A pediatric case of spontaneous intracerebral hemorrhage of unknown etiology

Bhavuk Kapoor^{1,*}, Mayank Kapoor²

¹Dept. of Neurosurgery, Government Medical College and Hospital, Jammu, Jammu and Kashmir, India

²Dept. of Neurosurgery, All India Institute of Medical Science Rishikesh, Uttarakhand, India



ARTICLE INFO

Article history:

Received 03-09-2022

Accepted 03-10-2022

Available online 21-10-2022

Keywords:

Paediatric ICH

Spontaneous ICH

Unknown etiology

ICH surgical evacuation

ABSTRACT

Introduction: Pediatric ICH peaks in the first year of life especially in neonatal period with hematological abnormalities or structural vascular disorders such as arteriovenous malformations (AVM) or aneurysms. Imaging modality of choice is NCCT head. Urgent surgery when indicated should be performed early.

Aims: To evaluate the causes of spontaneous ICH in paediatric patients and reviewing the literature.

Materials and Methods: We have discussed the causes of spontaneous ICH in our paediatric patient and we have discussed the management provided to this patient.

Conclusions: Taking a detailed history from the parents and the child is important for determining any history of head injury and bleeding episodes. Despite comprehensive evaluation, it may not be possible to determine the cause of ICH in some pediatric cases.

This is an Open Access (OA) journal, and articles are distributed under the terms of the [Creative Commons Attribution-NonCommercial-ShareAlike 4.0 License](https://creativecommons.org/licenses/by-nc-sa/4.0/), which allows others to remix, tweak, and build upon the work non-commercially, as long as appropriate credit is given and the new creations are licensed under the identical terms.

For reprints contact: reprint@ipinnovative.com

1. Background

Intracerebral hemorrhage (ICH) incidence among children younger than 10 years is considered to be higher than subarachnoid hemorrhage.¹

The rate of ICH among children is reported to be 0.8/100,000 person-years² resulting in mortality up to 33% and major deficits up to 40%, including seizures, cognitive and motor impairments.²⁻⁴ Pediatric ICH peaks in the first year of life especially in neonatal period with hematological abnormalities or structural vascular disorders such as arteriovenous malformations (AVM) or aneurysms.^{1,2,5,6} In Non-traumatic ICH there occurs an acute spontaneous extravasation of blood into the brain parenchyma. The hemorrhage may also extend into the ventricles or subarachnoid space.⁶

Structural vascular disorders such as an AVM, cerebral aneurysm, or moyamoya disease are the most commonly

observed causes for pediatric ICH. Other etiologies include hematological abnormalities, brain tumor, cavernous hemangioma, vasculopathy, vasculitis, cerebral and systemic infections, and more rarely due to illicit drug use.³⁻⁷ In this case report, we have presented a pediatric case of spontaneous ICH having an unknown etiology.

2. Case Discussion

A 8 months old male child presented with history of progressively increasing altered sensorium as per the history given by his parents. The child was in good health before the onset of symptoms. He had no history of head trauma, stroke, developmental delay, seizures or any history of spontaneous bruising or bleeding. His blood pressure at presentation was 106/72 mmHg, heart rate was 120/min, and respiratory rate was 24/min. He was also afebrile. At the time of Initial Neurological assessment, his GCS was: E2V1M5, PUPILS right:4 mm sluggish reaction & left :3mm reaction to light.

* Corresponding author.

E-mail address: kapoorbhavuk@yahoo.in (B. Kapoor).

Patient was intubated in view of low GCS. Urgent baseline investigations were sent. His coagulation parameters came out to be in the normal range. Patient was planned for emergency surgery after counselling the attendants. Right frontal craniotomy with evacuation of ICH was done. Adequate hemostasis was achieved. Duroplasty was done. Bone flap was kept back. Drain was kept and wound closure was done in layers.

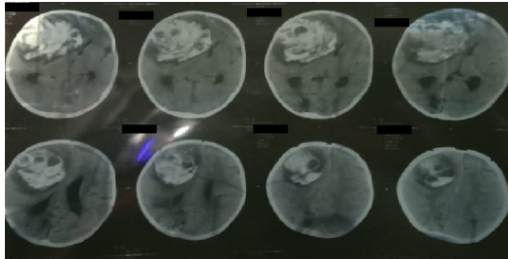


Fig. 1: NCCT head at presentation showed: Right frontal large ICH with mass effect and subfalcine herniation.

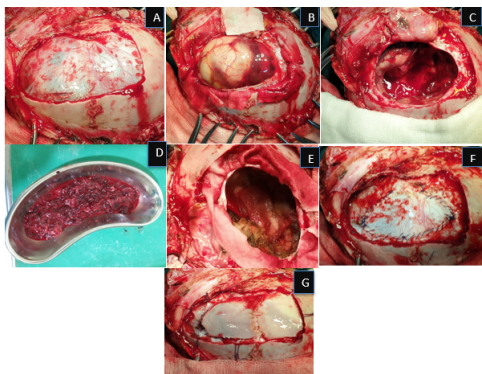


Fig. 2: a: After craniotomy; b: Parenchymal Bulge; c: After evacuation of ICH d : Evacuated ICH; e: Adequate hemostasis achieved; f: Dural closure; g: Bone flap kept back

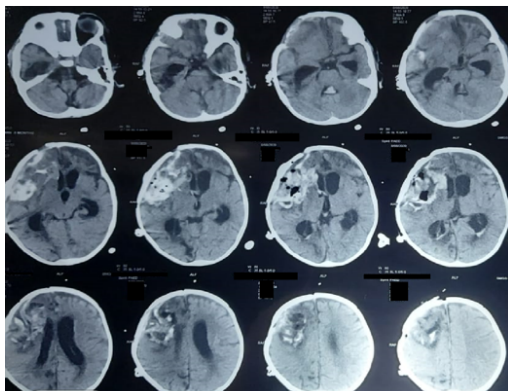


Fig. 3: Post operative NCCT Head.

Patient was subsequently extubated and then was discharged later on with GCS of E4V3M6.

3. Discussion

Even after doing comprehensive diagnostic evaluation in children with spontaneous ICH, the etiology in some cases remains unknown. The most frequently reported cause of pediatric ICH is AVM. AVM accounts for about 50% of ICH cases.^{3,8-11} In a study done by Jordan and Hillis,⁷ AVM accounts for 14 to 46% of hemorrhagic stroke in children and nearly 50% of ICH. Cavernous malformations are generally detected on MRI and may account for 3 to 22% of ICH.^{2,4,8,9,11}

Hematological abnormalities are reported to be one of the major risk factors in 10–30% of the patients; that includes thrombocytopenia, hemophilia and coagulopathies related to liver failure, disseminated intravascular coagulation, clotting factor deficiencies (factor VIII or IX), or rarely may be iatrogenic due to anticoagulation with heparin during cardiac surgery or extracorporeal membrane oxygenation.^{2,3} In our patient factor VIII levels came out to be normal. To 34% of cases of pediatric hemorrhagic stroke are attributed to Intracranial aneurysms^{2-4,8-10} Other etiologies that accounted for greater than 10% of ICH are moyamoya disease, drug abuse (cocaine or methamphetamine), hypertension and vasculopathy.^{10,12} The possible etiologies in our case may include a small AVM that had ruptured spontaneously. Since emergency surgery had to be done urgently we could not perform CT angio or MR angio brain.

The most common location of hemorrhage in children is lobar or the cerebellum, and rarely in the putamen or thalamus.¹¹ In our case also frontal lobe was the location of ICH. This is in contrast to the putamenal and lacunar vessel distribution seen in adults, due to the fact that the most common cause of ICH in pediatric population is AVM and not hypertension. The common clinical symptoms are non-specific and include severe headache, emesis, altered mental status, seizure, syncope and focal neurological deficits.^{4,6,9,11} Patient in our study presented with altered mental status. Some patients may have acute intracranial hypertension or herniation syndrome requiring urgent surgical intervention. In our case also urgent surgical intervention was required since the patient had raised Intracranial pressure and subfalcine herniation.

Typically, the initial imaging modality of choice for pediatric patients with suspected ICH is a non-contrast CT scan. Further testing as clinically indicated may include CTA, MRI, MRA, cerebral angiography and screening for coagulation abnormalities. In one study,¹² comparison was made between DSA and a combination of MRI, MRA, and magnetic resonance venography for detecting ICH in the pediatric population. It was found that DSA alone had a diagnostic yield of 61% that was statistically equivalent to

combination of all of the other three imaging modalities.

These studies reinforce the point that when non-invasive tests are unrevealing, DSA should be considered in children with spontaneous ICH. But urgent surgical intervention when indicated especially in cases having raised ICP and herniation should be performed early.

4. Conclusion

A thorough diagnostic evaluation including cerebral angiography may be necessary to determine the etiology of ICH in the pediatric population due to the heterogeneous etiologies. Taking a detailed history from the parents and the child is important for determining any history of head injury and bleeding episodes. Urgent surgery when indicated especially in cases having raised ICP and herniation should be performed early.

Despite comprehensive evaluation, it may not be possible to determine the cause of ICH in some pediatric cases.

5. Source of Funding

None.

6. Conflict of Interest

The Authors declare that there are no conflicts of interest regarding the publication of this paper.

References

1. Fullerton HJ, Wu YW, Sidney S, Johnston SC. Recurrent hemorrhagic stroke in children: a population-based cohort study. *Stroke*. 2007;38(10):2658–62.
2. Al-Rifai AJA, Riela MT, Roach AR. Nontraumatic brain hemorrhage in children: etiology and presentation. *J Child Neurol*.

2000;15(5):284–93.

3. Blom I, Schryver D, Kappelle EL, Rinkel LJ, Jennekensschinkel GJ, Peters A. Prognosis of haemorrhagic stroke in childhood: a long-term follow-up study. *Dev Med Child Neurol*. 2003;45(4):233–42.
4. Lo WD, Lee J, Rusin J, Perkins E, Roach ES. Intracranial hemorrhage in children: an evolving spectrum. *Arch Neurol*. 2008;65(12):1629–62.
5. Laugesaar R, Kolk A, Tomberg T, Metsvaht T, Lintrop M, Varendi H. Acutely and retrospectively diagnosed perinatal stroke: a population-based study. *Stroke*. 2007;38(8):2234–74.
6. Mayer SA, Rincon F. Treatment of intracerebral haemorrhage. *Lancet Neurol*. 2005;4(10):662–72.
7. Jordan LC, Hillis AE. Hemorrhagic stroke in children. *Pediatr Neurol*. 2007;36(2):73–80.
8. Meyer-Heim AD, Boltshauser E. Spontaneous intracranial haemorrhage in children: aetiology, presentation and outcome. *Brain Dev*. 2003;25(6):416–37.
9. Kumar R, Shukla D, Mahapatra AK. Spontaneous intracranial hemorrhage in children. *Pediatr Neurosurg*. 2009;45(1):37–45.
10. Visudhiphan P, Chiemchanya S, Wattanasirichaigoon D. Strokes in Thai children: etiology and outcome. *Southeast Asian J Trop Med Public Health*. 1996;27(4):801–6.
11. Lin CL, Loh JK, Kwan AL, Howng SL. Spontaneous intracerebral hemorrhage in children. *Kaohsiung J Med Sci*. 1999;15(3):146–51.
12. Liu AC, Segaren N, Cox TS, Hayward RD, Chong WK, Ganesan V. Is there a role for magnetic resonance imaging in the evaluation of non-traumatic intraparenchymal haemorrhage in children? *Pediatr Radiol*. 2006;36(9):940–6.

Author biography

Bhavuk Kapoor, Lecturer

Mayank Kapoor, Senior Resident

Cite this article: Kapoor B, Kapoor M. A pediatric case of spontaneous intracerebral hemorrhage of unknown etiology. *IP Indian J Anat Surg Head, Neck Brain* 2022;8(3):101-103.