

Content available at: <https://www.ipinnovative.com/open-access-journals>

IP Indian Journal of Anatomy and Surgery of Head, Neck and Brain

Journal homepage: <https://www.ijashnb.org/>

## Original Research Article

## The efficacy of nasolabial flap as a reconstruction modality in the surgical management of oral submucous fibrosis

Mugdha Milind Parkhi<sup>1,\*</sup>, K.C. Gupta<sup>1</sup>, Ashish Fanan<sup>2</sup><sup>1</sup>Dept. of Oral and Maxillofacial Surgery, Modern Dental College and Research Centre, Indore, Madhya Pradesh, India<sup>2</sup>G.S.R Institute of Craniofacial Surgery, Hyderabad, Telangana, India

## ARTICLE INFO

## Article history:

Received 13-08-2022

Accepted 12-10-2022

Available online 21-10-2022

## Keywords:

Nasolabial flap

Oral submucous fibrosis

Reconstruction

## ABSTRACT

The purpose of this study was to clinically assess the efficacy of nasolabial flap for reconstruction of oral cavity defects post fibrotomy in oral submucous fibrosis (OSMF) patients. The study was implemented on ten patients with OSMF with mouth openings of less than 10 mm interincisal distance. The extent of mouth opening (inter incisal distance) along with the viability and vascularity of the flap was evaluated clinically over a period 6 months. In our study, complications like flap necrosis, flap loss, infection and obstructive sialadenitis were not observed. However, intra-oral hair growth was seen in our 7 patients, extra-oral scar at the donor site was seen in all our patients and salivary fistula formation was reported in 1 of the patient which underwent fistula repair later. Mean mouth opening of 37 mm was achieved at 6 months post-operatively, with a mean increase of 31.5 mm. No relapse was encountered, even at last follow-up. On the basis of the results, we conclude that the inferiorly based nasolabial flap is an efficacious, viable and a reliable option for reconstruction of oral cavity defects in OSMF.

This is an Open Access (OA) journal, and articles are distributed under the terms of the [Creative Commons Attribution-NonCommercial-ShareAlike 4.0 License](https://creativecommons.org/licenses/by-nc-sa/4.0/), which allows others to remix, tweak, and build upon the work non-commercially, as long as appropriate credit is given and the new creations are licensed under the identical terms.

For reprints contact: [reprint@ipinnovative.com](mailto:reprint@ipinnovative.com)

## 1. Introduction

Oral submucous fibrosis is an insidious, chronic disease characterized by blanching and stiffness of the oral mucosa, leading to restricted mouth opening often referred to as trismus and burning sensation of oral mucosa.

Oral submucous fibrosis (OSMF), which presents with a severe degree of trismus, remains a difficult surgical problem.<sup>1</sup> Various treatment options have been documented in literature,<sup>1-4</sup> which includes release of fibrous bands followed by resurfacing the raw areas with skin graft, fresh human amnion, collagen, or local flaps.<sup>5</sup> Additional procedures like splitting of temporalis tendon and coronoidectomy and masseter muscle stripping have also been described to enhance mouth opening.<sup>5</sup>

The nasolabial flap is based on angular artery and thus classified as an axial pattern flap.<sup>6,7</sup> It can be superiorly based or inferiorly based. Dieffenbach in early 1830 used superiorly based nasolabial flaps to reconstruct nasal alae. In 1921 Esser described the use of the inferiorly based nasolabial flap to close palatal fistulae. The nasolabial flap is a versatile, economical option for the management of oral submucous fibrosis and has proved to be efficacious and reliable in reconstruction of head and neck defects.<sup>6,8</sup>

The elevation of flap is quick and simple, with minimal deformity of donor site and rapid post-operative rehabilitation. Also the proximity to the defect and achievement of good cosmetic result with preservation of function and least distortion of anatomy makes it the flap of choice. This paper describes the study, undertaken to assess the efficacy of nasolabial

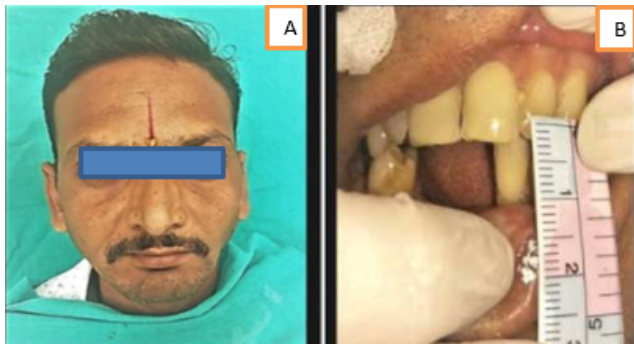flaps for reconstruction of the oral cavity defect post fibrotomy, in oral submucous fibrosis patients.

\* Corresponding author.

E-mail address: [mugdha.parkhi23@gmail.com](mailto:mugdha.parkhi23@gmail.com) (M. M. Parkhi).

## 2. Materials and Methods

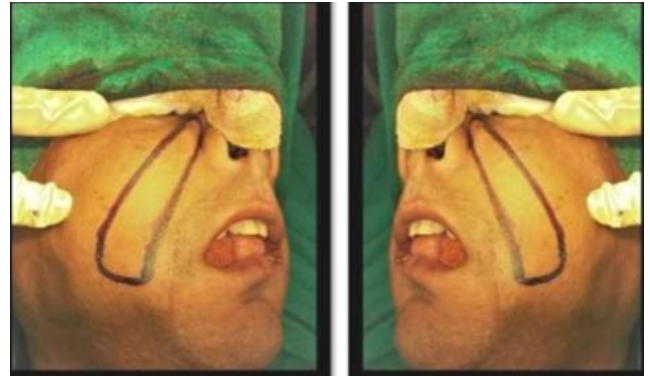
The study was carried out in the Department of Oral & Maxillofacial Surgery, Modern Dental College & Research Centre, Indore. 10 medically fit patients were chosen for the study. All these patients had a chief complaint of restricted mouth opening (interincisal distance less than 10 mm). Thus, all the cases were diagnosed as advanced oral submucous fibrosis based on long standing positive history of habits (chewing betel nut, tobacco, etc.), clinical examination and histopathological examination. Each patient's age, sex, etiology, history of habits, and preoperative mouth opening were documented (Table 1) Routine hematological investigations and radiographs were done for all patients. Patients were followed regularly for six months and maximum interincisal distance was measured (Table 3)



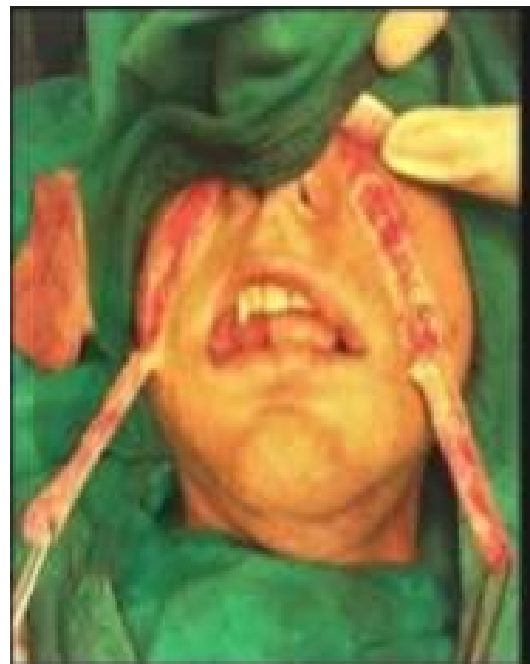**Fig. 1:** Pre operative (a); Front view (b); Mouth opening



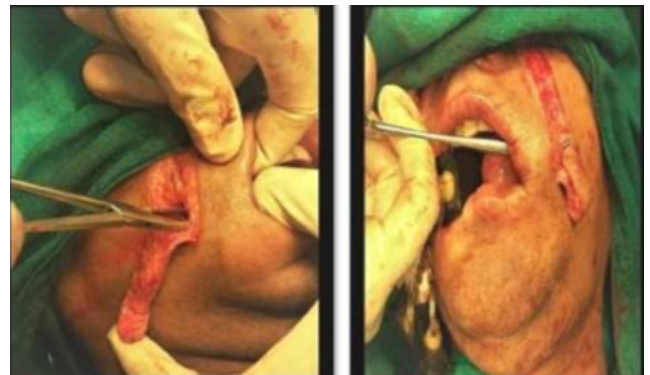**Fig. 2:** Intra-operative mouth opening



**Fig. 3:** Extra oral marking



**Fig. 4:** Bilaterally raised Nasolabial flap



**Fig. 5:** Transbuccal tunneling of Nasolabial flap

**Table 1:** (Pre-Operative Evaluation)

Case No.	Age	Sex	Chief Complaint	Type of habit	Stage of presentation
1.	43	M	Inability to open mouth since 5-6 yrs	Tobacco 4-5 pk/day, 7-8 yrs	IVa
2.	41	F	Burning sensation and inability to open mouth since 4-5 yrs	Betel nut 4-6/day	IVa
3.	28	F	Burning sensation & limitation in mouth opening since 6 years	Tobacco 4-5 times/day + lime, 7-8 yrs	IVa
4.	35	M	Inability to open mouth since 1½ years	Betelnut, 5-6/day, 7-8 yrs	IVa
5.	38	M	Inability to open mouth since 4 years	Pan Parag 8pk/day, 4-5 yrs	IVa
6.	26	M	Pain & decreased mouth opening since 3 years	Pan+Betelnut+Lime+Tobacco, 34pk/day, 10 yrs	IVa
7.	20	M	Inability to open mouth since 1½ Years	Betelnut, 10-14/day, 7 yrs	IVa
8.	20	M	Inability to open mouth + Burning sensation 4 years	Pan + Betelnut+Lime+Tobacco, 34pk/day 10 yrs	IVa
9.	32	M	Inability to open mouth since 2 Years	Betelnut, 10-12/day 4-5 yrs Smoking & Alcohol occasional	IVa
10	36	M	Inability to open mouth since 2-3 Years	Manikchand, 6-7 pk/day, 7 yr	IVa

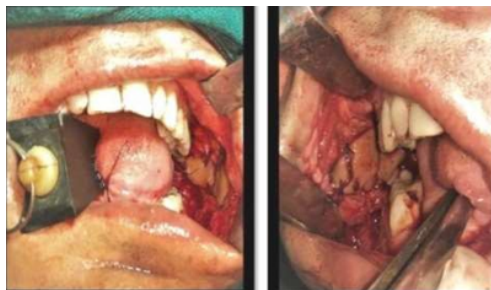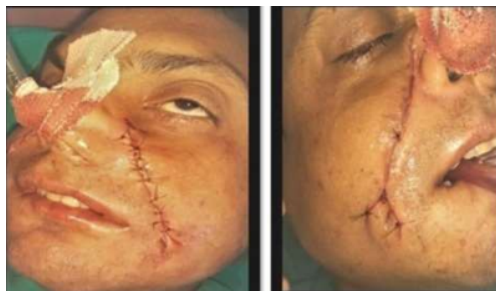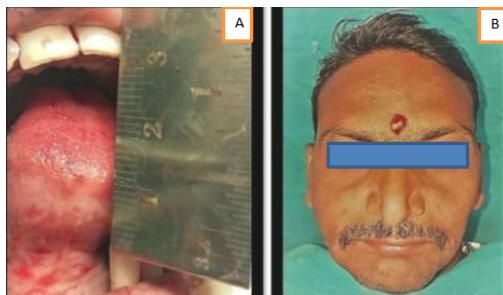**Table 2:** (Post-Operative Evaluation)

	Findings	Case no.									
		1	2	3	4	5	6	7	8	9	10
Intra Oral	Flap color	Normal	Normal	Normal	Normal	Normal	Normal	Normal	Normal	Normal	Normal
	Flap failures	X	X	X	X	X	X	X	X	X	X
	Blue/White Flap										
	Infection	X	X	X	X	X	X	X	X	X	X
	Sloughing	X	X	X	X	X	X	X	X	X	X
	Hair growth	Scanty	Absent	Absent	Scanty	Mod.	Mod.	Scanty	Scanty	Absent	Mod.
	Salivary fistula	X	X	X	Present	X	X	X	X	X	X
	Flap margin	Co-apted.	Co-apted	Co- apted.	Co- apted	Co-apted	Co- apted.	Co-apted	Co-apted	Co-apted.	Co-apted
	Co-apted/raised										
	Flap loss	X	X	X	X	X	X	X	X	X	X
Extra Oral	Partial/complete										
	Wound healing	Satis	Satis	Satis	Satis	Satis	Satis	Satis	Satis	Satis	Satis
	Wound dehiscence	X	X	X	X	X	X	X	X	X	X
	Wound infection	X	X	X	X	X	X	X	X	X	X
	Scarring	Accept	Accept	Accept	Accept	Accept	Accept	Accept	Accept	Accept	Accept

Accept: Acceptabl Satis: Satisfactory X: Absent Mod: Moderate

**Table 3:** (Mouth opening evaluation)

Case No.	Pre operative spontaneous Mouth opening (mm)	Forced intra operative mouth opening (mm)	Post operative 1 <sup>st</sup> day	Post operative 7 <sup>th</sup> day	Post operative 1 <sup>st</sup> month	Post operative 3 <sup>rd</sup> month	Post operative 6 <sup>th</sup> month
1.	1	40	25	30	32	35	38
2.	8	37	20	30	32	35	36
3.	5	45	24	32	34	36	36
4.	8	40	20	32	35	36	38
5.	5	44	28	34	35	37	37
6.	6	45	24	32	36	36	38
7.	4	40	28	32	35	36	36
8.	7	42	20	28	32	36	36
9.	2	40	20	28	35	37	37
10.	9	42	24	32	36	38	38
Mean	5.5	41.5	23.3	31	34.2	36.2	37

**Fig. 6:** Adaptation of Nasolabial flap intra-orally**Fig. 7:** Extra-Oral Suturing**Fig. 8:** Post-Operative Mouth opening (6 months) a; Mouth opening b; Front view

**Surgical Technique:** A total of ten cases of OSMF were undertaken for the study of which one case is shown (Figure 1). After informed consent surgical procedures were carried out under general anesthesia wherein the patients were intubated using the awake blind nasal technique or fiberoptic intubation under antibiotic coverage. The intraoral incisions to release the fibrous bands were made using electro-surgical knife along the buccal mucosa at the level of occlusal plane away from Stenson's duct orifice. Incision began 1 cm behind the corner of the mouth and extended posteriorly up to the anterior faucial pillars and soft palate. Undermining of the wound margins were done by blunt dissection until no resistance was felt.

Using Heister's mouth gag forcible mouth opening in the range of 40-45 mm was achieved (Figure 2) and a bite block was placed. The maxillary and mandibular third molars were extracted if any.

For the reconstruction of the defect in the buccal mucosa, the nasolabial flap was used in our study. Nasolabial flaps from the tip of nasolabial fold to corner of mouth were marked (Figure 3). The width of the flap was kept 1.5 to 2.5 cm. The medial incision line precisely followed the nasofacial folds on its inferior third. The medial and lateral limbs of incision tapered together, superiorly approximately 0.5 to 0.75 cms antero-inferiorly to medial canthus. The inferior limit of the flap was kept at the level of the oral commissure.

The flap was raised from superior to inferior in a supramuscular plane by using dissecting scissors (Figure 4).

At the region of the modiolus wherein the facial artery enters the skin, the pedicle was positioned. The transbuccal tunnel was made in the region of the modiolus just medial to the pedicle (Figure 5).

The flap was then transferred into the oral cavity in a tension free manner and inset onto the defect (Figure 6). Generous undermining of the donor site was performed in

the subcutaneous plane, and layered closure of the donor site was then performed with minimal tension (Figure 7). An attempt was made to minimally evert the margins along the nasofacial portion of the incision so as to achieve a slightly depressed scar once healing is completed, resulting in a more natural appearance.

From the 10th postoperative day physiotherapy (mouth opening exercises using wooden sticks) was started, with a frequency of four times a day with duration of half an hour, and later the frequency and duration was increased to further improve the mouth opening until values were reached that were achieved intraoperatively. At every follow-up visit our patients were evaluated for mouth opening postoperatively. The vascularity and viability of flap was evaluated using Pin prick test on the 1<sup>st</sup>, 7<sup>th</sup> and 21<sup>st</sup> post-operative days.

No relapse was encountered, even at the last follow-up (Figure 8).

### 3. Results

In our study, adequate mouth opening was achieved & maintained with minimum intraoral as well as extraoral scarring.

Healing was excellent without any of evidence of flap necrosis, flap loss, infection, obstructive sialadenitis or dehiscence. However, intra-oral hair growth was seen in our 7 patients, extra-oral scar at the donor site was seen in all our patients and salivary fistula formation was reported in 1 of the patient which underwent fistula repair later (Table 2).

The preoperative mouth opening in all the cases was less than 10 mm, with a mean of 5.5 mm. After release of fibrotic bands, a mean forced intraoperative mouth opening of 41.5 mm was achieved. Mean mouth opening of 37 mm was achieved at 6 months post-operatively (Table 3), with a mean increase of 31.5 mm. No relapse was encountered, even on the last follow-up appointment.

### 4. Discussion

A variety of surgical modalities have been used for the treatment of advanced oral submucous fibrosis. In order to achieve the results and maintain it for long term, fibrous bands should be completely released, followed by resurfacing the bilateral buccal defects with well-vascularised tissue.

A mucosal graft is an ideal graft to cover the oral mucosa, but is limited by the quantity of oral mucosa available for grafting.<sup>6</sup> Results with split-thickness skin grafting or fresh human amnion to cover the raw areas post fibrotomy have been disappointing, as the failure rate is high due to greater incidence of shrinkage, contracture, and rejection of graft encountered because of the poor oral conditions and subsequent recurrence of symptoms.<sup>9</sup> Tongue flaps, when used to cover the buccal defects in OSMF patients have disadvantages such

as postoperative dysphagia, disarticulation, the risk of postoperative aspiration and need for additional surgery for detachment of the pedicle.<sup>9</sup> The involvement of tongue in oral submucous fibrosis often precludes its use in treating the condition.<sup>9,10</sup>

The use of bilateral, small, bipaddled radial forearm flaps for reconstruction of bilateral buccal defects requires two flaps with two microsurgeries. Thus, the procedure is technique sensitive and time consuming.<sup>11</sup> The use of buccal fat pad to cover the defects after excision of the fibrous bands is easy to harvest but the anterior reach of the flap is often inadequate and cannot be used for larger defects.<sup>12</sup> Island palatal flaps again have limitation that they fail to reach posteriorly.<sup>11</sup> The use of nasolabial flaps in treatment of OSMF is more suitable for juxtaposed defects, in particular those of buccal mucosa, and is increasingly popular.

Intraorally placed, nasolabial flap provides 15 cm<sup>2</sup> of durable lining,<sup>13</sup> a mobile pedicle with sufficient blood supply, to be safely transposed. Deriving a dual blood supply from both, facial and ophthalmic arteries, the nasolabial flap is either superiorly or inferiorly based.<sup>14</sup> The inferior extension of the classic nasolabial flap usually extends inferiorly to an area lateral to the nasolabial fold, but it can be carried more inferiorly to the area of the oral commissure to provide a longer more versatile flap.<sup>14,15</sup>

The advantages of nasolabial flaps includes rich vascularity, versatility in design, close proximity to the defect, ease of flap elevation, supple skin, thus aiding in increasing mouth opening and causing minimal esthetic deformity, while the disadvantages being intraoral hair growth and occasional hypertrophic scar at the donor site. In our study we employed bilateral inferiorly based nasolabial flaps in all our 10 patients wherein, none of the flaps showed either bluish or whitish discoloration in the postoperative phase and no infection was encountered in any of our cases. Complications such as flap loss, flap avulsion, obstructive sialadenopathy or wound dehiscence were not encountered in our series. Intraoral hair growth was observed on the 3rd – 4th postoperative day, which was managed by regular trimming initially followed by epilation after 1½ months (Table 2).

The donor site healed uneventfully in all our cases, and no complication was noted. Although the scars were perceptible in all cases, they were readily accepted by the patients. Definite increase in mouth opening was observed over the first four post-operative weeks, three months and at six months period (Table 3). A mean increase in mouth opening at the 4th postoperative week was 34.2 mm, at 3 months was 36.2 mm and by the end of 6 months, an increase up to 37 mm was noted. The results obtained in our series were satisfactory permitting us to conclude that the bilateral inferiorly based nasolabial flap is an efficacious, viable and reliable option for reconstruction of oral cavity

defects post fibrotomy in oral submucous fibrosis patients.

## 5. Source of Funding

None.

## 6. Conflict of Interest

None.

## References

1. Kavarana NM, Bhathena H. Surgery for severe trismus in submucous fibrosis. *Br J Plast Surg.* 1987;40(4):407-47.
2. Rananjaneyulu P, Rao P. Submucous fibrosis - New treatment. *J Indian Dent Assoc.* 1980;52(1):379-80.
3. Cox SC, Walker D. Oral submucous fibrosis. A review. *Australian Dental J.* 1996;41(5):294-303.
4. Gnanam A, Kannadasan K, Venkatachalapathy S, David J. Multimodal treatment options for oral submucous fibrosis. *SRM Univ J Dent Sci.* 2010;1(1):26-9.
5. Canniff JP, Harvey W, Harris M. Oral submucous fibrosis: its pathogenesis and management. *Br Dent J.* 1986;160(12):429-34.
6. Maria A, Sharma Y, Kaur P. Use of Nasolabial Flap in the Management of Oral Submucous Fibrosis - A Clinical Study. *People's J Sci Res.* 2011;4(1):28-30.
7. Hynes B, Boyd JB. The nasolabial flap - Axial or Random. *Arch Otolaryngol Head Neck Surg.* 1988;114(21):1389-91.
8. Borle RM, Nimonkar PV, Rajan R. Extended nasolabial flaps in the management of oral submucous fibrosis. *Br J Oral Maxillofac Surg.* 2009;47(5):382-7.
9. Khanna JN, Andrade NN. Oral submucous fibrosis: a new concept in surgical management - Report of 100 cases. *Int J Oral Maxillofac Surg.* 1995;24(6):433-9.
10. Borle RM, Borle SR. Management of oral submucous fibrosis: A conservative Approach. *J Oral Maxillofac Surg.* 1991;49(8):788-91.
11. Lee JT, Cheng LF, Chen PR. Bipaddled radial forearm flap for the reconstruction of bilateral buccal defects in oral submucous fibrosis. *Int J Oral Maxillofac Surg.* 2007;36(1):615-9.
12. Paissat DK. Oral submucous fibrosis. *Int J Oral Surg.* 1981;10(5):307-12.
13. Morgan RF, Chambers RG, Jaques DA, Hoopes JE. Nasolabial flap in intraoral reconstruction - Review of 55 cases. *Am J Surg.* 1981;142(4):448-50.
14. Gewirtz HS, Eilber FR, Zream H. Use of nasolabial flap for reconstruction of the floor of the mouth. *Am J Surg.* 1978;136:508-11.
15. Balaji SM. Versatility of nasolabial flaps for management of severe trismus in oral submucous fibrosis. *Indian J Dent Res.* 2016;27(5):492-9.

## Author biography

**Mugdha Milind Parkhi**, PG Student

**K.C. Gupta**, Dean and Head

**Ashish Fanan**, Consultant

**Cite this article:** Parkhi MM, Gupta KC, Fanan A. The efficacy of nasolabial flap as a reconstruction modality in the surgical management of oral submucous fibrosis. *IP Indian J Anat Surg Head, Neck Brain* 2022;8(3):92-97.