

Content available at: <https://www.ipinnovative.com/open-access-journals>

IP Archives of Cytology and Histopathology Research

Journal homepage: <https://www.achr.co.in/>

## Case Report

# Renal replacement lipomatosis with granulomatous inflammation – A case report and review of literature

Veena R<sup>1,\*</sup>, Sowmya B M<sup>1</sup>, Gowri Prabhu<sup>1</sup>, Varendra G Kulkarni<sup>1</sup>

<sup>1</sup>Dept. of Pathology, J.J.M Medical College, Davangere, Karnataka, India



### ARTICLE INFO

#### Article history:

Received 15-05-2022

Accepted 03-06-2022

Available online 23-09-2022

#### Keywords:

Lipomatosis

Renal

Granuloma

### ABSTRACT

**Background:** Renal replacement lipomatosis can be defined as the proliferation of fibrofatty tissue which subsequently replace the renal parenchyma. It is usually benign unilateral and occurs as a result of severe atrophy or destruction of the renal parenchyma, due to a calculus with secondary proliferation of renal sinus, renal hilus, and perirenal fatty tissue to a variable extent.

**Case Report:** A 55yr old female presented to surgeon with history of pain and swelling in right flank. On CECT abdomen there was seen non functional right kidney with staghorn calculi along with perirenal abscess. Patient was treated with nephrectomy and drainage of collection. Intraoperatively Perirenal Abscess extending to psoas and iliopsoas region along with dense adhesion between kidney and liver was found. The multiple sections studied from the lesion showed extensive fibrofatty tissue with few tubule like structures lined by cuboidal epithelium and containing dense eosinophilic secretions. There is seen mixed inflammatory infiltrates with granulomas. Histological features confirmed that Renal replacement lipomatosis with granulomatous inflammation.

**Conclusion:** The clinical importance of RRL is that it stimulates fat-containing tumors in the kidney or its vicinity such as lipomas, angiomyolipomas and liposarcomas can be misdiagnosed preoperatively. Hence this case report has been presented to create awareness of this condition among the pathologist and practicing urologists.

This is an Open Access (OA) journal, and articles are distributed under the terms of the [Creative Commons Attribution-NonCommercial-ShareAlike 4.0 License](https://creativecommons.org/licenses/by-nc-sa/4.0/), which allows others to remix, tweak, and build upon the work non-commercially, as long as appropriate credit is given and the new creations are licensed under the identical terms.

For reprints contact: [reprint@ipinnovative.com](mailto:reprint@ipinnovative.com)

## 1. Introduction

Renal replacement lipomatosis (RRL) is a rare and benign condition characterized by proliferation of renal sinus/hilar and perirenal fatty tissue with marked atrophy of the renal parenchyma. It is seen with calculus disease in 70% of cases and associated with chronic inflammation and hydronephrosis.<sup>1-4</sup>

## 2. Case Report

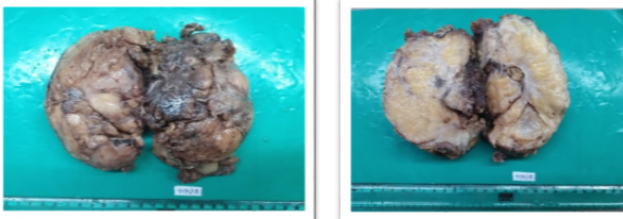
A 55yr old female presented to surgeon with history of pain and swelling in right flank since 6 months. No history of

fever, hematuria. On CECT abdomen there was seen non-functional right kidney with staghorn calculi along with perirenal abscess. Patient was treated with nephrectomy and intraoperatively there was seen perirenal abscess and there was a frank pus extending to psoas iliopsoas region and there was a dense adhesion between the kidney and the liver. The specimen was sent for histopathological examination.

Grossly; the specimen measured around 14\* 10\* 9cm intact Gerota's fascia, irregular nodular external surface and fibro-fatty tissue attached on the kidney along with organized exudates at the hilar surface was noted ureter was not appreciable. Cut surface appeared yellowish with lot of fatty tissue deposition. There was complete loss of renal architecture, and also seen calculi measuring 1X1cm.

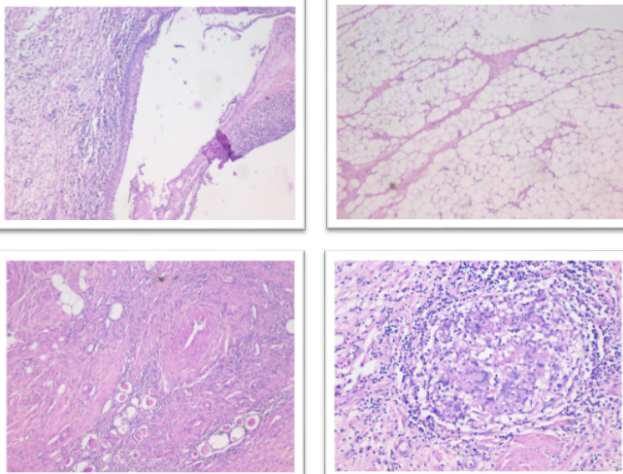
\* Corresponding author.

E-mail address: [veenatalakerappa@gmail.com](mailto:veenatalakerappa@gmail.com) (Veena R).



**Fig. 1:** Fibro-fatty tissue attached on the kidney

Microscopically; Multiple sections studied from the mass showed extensive fibrofatty tissue with few tubule like structures lined by cuboidal epithelium and containing eosinophilic secretions. There is seen dense mixed inflammatory infiltrates with few granulomas composed of epithelioid histiocytes, extensive necrosis and multinucleated giant cells. No glomeruli made out in the section studied. Histopathology of the tissue confirmed the diagnosis renal replacement lipomatosis.



**Fig. 2:** Extensive necrosis and multinucleated giant cells

### 3. Discussion

Renal replacement lipomatosis (RRL) also known as fibrolipomatosis is an uncommon condition, which occurs secondary to atrophy or destruction of renal parenchyma by chronic inflammation. RRL is most commonly seen in association with calculus disease (in >70% patients), however it can be associated with other chronic inflammatory pathologies such as chronic pyelonephritis, renal tuberculosis and transplant patients.<sup>1,2</sup>

The mildest form of renal lipomatosis is usually seen in the sixth and seventh decade associated with obesity, atherosclerosis or use of exogenous steroids, and it has no clinical significance.<sup>4</sup>

Danza FM et al. reported their experience with 18 cases of replacement lipomatosis: 6 patients had the massive

form, one of them bilateral, 5 patients had associated xanthogranulomatous pyelonephritis and 7 had an initial focal form. They speculated that the cause of this abnormal fatty proliferation is related to peculiar individual reactivity and not only the obstruction and chronic infection.<sup>5</sup>

The main differential considerations for RRL include malakoplakia, fat containing tumors such as liposarcomas, lipomas, and angiomyolipomas, xanthogranulomatous pyelonephritis and transitional carcinoma of the renal sinus.<sup>6</sup>

Patients usually present with complaints of recurrent flank pain, fever, weight loss and mass per abdomen. Usually its unilateral and Hydronephrosis with chronic infection leading to parenchymal atrophy.<sup>7</sup>

The radiological investigations which are helpful in diagnosing RRL includes ultrasound (US) Computed tomography(CT) Magnetic resonance imaging(MRI) and recently MR urography with gadolinium contrast have come up as the most accurate diagnostic tools for replacement lipomatosis showing the presence of perirenal fat intensity signal, obstruction, dilated ureter, level of obstruction, and atrophic kidney.<sup>5</sup>

Resulting from long standing obstruction or stone disease which are potential sites for infections. In Simple nephrectomy, the kidney is dissected free through the convenient plane between the capsule and its fatty coverings. If plane is obscured by adhesions and scarring then subcapsular dissection is done.

#### 3.1. Histologically

Renal replacement lipomatosis and xanthogranulomatous pyelonephritis may mimic each other as well as can coexist in same patient. Renal replacement lipomatosis shows increased mature adipose tissue content in renal sinus and perirenal tissues with very few glomeruli and thyroidised tubules. While xanthogranulomatous pyelonephritis is characterized by infiltration of lipid-loaded inflammatory foam cells in the renal parenchyma. The absence of Xanthoma cells confirms the diagnosis in favor of renal replacement lipomatosis.

### 4. Conclusion

The clinical importance of RRL is that it stimulates fat-containing tumors in the kidney or its vicinity such as lipomas, angiomyolipomas and liposarcomas can be misdiagnosed preoperatively. Hence this case report has been presented to create awareness of this condition among the pathologist and practicing urologists.

### 5. Conflict of Interest

The authors declare no relevant conflicts of interest.

## 6. Source of Funding


None.

## References


1. Choh NA, Jehangir M, Choh SA. Renal replacement lipomatosis: A rare type of renal pseudotumor. *Indian J Nephrol.* 2010;20(2):92–3. doi:10.4103/0971-4065.65303.
2. Nathani S, Singh K, Mehta P. Renal Replacement Lipomatosis with Psoas Abscess Mimicking as Xanthogranulomatous Pyelonephritis. *Med Sur Urol.* 2018;7(3):204. doi:10.4172/2168-9857.1000204.
3. Metin MR, Ikiz S. The Evaluation of Renal Replacement Lipomatosis with Computerized Tomography and Magnetic Resonance Imaging Findings: A Case Report. *J Med Diagn Meth.* 2017;6:262. doi:10.4172/2168-9784.1000262.
4. Yaseen HA, Rashed AO. Renal Lipomatosis. *J Sulaimani Med Coll.* 2015;5(2):161–5.
5. Khan M, Nazir SS, Ahangar S, Qadri SF, Salroo NA. Total Renal Replacement Lipomatosis. *Int J Surg.* 2010;8(4):263–5. doi:10.1016/j.ijssu.2010.02.009.
6. Xu Y, Liu RL, Zhang ZH, Zhao WM, Yang QC. Renal Replacement Lipomatosis. *Eur Surg Res.* 2006;38(4):385–7. doi:10.1159/000094534.


7. Gowri M, Jyothi B, Anunayi J. Renal Replacement Lipomatosis - a case report. *J Evid Based Med Healthc.* 2019;6(6):397–9.

## Author biography

**Veena R**, Post Graduate  <https://orcid.org/0000-0002-1044-4962>

**Sowmya B M**, Assistant Professor  <https://orcid.org/0000-0003-2201-2451>

**Gowri Prabhu**, Post Graduate  <https://orcid.org/0000-0002-6151-0210>

**Varendra G Kulkarni**, Professor and HOD  <https://orcid.org/0000-0003-2904-1423>

**Cite this article:** Veena R, Sowmya B M, Prabhu G, Kulkarni VG. Renal replacement lipomatosis with granulomatous inflammation – A case report and review of literature. *IP Arch Cytol Histopathology Res* 2022;7(3):208-210.