

Content available at: <https://www.ipinnovative.com/open-access-journals>

IP Archives of Cytology and Histopathology Research

Journal homepage: <https://www.achr.co.in/>

## Case Report

# The worst of both worlds - carcinosarcoma of the ovary: A case report

Sri Devi R<sup>1,\*</sup>, Shruthi Kareddy<sup>2</sup>, Soumya B M<sup>1</sup>, Vardendra Kulkarni<sup>1</sup>

<sup>1</sup>Dept. of Pathology, JJM Medical College, Davangere, Karnataka, India

<sup>2</sup>Dept. of Pathology, Bangalore Medical College and Research Institute, Bangalore, Karnataka, India



### ARTICLE INFO

#### Article history:

Received 12-08-2022

Accepted 28-10-2022

Available online 30-11-2022

#### Keywords:

Ovarian carcinosarcoma

Tumour

### ABSTRACT

Ovarian carcinosarcoma (OCS) is a rare, highly aggressive neoplasm characterized by presence of both carcinomatous and sarcomatous component. Even after evolution of chemotherapy with introduction of platinum agents, the survival still seems to be poor. A report of such rare case tumour in a 62 year old female is presented here.

This is an Open Access (OA) journal, and articles are distributed under the terms of the [Creative Commons Attribution-NonCommercial-ShareAlike 4.0 License](https://creativecommons.org/licenses/by-nc-sa/4.0/), which allows others to remix, tweak, and build upon the work non-commercially, as long as appropriate credit is given and the new creations are licensed under the identical terms.

For reprints contact: [reprint@ipinnovative.com](mailto:reprint@ipinnovative.com)

## 1. Introduction

Ovarian cancer causes more deaths per year than any other cancer of the female reproductive system. Carcinosarcoma of the ovary is a rare, highly aggressive neoplasm characterized by the presence of both carcinomatous and sarcomatous components. It is also called as malignant mixed mesodermal tumors [MMMTs], malignant mixed mullerian tumors or sarcomatoid carcinomas. It accounts for <1% of all ovarian tumours. Even after evolution of chemotherapy with introduction of platinum agents, the survival still seems to be poor and hence data regarding an optimal regimen and its impact on patient's survival remains inconclusive.<sup>1,2</sup>

## 2. Case Report

A 62 year old female came with history of bleeding per vagina and fullness over abdomen since 20 days. On complete examination she was poorly built and nourished with a palpable mass in the lower abdomen. CECT showed a right ovarian solid cystic necrotic mass occupying the whole of pelvis. She underwent a total abdominal hysterectomy

with partial omentectomy. The left adnexa showed an irregularly enlarged ovarian mass measuring 13x7x5cm. Cut surface was solid and cystic with areas of haemorrhage and necrosis. Serous fluid was drained out.

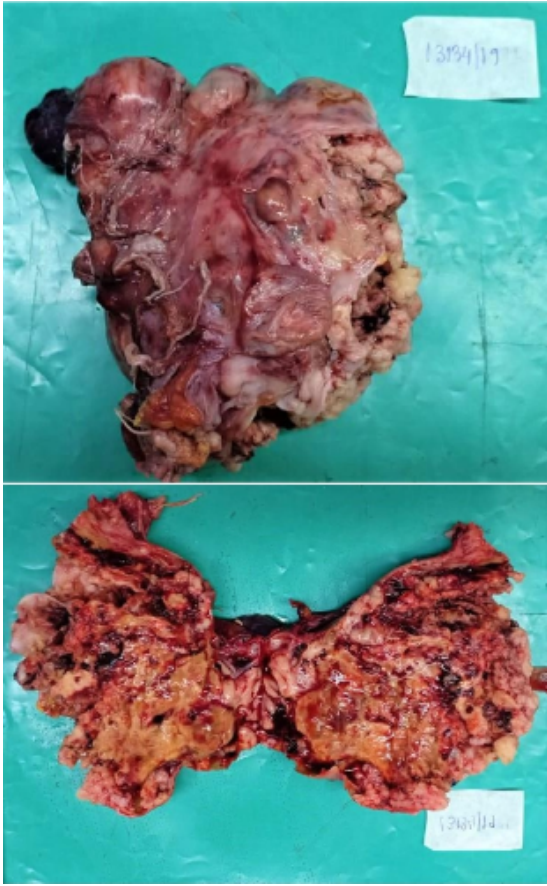
Histological examination showed a high grade biphasic neoplastic lesion composed of an admixture of epithelial and mesenchymal elements. Epithelial element showed high grade undifferentiated tumor cells arranged in sheets, trabeculae and cords exhibiting moderate pleomorphism, ill-defined cytoplasmic borders, vesicular nuclei with finely dispersed chromatin. Focally glandular differentiation was made out. 5-6mitoses/HPF seen. Mesenchymal component in the form of atypical sarcomatous spindle shaped cells along with heterologous differentiation towards cartilage was made out. Cartilage showed high cellularity and cytological atypia. Multinucleate giant cells were seen. Areas of necrosis and haemorrhage present. No vascular invasion noted.

Cell block study for Ascitic fluid was positive for malignancy although omentum sent for HP examination did not show any macroscopic or microscopic deposits.

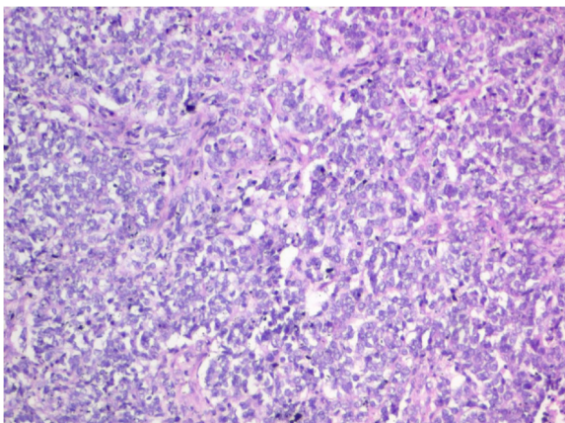
So the final diagnosis of FIGO stage III- Carcinosarcoma of ovary with heterologous element was made. Patient did not receive any chemotherapy despite being advised yet the

\* Corresponding author.

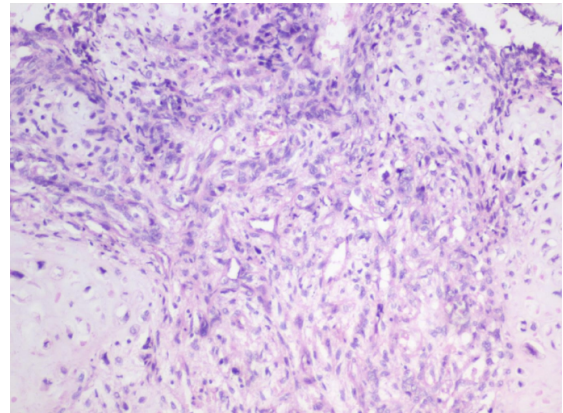
E-mail address: [sridevi.vrg@gmail.com](mailto:sridevi.vrg@gmail.com) (Sri Devi R).



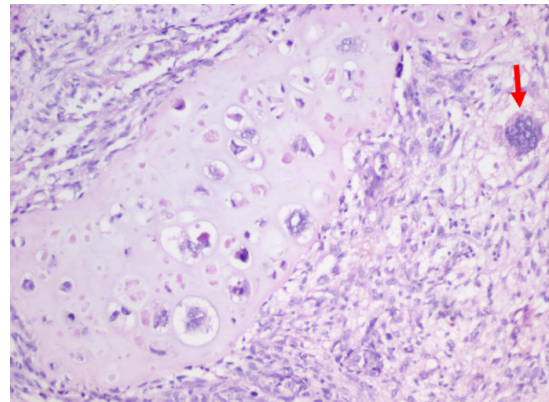
**Fig. 1:** Irragular ovarian mass with heterogenous area on cut surface



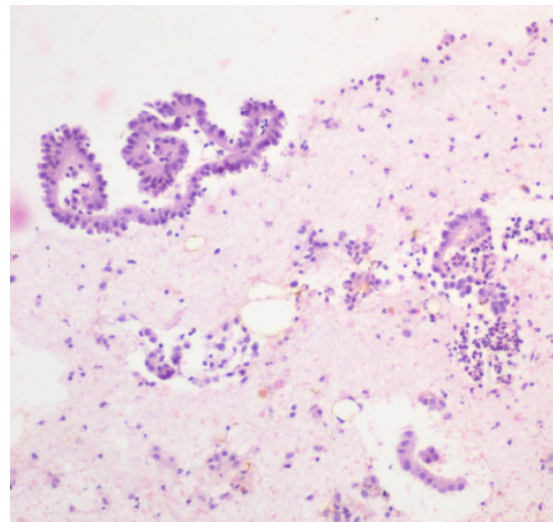
**Fig. 2:** Epithelial component showing undifferentiated cell in sheets and trabecular (Hand E & 40x).



**Fig. 3:** Mesenchymal component showing atypical spindle cells with areas of cartilaginous differentiation (Hand E, 40x).



**Fig. 4:** Heterologous cartilaginous differentiation showing atypia; Multinucleate giant cell (arrow) (Hand E, 40X).



**Fig. 5:** Cell block preparation showing atypical malignant cells in clusters and trabeculae. (H & E, 40x).

patient was keeping well 10 months post-surgery.

### 3. Discussion

Carcinosarcomas are tumours usually arising from the uterus. Their occurrence in the ovary is a rarity.<sup>3</sup> The pathogenesis of carcinosarcomas remains under debate but immunologic studies and molecular studies have suggested that three main theories: 1) The collision theory- where the two tumour types collide and exist as two independent tumours. 2) The combination theory- where the two components arise from a common stem cell precursor. 3) The conversion theory- where the sarcomatous element arises from the carcinomatous element during the tumour evolution.<sup>4</sup> It usually presents in elderly postmenopausal women. Symptoms include pelvic/ abdominal pain, early satiety, bloating, abdominal distension and other GI complaints.

Patients' performance status at presentation is usually worse. They present in the advanced disease stage and these patients have a grim prognosis with median survival rate of 17-27 months. After reviewing the prognostic factors patients with heterologous components said to have worse prognosis. But this no longer holds good. Also, other histologic features like mitotic index, grade of the tumour are no longer associated with the ability to predict metastasis. However, some studies have shown that the tumour's epithelial elements may have predictive outcome.<sup>5</sup> Usually FIGO stage I and II have good prognosis while stage III and IV have worse prognosis owing to the suboptimal debulking of the tumor during surgery.<sup>6</sup> So the residual disease following surgery is an important prognostic factor which can be analysed by follow-up CA-125 levels. IHC can be used to identify the biphasic population but the studies on overexpression of p53 and Ki67 index as prognostic indicators has not yet shown statistically significant results.<sup>7,8</sup>

### 4. Conclusion

Owing to its poor prognosis, early diagnosis whenever possible, optimal debulking of the tumor during surgery and follow up of the patient for residual disease becomes important. Despite the aggressive treatment of surgery and chemotherapy it carries a significantly increased risk of death. The risk, rarity, prognosis of this tumor emphasises the need for collaborative, prospective studies targeted to better understand the molecular changes and the need

to design better treatment regimens to improve patient's survival.

### 5. Source of Funding

None.

### 6. Conflicts of Interest

There is no conflict of interest.

### References

1. Brown E, Stewart M, Rye T, Al-Nafussi A, Williams ARW, Bradburn M, et al. Carcinosarcoma of the ovary: 19 years of prospective data from a single center. *Cancer*. 2004;100(10):148–53.
2. Montalvo-Esquivel G, Chanona-Vilchis JG, Herrera-Gómez A, Meneses-García AA, Isla-Ortiz D. Primary ovarian carcinosarcoma. Report of eight cases. *Ginecol Obstet Mex*. 2014;82(7):483–9.
3. Priyadarshini P, Majumdar SK, Prida DK. Carcinosarcoma of ovary with long-term overall survival. *Oncol J India*. 2019;3(2):41–4. doi:10.4103/oji.oji\_32\_19.
4. Carmen MGD, Birrer M, Schorge JO. Carcinosarcoma of the ovary: A review of the literature. *Gynecologic Oncology*. 2012;125:271–277.
5. Ariyoshi K, Kawachi S, Kaku T, Nakano H, Tsuneyoshi M, I, . . . . Prognostic factors in ovarian carcinosarcoma: a clinicopathological and immunohistochemical analysis of 23 cases. *Histopathology*. 2007;37(5):427–36. doi:10.1046/j.1365-2559.2000.01015.x.
6. Harris MA, Delap LM, Sengupta PS, Wilkinson PM, Welch RS, Swindell R, et al. Carcinosarcoma of the ovary. *Br J Cancer*. 2003;88(5):654–7. doi:10.1038/sj.bjc.6600770.
7. Barnholtz-Sloan JS, Morris R, Malone JM, Munkarab AR. Survival of women diagnosed with malignant, mixed mullerian tumors of the ovary (OMMMT). *Gynecol Oncol*. 2004;93(2):506–12. doi:10.1016/j.ygyno.2004.02.016.
8. Dasgupta S, Bose D, Bhattacharyya NK, Biswas PK, Pranab Kumar Biswas. Carcinosarcoma of ovary with its various immunohistochemical expression: Report of a rare case. *J Can Res*. 2015;11(4):1022. doi:10.4103/0973-1482.147390.

### Author biography

Sri Devi R, Post Graduate  <https://orcid.org/0000-0003-3351-7471>

Shruthi Kareddy, Senior Resident

Soumya B M, Assistant Professor

Vardendra Kulkarni, Professor and Head

**Cite this article:** Sri Devi R, Kareddy S, Soumya B M, Kulkarni V. The worst of both worlds - carcinosarcoma of the ovary: A case report. *IP Arch Cytol Histopathology Res* 2022;7(4):270-272.