



Case Report

Primary intravascular large B cell lymphoma of prostate-A diagnostic dilemma

Lakshmi Agarwal^{1,*}, Sanjay Gandhi², Manmohan³

¹Government Medical College, Kota, Rajasthan, India

²Binali complex, Ahmedabad, Gujarat, India

³Pushpadi Cancer Care Center, Kota, Rajasthan, India



ARTICLE INFO

Article history:

Received 11-07-2022

Accepted 09-08-2022

Available online 30-11-2022

Keywords:

Lymphoma

Rare

Intravascular

Biopsy

ABSTRACT

Intravascular large B cell lymphoma is a very rare neoplasm of prostate. It is important to identify this entity and differentiate this from prostatic adenocarcinoma as treatment is different. Here we present a rare case of primary intravascular large B cell lymphoma of the prostate.

This is an Open Access (OA) journal, and articles are distributed under the terms of the [Creative Commons Attribution-NonCommercial-ShareAlike 4.0 License](https://creativecommons.org/licenses/by-nc-sa/4.0/), which allows others to remix, tweak, and build upon the work non-commercially, as long as appropriate credit is given and the new creations are licensed under the identical terms.

For reprints contact: reprint@ipinnovative.com

1. Introduction

Intravascular large B cell lymphoma (IVLBCL) is a very rare distinct entity of diffuse large B cell lymphoma (DLBCL). It is also known as intravascular lymphomatosis or Angiotropic lymphoma.¹ It is a high-grade lymphoma arising from the peripheral mature B cells. It commonly affects the older age group and may involve any tissue and organ. CNS, skin, kidney, lungs, adrenal gland and bone marrow are most commonly affected. It is characterised by presence of lymphoma cells within the lumina of small to medium sized blood vessels. The aetiology of this tumour is unknown.

The involvement of prostate by IVLBCL as primary organ is very rare and accounts for 0.09% of all prostatic cancer.^{1,2} Only a few cases have been reported till date. Hence, we report a case of primary prostate IVLCL.

2. Case Report

A 60-year-old male presented with a history of voiding symptoms. There was no history of fever or weight loss and neurological symptoms. The peripheral lymph nodes were not enlarged on physical examination. Digital rectal examination revealed enlargement of the prostate and his prostate specific antigen level was 4.31ng/ml. A complete blood count showed anaemia, with a haemoglobin level of 8.2g/dl. Total leukocytes counts and platelets were within normal limits. There were no abnormal cells seen. Liver and renal function test were normal. Lactate dehydrogenase was increased-900IU/L. HIV test was negative. Chest X-ray, sonography of abdomen showed normal findings. Ultrasonography of pelvis revealed enlarged prostate measuring 3.5x3x3 cm. Trans-urethral resection of the patient's prostate was performed.

The entire resected prostate chips were processed. Paraffin blocks were made and slides were stained with haematoxylin and eosin stain. Section revealed large lymphoid cells within the lumina of blood vessels. These cells form cohesive clusters admixed with fibrin. The cells resemble centroblast. The surroundings stroma,

* Corresponding author.

E-mail address: drLaxmiagarwal@gmail.com (L. Agarwal).

acinar and glandular structures were benign. [Figure 1] Immunohistochemistry staining was done. The malignant cells were found to be positive for CD45, Cd20 and negative for cytokeratin and CD3. Ki-67 proliferation index was 60%. The CD34 staining was positive in endothelial cells, highlighting the intravascular nature of the malignant cells. [Figure2]. On the basis of the above findings the final diagnosis of intravascular large B cell lymphoma of prostate was rendered. PET scan was done and tumor was found to be confined within the prostate. Chemotherapy was planned followed by radiation to the prostate. After the completion of treatment, followed up CT scan revealed complete remission.

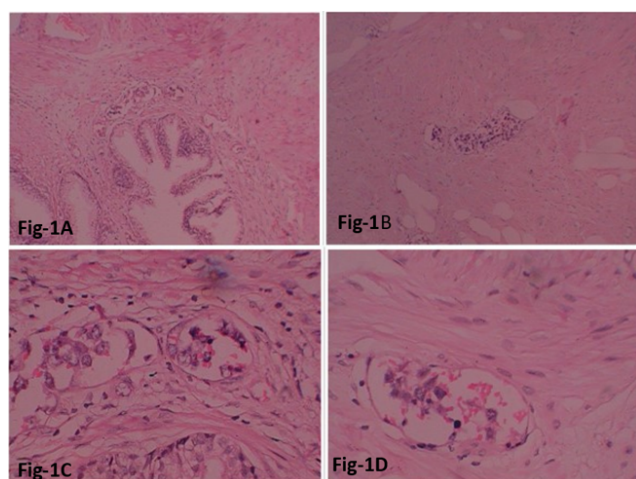


Fig. 1: Microscopic examination, H&E stain: **A** : showing normal gland and parenchyma (20X). **B**: malignant cells within the lumen of vessels (10X). **C, D**-Showing malignant lymphoid cells having scant cytoplasm, prominent nucleoli within the lumen of vessels (40X).

3. Discussion

Intravascular large cell lymphoma is a rare and high-grade B cell lymphoma. It commonly affects the older age group, median age 67 years. The etiology is unknown. It can involve any organ or tissue- CNS, skin, kidney, lung are the most common sites. The clinical symptoms are varied and nonspecific. The most commonly include fever, hepato-splenomegaly, anaemia, thrombocytopenia and disseminated intravascular coagulation. Patients usually lack lymphadenopathy and rarely involve the bone marrow and peripheral blood.²⁻⁴ Ferreri et al. in the study of a series of 38 patients, reported anemia in nearly 65% of patients, increased LDH and β 2 microglobulin levels in more than 80% of patients, and an elevated ESR in 14% of patients.² In the present study, the patient has anemia only and there were no other complaints.

The primary intravascular lymphoma of prostate is very rare and only a few of the cases has been reported. Various

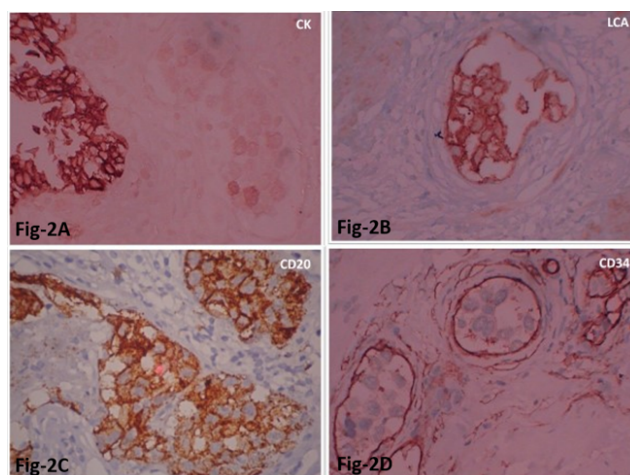


Fig. 2: Immunohistochemistry: Tumor cells are negative for cytokeratin; **A**: But positive for LCA; **B**: CD20 is positive; **C**: The endothelial cells are positive for CD34 showing the intravascular nature of malignant cells (**D**).

definition has been used to classify the lymphomas as primary. In a study done by Bostwick DG et al, 35% of the prostate lymphoma were found to be primary. They used the following criteria to identify primary prostatic lymphomas: (i) Presenting symptoms attributable to prostatic enlargement; (ii) involvement of prostate predominantly, with or without involvement of adjacent tissue; and (iii) absence of involvement of liver, spleen, or lymph nodes within 1 month of diagnosis of prostatic involvement.^{5,6}

Due to rarity of the disease and non-specific symptoms, it is difficult to diagnose. However, it should be considered in differential diagnosis for elderly patients with enlarged prostate. The PSA level is generally within normal limits but may be increased in some cases. They generally present with lower urinary tract problems like urinary frequency, urgency, hematuria, or acute retention. Due to these findings, it is mistaken as benign prostate hyperplasia or prostatitis. The elevated LDH levels, fever of unknown origin, and unexplained neurological symptoms in elderly patients should raise the suspicion of lymphoma.^{4,6-8} It should be differentiated from adenocarcinoma of prostate and secondary metastasis as the treatment protocol varies. Biopsy and immunohistochemical assessment are the gold standard for the diagnosis. Adenocarcinoma involves the glands and adjacent parenchyma. It is positive for cytokeratin. The malignant cells are present within the lumen of the vessels in large cell intravascular lymphoma and is positive for LCA. The glands and parenchyma are not involved.

As the therapeutic strategy differs, early diagnosis can result in a better outcome of the patient.

Due to a few numbers of cases reported in the literature, there is no consensus for the standard treatment protocol. The chemotherapy of R-CHOP with or without radiotherapy remains the currently recommended therapy for IVLBCL according to the available data⁹ and NCCN practice guideline of DLBCL. Further research is required to improve the understanding of the pathogenesis and biology of this rare type of lymphoma.

4. Source of Funding

None.

5. Conflicts of Interest

There is no conflict of interest.

References

1. Sarris A, Dimopoulos M, Pugh W, Cabanillas F. Primary lymphoma of the prostate: Good outcome with doxorubicin-based combination chemotherapy. *J Urol*. 1995;153(6):1852–4. doi:10.1016/s0022-5347(01)67330-0.
2. Ferreri AJ, Campo E, Seymour JF, Willemze R, Ilariucci F. Intravascular lymphoma: clinical presentation, natural history, management and prognostic factors in a series of 38 cases, with special emphasis on the 'cutaneous variant'. *Br J Haematol*. 2004;127(2):173–83. doi:10.1111/j.1365-2141.2004.05177.x.
3. Shimada K, Kinoshita T, Naoe T, Nakamura S. Presentation and management of intravascular large B-cell lymphoma. *Lancet Oncol*. 2009;10(9):895–902. doi:10.1016/S1470-2045(09)70140-8.
4. Quintini G, Barbera V, Franco V, Florena AM, Spadola V, Mariani G, et al. Uncommon presentations of non-Hodgkin's lymphoma: case 1. Intravascular large B-cell lymphoma: diagnosis on prostate biopsy. *J Clin Oncol*. 2003;21(3):564–9.
5. Bostwick DG, Iczkowski KA, Amin MB, Discigil G, Osborne B. Malignant lymphoma involving the prostate: Report of 62 cases. *Cancer*. 1998;83(4):732–8. doi:10.1002/(sici)1097-0142(19980815)83:4<732::aid-cnecr15>3.0.co;2-t.
6. Kakkur A, Rajeshwari M, Bhethanabhotla S, Kaur K, Jain D, Gogia A, et al. Primary diffuse large B-cell lymphoma of the prostate: A report of two cases with diagnostic considerations. *J Cancer Res Ther*. 2015;11(4):977–9. doi:10.4103/0973-1482.176122.
7. Pusch G, Feher G, Szomor A, Kover F, Gomori E, Illes Z, et al. Intravascular lymphoma presenting with neurological signs but diagnosed by prostate biopsy: suspicion as a key to early diagnosis. *Eur J Neurol*. 2009;16(3):39–41. doi:10.1111/j.1468-1331.2008.02382.x.
8. Özsan N, Sarsık B, Yılmaz AF, Şimşir A, Dönmez A. Intravascular Large B-Cell Lymphoma Diagnosed on Prostate Biopsy: A Case Report. *Turk J Haematol*. 2014;31(4):403–7. doi:10.4274/tjh.2013.0090.
9. Shimada K, Matsue K, Yamamoto K. Retrospective analysis of intravascular large B-cell lymphoma treated with rituximab-containing chemotherapy as reported by the IVL study group in Japan. *J Clin Oncol*. 2008;26(19):3189–95. doi:10.1200/JCO.2007.15.4278.

Author biography

Lakshmi Agarwal, Assistant Professor

Sanjay Gandhi, Consultant Pathologist

Manmohan, Consultant Oncosurgeon

Cite this article: Agarwal L, Gandhi S, Manmohan. Primary intravascular large B cell lymphoma of prostate-A diagnostic dilemma. *IP Arch Cytol Histopathology Res* 2022;7(4):241-243.