

Content available at: <https://www.ipinnovative.com/open-access-journals>

IP Archives of Cytology and Histopathology Research

Journal homepage: <https://www.achr.co.in/>

## Case Report

# Tonsillar Actinomycosis with presence of Epidermal inclusion cyst: Report of a rare entity

Punam Prasad Bhadani<sup>1,\*</sup>, Sneha Aditi<sup>1</sup>, Avinash Singh<sup>1</sup>, Nisha<sup>1</sup>

<sup>1</sup>Dept. of Pathology, All India Institute of Medical Sciences, Patna, Bihar, India



### ARTICLE INFO

#### Article history:

Received 14-10-2021

Accepted 25-10-2021

Available online 02-12-2021

#### Keywords:

IAC Yokohama

Breast FNA

Histopathological correlation

Risk of Malignancy

p-value

### ABSTRACT

Epidermal inclusion cysts (EIC) are benign lesions that can be encountered throughout the body, but with a low incidence in the head and neck region. (1.6 to 7%) The various locations in this region where the cyst can arise are sublingual, submental, submandibular and buccal mucosa. EIC present in the tonsils are extremely rare and reported less than 0.01% in published English literature. We report a rare and incidental finding of epidermal inclusion cyst with actinomycetes in tonsil in a 57 year old male who presented with sore throat and difficulty in swallowing.

This is an Open Access (OA) journal, and articles are distributed under the terms of the [Creative Commons Attribution-NonCommercial-ShareAlike 4.0 License](#), which allows others to remix, tweak, and build upon the work non-commercially, as long as appropriate credit is given and the new creations are licensed under the identical terms.

For reprints contact: [reprint@ipinnovative.com](mailto:reprint@ipinnovative.com)

## 1. Introduction

Epidermal inclusion cysts (EIC) are practically the same as epidermoid cysts, epithelial cyst, keratinous cyst, sebaceous cyst, milia, squamous inclusion cyst or the infundibular cyst. Epidermal inclusion cysts are benign lesions which can be developmental or acquired. In 1859, Rosen gave the term of epidermal cyst. EIC can be developed during the fetal period from abnormal epithelial components of ectodermal tissue or they may arise after trauma or surgery due to implanted epithelium.<sup>1-3</sup> EIC can occur in any part of the body, with approximately 1.6-6.9% of cases in the head and neck area. In oral cavity, the most common affected site is floor of the mouth, but tonsillar location remains extremely rare (less than 0.01%).<sup>2</sup> Treatment of EIC of the head and neck is surgical and also depends on the localization and the size of the lesion. Histopathological examination is of utmost importance in every resected tonsil to differentiate benign inclusion cysts from tonsillar squamous cell carcinomas.<sup>3,4</sup>

Hereby, we report a case of epidermal inclusion cyst in the tonsil which was encountered as an incidental finding

along with the presence of actinomycetes, with an emphasis on histopathological examination of resected tonsil.

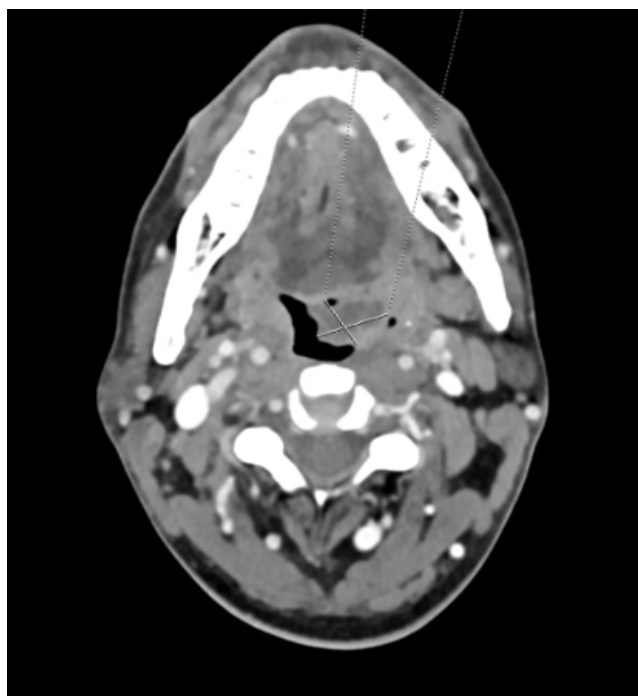
## 2. Case Report

A 57 year old male patient came to an outpatient department of otorhinolaryngology with complaint of on and off sore throat and difficulty in swallowing. Local examination revealed hypertrophied and congested bilateral tonsil, more prominent on left side. Few enlarged cervical lymph nodes were also observed. Clinical diagnosis of chronic tonsillitis was suspected. CECT neck was done which showed mild bulky enhancing lesion with small hypodense cystic area inside the left tonsillar region measuring 2.1 x 1.5 x 1.9 cm. (Figure 1)

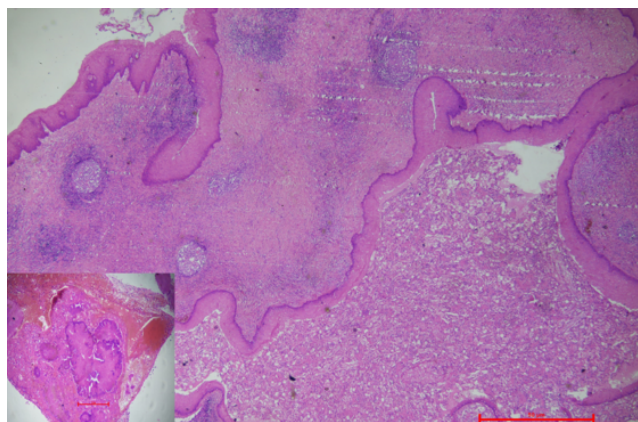
The patient underwent bilateral tonsillectomy. The excised specimen was sent for histopathological examination. Left tonsillectomy specimen measured 5.7 x 2.5 x 0.4 cm. Right tonsillectomy specimen was unremarkable. Microscopy of left tonsil showed irregularly intact dilated cystic cavity below the normal tonsillar lining epithelium. Cyst was lined by stratified squamous epithelium with the lumen filled with keratinous flakes.

\* Corresponding author.

E-mail address: [bhadanipunam@gmail.com](mailto:bhadanipunam@gmail.com) (P. P. Bhadani).



**Fig. 1:** CECT neck shows bulky enhancing lesion in left tonsillar fossa with small hypodense cystic area measuring 2.1 x 1.5 x 1.9 cm.



**Fig. 2:** Photomicrograph shows irregular dilated cystic cavity inside the tonsil, lined by stratified squamous epithelium filled with keratinous flakes (H&E stain; 40x), inset show presence of actinomycetes. (H&E stain; 100x)

Adjacent to the cystic area actinomycetes bacterial colonies were seen. (Figure 2).

### 3. Discussion

The palatine tonsil is a lymphoid tissue with an external lining of stratified squamous epithelium.<sup>4</sup> Cysts in the oral cavity can be epidermoid, dermoid and teratoid.<sup>5</sup> Microscopy is the best tool for definite diagnosis. Epidermal

inclusion cyst is lined by simple squamous epithelium and its wall does not contain skin adnexal structures or fibrous elements. However, dermoid cysts contain skin adnexal structures and teratoid cysts contain all three germ layer components like muscle, bone, cartilage or fat. The male to female ratio with diagnosis of EIC in tonsil is 1:4, majority in the age group of 10-35 years.<sup>3,5</sup> Present reported case was a 57 year old male with cystic lesion suspected on CECT neck.

These cysts can be associated with certain hereditary syndromes like Gardner syndrome caused by mutations in the adenomatous polyposis coli gene, or in Lowe syndrome, an X-chromosomal oculo-cerebral-renal disorder caused by mutations of the OCLR1-gene (Oculo Cerebro Renal Lowe syndrome).<sup>4</sup>

Pathogenesis behind the development of epidermal inclusion cyst proposed are the inclusion of ectodermal tissue during the embryogenesis or might be metaplastic change due to chronic irritation.<sup>3-5</sup> In the present case presence of actinomycetes might be a chronic or prolonged irritant for the development of EIC. Histopathological examination is considered as gold standard which can easily differentiate these entities. Hence, gross and microscopy in every resected tonsillar mass is of utmost important. Complications of squamous inclusion cysts are rare, but can lead to infection, scarring, recurrence or rarely malignancy, if non-diagnosed or untreated.<sup>6</sup> Post-surgical follow-up of the present case was uneventful.

Actinomycetes are gram-positive, non-acid fast, anaerobic or microaerophilic filamentous branched bacteria which are very difficult to grow in culture, less than 30% of cultures being positive for this bacterial infestation. Cervicofacial region is the most common area of involvement by actinomycetes.<sup>6</sup> The pathogenesis is associated to its capacity to act as an intracellular parasite and thus resist phagocytosis as well as its inclination to spread without respect for well-established tissue plains.<sup>3-6</sup>

Treatment for these lesions is surgical excision of the cyst or tonsillectomy, depends on the clinical presentation.<sup>5,6</sup> Intact excision of tonsil is important as its contents could have an irritating effect on the surrounding fibrovascular tissue. Excised tonsils must be sent for histopathological examination for correct treatment and importance of follow-up due to increased risk of recurrence.

### 4. Conclusion

To conclude the importance of this case report, is to highlight the rarity of epidermal inclusion cyst and actinomycetes in the tonsil together, and one might be the cause of another entity. Clinically patient might represent as difficulty in swallowing and can mimic malignancy. Surgical intervention is compulsory with histopathological examination, in each and every case to differentiate between benign and malignant pathology and to start correct

treatment with importance of regular follow-up.

## 5. Conflicts of Interest

The authors declare that there are no conflicts of interest regarding the publication of this paper.

## 6. Source of Funding

None.

## References

1. Fernandes VL, Khandolkar P, Pillai VG, Sukhthankar IR, Chari AA. Squamous Inclusion Cyst in the Palatine Tonsil Mimicking a Tumor. *Int J Otolaryngol Head Neck Surg*. 2018;7(5):249–53.
2. Bouatay R, Jellali S, Abdejelil N, Koubaa J. Epidermoid cyst of the tonsil: a rare finding. *The Pan Afr Med J*. 2019;34. doi:10.11604/pamj.2019.34.4.18193.
3. Nikumbh DB, Nikumbh RD, More H. Intratonsillar multiple epidermal inclusion cysts-A tumor mimic. *Arch Cytol Histopathology Res*. 2017;2(1):18–20.
4. Jain A, Saeed N, Maheshwari V, Kamal M. Epidermoid Cyst of The Tonsil: a rare finding. *Int Arch BioMed Clin Res*. 2017;3(1):14–5.
5. Janarthanam J, Mahadevan S. Epidermoid cyst of submandibular region. *J Oral Maxillofac Pathol*. 2012;16(3):435–7.
6. Mishra U, Giridher V, Ahmad Z. Tonsillar Actinomycosis with multiple epidermoid cysts: A rare case report. *IOSR J Dent Med Sci (IOSR-JDMS)*. 2019;18(4):12–4.

## Author biography

**Punam Prasad Bhadani**, Professor and Head

**Sneha Aditi**, Senior Resident

**Avinash Singh**, Senior Resident

**Nisha**, Senior Resident

**Cite this article:** Bhadani PP, Aditi S, Singh A, Nisha. Tonsillar Actinomycosis with presence of Epidermal inclusion cyst: Report of a rare entity. *IP Arch Cytol Histopathology Res* 2021;6(4):288-290.