

Content available at: <https://www.ipinnovative.com/open-access-journals>

IP Annals of Prosthodontics and Restorative Dentistry

Journal homepage: <https://www.aprd.in/>

## Case Report

# An alarming complication of hexdriver ingestion: A caution for implantologists: A clinical report

Kavya Koluguri<sup>1,\*</sup>, Mamatha N S<sup>2</sup>, Sweeda Sunny<sup>1</sup>, Shrutha Prabhachandra<sup>1</sup>, Nabeela Begum<sup>1</sup>

<sup>1</sup>Dept. of Implantology, Rajarajeshwari Dental College and Hospital, Bengaluru, Karnataka, India

<sup>2</sup>Dept. of Oral and Maxillofacial Surgery, Rajarajeshwari Dental College and Hospital, Bengaluru, Karnataka, India



### ARTICLE INFO

#### Article history:

Received 30-07-2022

Accepted 09-08-2022

Available online 30-09-2022

#### Keywords:

Dental implants

Aspiration

Ingestion

Complication

Management

Surgical intervention

### ABSTRACT

Implant dentistry has been a breakthrough invention for the rehabilitation of partially and completely edentulous patients for a few decades, but an advancing complication associated with implant procedures is the accidental ingestion or aspiration of dental implant components (implants, cover screws, abutments, implant instruments etc.) A radiographic evaluation is essential to confirm the presence of a foreign body. Generally, instruments that enter the gastrointestinal tract pass asymptotically within 4 days to 2 weeks. Occasionally, a surgical approach is requisite to remove the instrument when there is some complication in the gastrointestinal tract. Thus, a legitimate diagnosis is essential to avoid unnecessary surgical intervention. However, the knowledge of such incidents, their treatment protocols and preventive measures are to be known to every clinician performing implant treatments in order to deal with such situations effectively. This article presents a case report of accidental ingestion of the hex driver used during the clinical procedures in implant dentistry and its management.

This is an Open Access (OA) journal, and articles are distributed under the terms of the [Creative Commons Attribution-NonCommercial-ShareAlike 4.0 License](https://creativecommons.org/licenses/by-nc-sa/4.0/), which allows others to remix, tweak, and build upon the work non-commercially, as long as appropriate credit is given and the new creations are licensed under the identical terms.

For reprints contact: [reprint@ipinnovative.com](mailto:reprint@ipinnovative.com)

## 1. Introduction

Although unusual, foreign body (impression material, crowns, brackets, files, implant abutments, hex drivers etc.) ingestion occurs in dentistry and may at times result in serious complications. In general, when an object is lost in the oropharynx, there exist two possibilities: patients may either ingest it into the stomach or aspirate it into the lungs. Approximately 80% of objects lost are ingested into the gastrointestinal system, 20% are aspirated into the lungs and almost 90% of ingested objects usually pass through the gastrointestinal tract predictably in 4 to 6 days.<sup>1</sup> There are, however, many potential sites of impaction, including the ileocecal valve and rectosigmoid junction. 75% of all perforations occur at or near the ileocecal valve.<sup>2,3</sup> The

complications associated with swallowed foreign bodies are generally haemorrhage, infection, intestinal obstruction, and perforation.<sup>4</sup> An early diagnosis plays a key role in treatment success. Clinical management involves watchful waiting with serial radiographs, or intervention either by means of endoscopy or by open abdominal surgery. Surgical interventions are necessary when there is bleeding, obstruction, or impaction in the gastrointestinal tract.

Due to the miniature size of implants, and implant components (abutments, hex drivers, etc.) this complication may easily occur at any time during implant procedures (surgical and prosthetic). The reason for such complications is the difficulty in handling such small implant instruments and components added by the slippery nature of saliva or blood. Most implant procedures are performed supine or semi-recumbent, which may predispose to ingestion or aspiration. In addition, other contributing factors include

\* Corresponding author.

E-mail address: [kavyakoluguri@gmail.com](mailto:kavyakoluguri@gmail.com) (K. Koluguri).

the use of local anaesthesia (loss of gag reflex), oral or intravenous sedation, unexpected patient movements, poor access and visualization, limited mouth opening, and unexpected detachment of implant components.<sup>5-7</sup>

The aim of this article is to describe a clinical report in which a hex driver was accidentally ingested and to bring awareness regarding potential consequences with preventive and treatment methods.

## 2. Case Description

A 26-year-old male patient reported to the Implantology department of Rajarajeswari Dental College and Hospital with the chief complaint of missing teeth in the lower left and right back tooth region since 6 months and wanted to get a replacement of the same. Dental implants were placed in 36 and 46 areas. During the second-stage surgery, as the treating doctor was attempting to access the implant cover screw, the hex driver slipped from the hand. Consequently, as the clinician was attempting to retrieve the instrument, patient exhibited a sudden movement which resulted in the involuntary swallowing of the hex driver by the patient. When asked whether he had realized about swallowing something, he told he was unaware. Immediately after the episode, the patient was referred to the Emergency Department at the Rajarajeswari Medical College and Hospital.

On clinical examination, the patient did not report any discomfort or symptoms. An abdominal radiograph was advised for the patient. An X-ray revealed the presence of an instrument in the gastrointestinal tract. Taking into consideration- the patient's age, history and instrument characteristics, the medical team decided to make a daily radiograph to evaluate whether the instrument was moving in the gastrointestinal tract.

The patient was kept on a fibre-rich diet in an attempt to eliminate the instrument physiologically (stool analysis by the patient was also recommended to confirm whether the instrument was expectorated). The patient was asked to report to the hospital in case of any symptoms like abdominal pain, cramps or blood in the stool. The entire situation and its consequences were explained to the patient clearly.

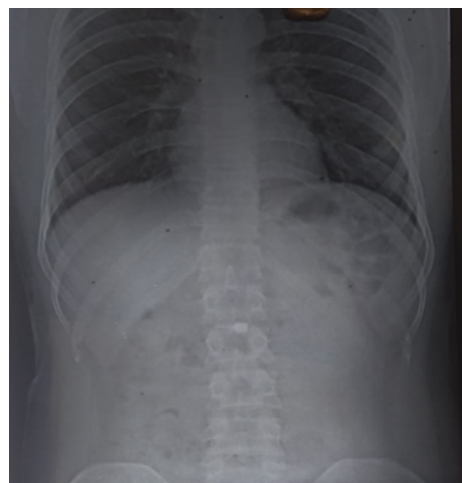Day 1: Radiograph taken on the day of the incident revealed the presence of hex driver in the upper gastrointestinal tract. Figure 1

Day 2: The radiograph disclosed the presence of hex driver in the lower parts of the gastrointestinal tract. Figure 2

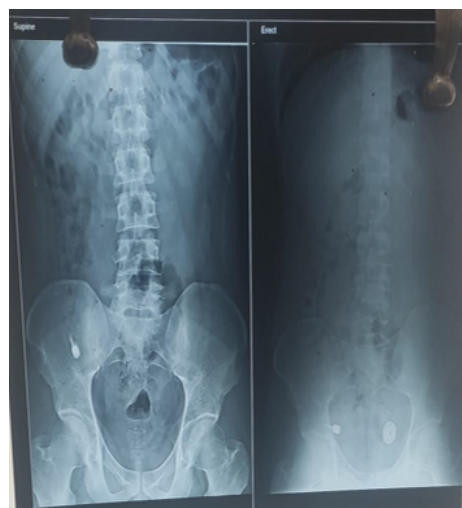Day 5: Radiograph showed the absence of hex driver in the gastrointestinal tract. Figure 3

## 3. Discussion

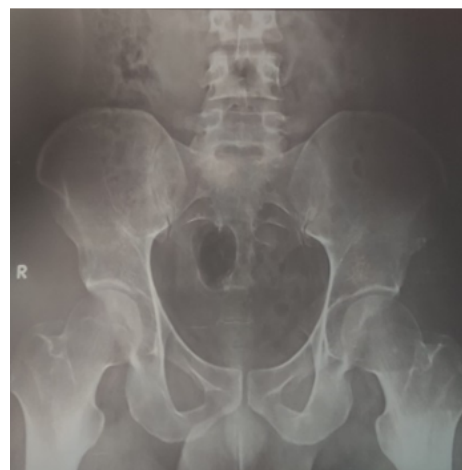During the dental procedure, if a foreign object is lost in the oropharynx when the patient is in the supine position,



**Fig. 1:** DAY 1: Abdominal radiograph



**Fig. 2:** DAY 2: Abdominal radiograph (supine and erect position)



**Fig. 3:** Day 5: Pelvic radiograph

it is advisable not to instruct the patient to sit straight up immediately, as this may lead to ingestion or aspiration of the instrument. It is ideal to make the patient turn to a side and attempt to “cough up” the object.<sup>7</sup>

If an instrument is lost, immediate symptoms usually are a good indicator in determining if the foreign body was aspirated or ingested. If the patient exhibits coughing, wheezing, pain, and cyanosis symptoms, an immediate medical emergency protocol should be initiated, as this is indicative of aspiration. If the patient is asymptomatic, which usually indicates ingestion; it is mandatory that the patient is referred to their physician or emergency room for immediate radiographs. Radiographic examination (usually chest and abdomen radiograph) is necessary for the diagnosis of the location, size, and shape of the foreign body, as well as the need for immediate medical intervention.<sup>7</sup> Radiographic evaluation and a fibre-rich diet is the initial protocol for the management of such cases. Abdominal pain and/or the presence of blood in the patient’s faeces are signs of intestinal perforation or obstruction. In such cases, surgical removal is indicated.<sup>1</sup>

In the case presented here reassurance of the patient, vigilant follow-up with serial x-rays and diet modification has resulted in a favourable outcome.

Any foreign object that is aspirated could be located anywhere along the tracheobronchial tree; however, the right bronchus is the most common site because of its more vertical and wider anatomic configuration in comparison to the left bronchus.<sup>8</sup> Usually, the patient will be symptomatic, exhibiting signs of laryngotracheal obstruction such as the universal sign of choking, dyspnea, coughing, wheezing, stridor, or cyanosis.<sup>7</sup> If airway obstruction is present, the clinician should immediately encourage the patient to cough, if the condition doesn’t improve, and the patient is conscious Heimlich manoeuvre should be performed and if the patient is unconscious CPR protocol is to be initiated. Stabilizing the patient in such a situation is most crucial. Once the patient is stabilized, he has to be transferred to the emergency department for localization of the instrument and its recovery.

Following the confirmation of the location, retrieval is necessary most commonly with flexible or rigid bronchoscopy. Bronchoscopy has been shown to be 99% effective in the removal of foreign objects; however, 1% requires surgical retrieval. Long-term retention of the foreign body in the respiratory system can be life-threatening resulting in possible complications like pneumonia, atelectasis, pneumothorax, haemorrhage, or lung abscess.<sup>7</sup>

### 3.1. Prevention

Ingestion and aspiration of objects used in dentistry are most commonly attributed to the iatrogenic cause and can be prevented. It is vital that the dental implant clinician

incorporates specific preventive treatment techniques and protocols to minimize the possibility of such complications.

Techniques to prevent ingestion or aspiration include:

1. Patient positioning: For implant procedures with an increased risk of ingestion or aspiration, it is advisable to keep the patient seated in a more upright position instead of a supine position.<sup>7</sup>
2. Throat packs or pharyngeal screens: The most common technique that can be used to avoid ingestion or aspiration is the use of 4x4 surgical gauze. The gauze should be opened and positioned in the oral cavity distal to the area of treatment. A 2x2 gauze should never be used, as saliva or blood saturation may lead to the gauze being aspirated or ingested due to its small size.<sup>7</sup>
3. Ligatures: Dental floss or suture material should be tied to any possible implant component so that easy retrieval is possible if an object is lost in the oropharynx.<sup>7</sup>
4. High-vacuum suction: Can be used with a large aspirator if the foreign body is easily accessible.<sup>7</sup>
5. Surgical Gloves: Because of blood and saliva, it is not uncommon for surgical gloves to become slippery. Though not practical, periodic glove replacement will prevent this complication.<sup>7</sup>

Unfortunately, no single technique will guarantee this complication from occurring; thus, extreme caution should always be exercised.<sup>7</sup>

## 4. Conclusion

“Learning from your mistakes is smart, learning from the mistakes of others is wise”. This article is an attempt to educate clinicians about the pitfalls that can happen during implant treatments by presenting one such case that took place and to put a halt to iatrogenic errors for accidental ingestion or aspiration of foreign bodies.

## 5. Source of Funding

None.

## 6. Conflict of Interest

None.

## References


1. Abusamaan M, Giannobile WV, Preeti J, Naresh TG. Swallowed and aspirated dental prostheses and instruments in clinical dental practice. *J Am Dent Assoc.* 2014;145(5):459–63. doi:10.14219/jada.2013.55.
2. Macmanus JE. Perforations of the intestine by ingested foreign bodies: Report of two cases and review of the literature. *Am J Surg.* 1941;53(3):393–402. doi:10.1016/S0002-9610(41)90652-9.
3. Maleki M, Evans W. Foreign-body perforation of the intestinal tract. *Arch Surg.* 1970;101(4):475–7.

4. Souza JG, Filho GS, Neto AP, Jr HL, Bianchini MA, Cardoso AC, et al. Accident in implant dentistry: involuntary screwdriver ingestion during surgical procedure. A clinical report. *J Prosthodont*. 2012;21(3):191–3. doi:10.1111/j.1532-849X.2011.00826.x.
5. Iovino P, Sarno A, Caro VD, Mazzei C, Santonicola A, Bruno V, et al. Screwdriver Aspiration During Oral Procedures: A Lesson for Dentists and Gastroenterologists. *Prosthesis*. 2019;1(1):61–8. doi:10.3390/prosthesis1010008.
6. Filho GS, Souza J, Dalago HR, Ouriques FD, Tosin CA, Bianchini MA, et al. Management of accidental aspiration of foreign bodies in implant dentistry. *Int J Stomatology Occlusion Med*. 2014;7(1):95–6. doi:10.1007/s12548-013-0095-6.
7. Resnik RR. A serious and emerging complication in implant dentistry: ingestion or aspiration of implant components; Available from: <https://implantpracticeus.com/dr-randolph-r-resnik-director-of-the-misch-international-implant-institute/>.
8. Ireland A. Management of inhaled and swallowed foreign bodies. *Dent Update*. 2005;32(2):83–6. doi:10.12968/denu.2005.32.2.83.

## Author biography

**Kavya Koluguri**, Student  <https://orcid.org/0000-0002-8172-9359>

**Mamatha N S**, Professor  <https://orcid.org/0000-0003-3029-8971>

**Sweeda Sunny**, Student  <https://orcid.org/0000-0003-1765-8506>

**Shrutha Prabhachandra**, Tutor

**Nabeela Begum**, Student

<p><b>Cite this article:</b> Koluguri K, Mamatha N S, Sunny S, Prabhachandra S, Begum N. An alarming complication of hexdriver ingestion: A caution for implantologists: A clinical report. <i>IP Ann Prosthodont Restor Dent</i> 2022;8(3):171-174.</p>
--