

Content available at: <https://www.ipinnovative.com/open-access-journals>

IP Annals of Prosthodontics and Restorative Dentistry

Journal homepage: <https://www.aprd.in/>

## Case Report

# Denture marking as a forensic tool- Case series

Surbhi Sharma<sup>1,\*</sup>, Reeta Jain<sup>1</sup>, Shanta Chopra<sup>1</sup>, Shaveta Kaushal<sup>1</sup>

<sup>1</sup>Dept. of Prosthodontics, Grnesis Institute of Dental Sciences and Research, Ferozepur, Punjab, India



### ARTICLE INFO

#### Article history:

Received 18-11-2021

Accepted 24-11-2021

Available online 10-12-2021

#### Keywords:

Cheiloscopy

Denture labeling

DNA fingerprinting

Forensic science

### ABSTRACT

Forensic odontology is the branch that comes under forensic science which deals with proper handling, examination and evaluation of dental evidences. This manuscript describes various techniques that can be adopted for denture identification. The labeling method followed here is inclusion method where photographic sheet was used to mark dentures as this sheet is solvent resistant. The area selected for denture marking is palatal area on maxillary denture and distolingual flange of mandibular area as these areas have sufficient space for inclusion of details and there are not esthetically compromising areas. By this method denture labeling could be done in existing prosthetic devices or could be incorporated in newly constructed prosthesis. The American Board of Forensic Odontology guidelines indicate that most dental identifications are based on restorations, caries, missing teeth and/or prosthetic devices.

This is an Open Access (OA) journal, and articles are distributed under the terms of the [Creative Commons Attribution-NonCommercial-ShareAlike 4.0 License](https://creativecommons.org/licenses/by-nc-sa/4.0/), which allows others to remix, tweak, and build upon the work non-commercially, as long as appropriate credit is given and the new creations are licensed under the identical terms.

For reprints contact: [reprint@ipinnovative.com](mailto:reprint@ipinnovative.com)

## 1. Introduction

A prosthodontist play a major role in fabrication of prosthesis which was used as identification tool for investigation. We can use patient's name, picture, number or any other relevant information for this purpose. Also, every individual living in India has Aadhaar number given by Unique Identification Authority of India (UIDAI) Aadhaar card project. So this can also be used. We can use QR code (Quick response code) to incorporate abundance of information in a small area over the denture.<sup>1,2</sup> Therefore different labeling techniques are used in this report to give an idea about denture identification methods.

## 2. Case series

### 2.1. Case 1

1. A female patient, 60 years old reported to the department of Prosthodontics, Crown & Bridge and

oral implantology having chief complaint of difficulty in chewing food due to missing teeth since two years. Patient's vitals were checked and case history was taken with detailed intra and extra oral examination. During history taking, it was found that patient lives in a joint family and four persons were already wearing dentures.

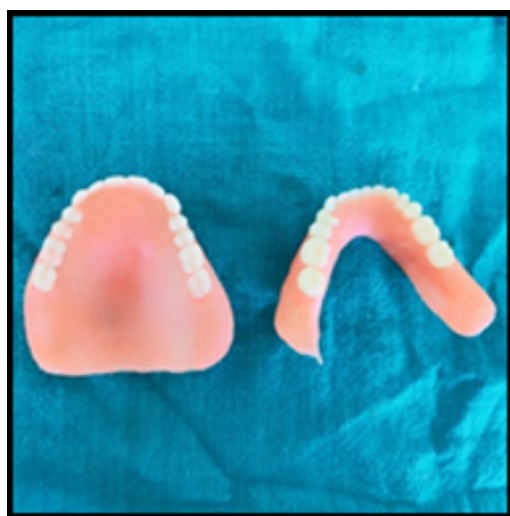2. Complete denture fabrication with labeling was advised to the patient for the purpose of denture identification to avoid exchange of denture with other family members. Advantages and disadvantages of denture labeling were also explained in detail to the patient and patient was positive about the procedure. Written consent was taken from patient with signature.
3. All conventional steps in fabrication of complete denture prostheses were followed and fabrication was done with compression molding technique with heat cure acrylic resin (DPI India) (Figure 1). After the fabrication of denture, final finishing and polishing was completed. Patient's aadhaar card information was written on a notepad for the purpose of

\* Corresponding author.

E-mail address: [surbhisharma12025@gmail.com](mailto:surbhisharma12025@gmail.com) (S. Sharma).

label preparation.<sup>3</sup> An application named “QR code generator” was downloaded on the smart phone and patient’s details were added to this application that includes name of patient, Aadhaar number, pin code of patient’s residence. QR code was generated through this application and printed on the photographic paper having dimensions of 1.7cm×1.7cm, another photographic paper with printed Aadhaar number of patient was prepared having dimensions of 3.5cm×0.5cm (Figure 2).

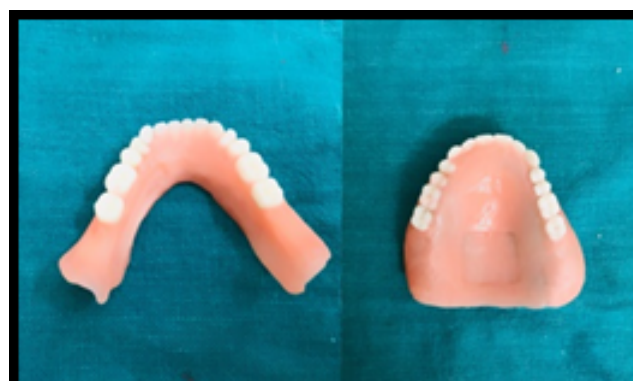4. On the polished surface of posterior palatal region of the maxillary denture, a slot of 1.8cm×1.8cm in dimension and 1.5mm deep was made with acrylic trimming bur to accommodate QR Code of Aadhaar information. Same way a slot of 3.5cm×0.5cm with depth of 1.5mm prepared on distolingual flange of mandibular denture to accommodate Aadhaar number (Figure 3). The QR code was precisely placed in the prepared slot in maxillary denture without any fold and Aadhaar number is placed on the mandibular prepared slot. The clear self-polymerizing acrylic resin (DPI cold cure) was mixed according to manufacturer’s instructions and placed over the QR code and Aadhaar number to fill the slot in maxillary and mandibular denture respectively and was allowed to set.<sup>4</sup>
5. Denture was again finished and polished to enhance the clarity of QR code and Aadhaar number (Figure 4). The QR code is scanned with QR code scanner in different smart phones to confirm the scan ability of incorporated code and it was clearly retrieved (Figures 5 and 6).
6. Denture insertion was done and patient was happy with the procedure as it was going to help her in identifying denture as it has unique information incorporated (Figures 7 and 8).



**Fig. 1:** Prosthesis fabricated



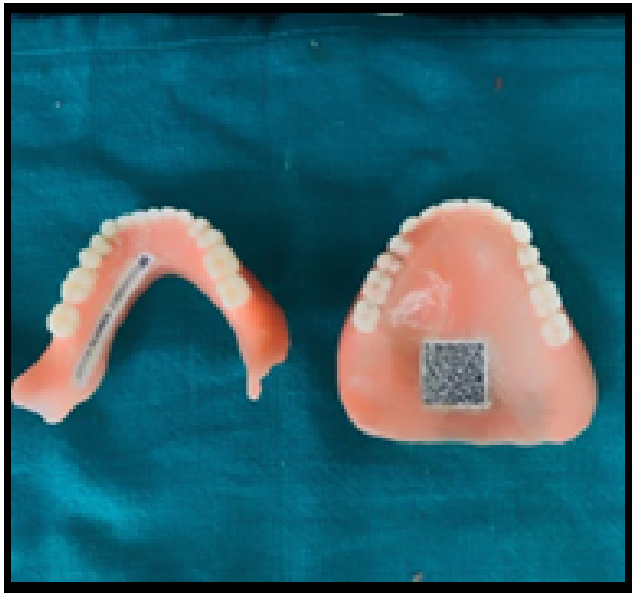
**Fig. 2:** Aadhaar number and QR code printed on photographic sheet



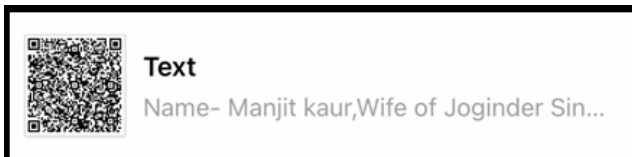**Fig. 3:** Slot of desired dimensions prepared

## 2.2. Case 2

1. Another female patient 57 years old was reported with chief complaint of difficulty of chewing food due to worn out old dentures. Residual ridge was inspected, patient’s vitals were checked and case history was taken with detailed examination. During history taking, it was found that patient was wearing dentures since eight years and has three set of dentures but she was not satisfied with the previous dentures.
2. Complete denture fabrication with labeling was advised to the patient for the purpose of denture identification to avoid exchange of denture with previous dentures. Advantages and disadvantages of denture labeling were explained in detail to the patient and patient was positive about the procedure. Written consent was taken from patient with signature. Same procedure as described before was followed for fabrication of denture and patient’s name on photographic sheet was incorporated on both the



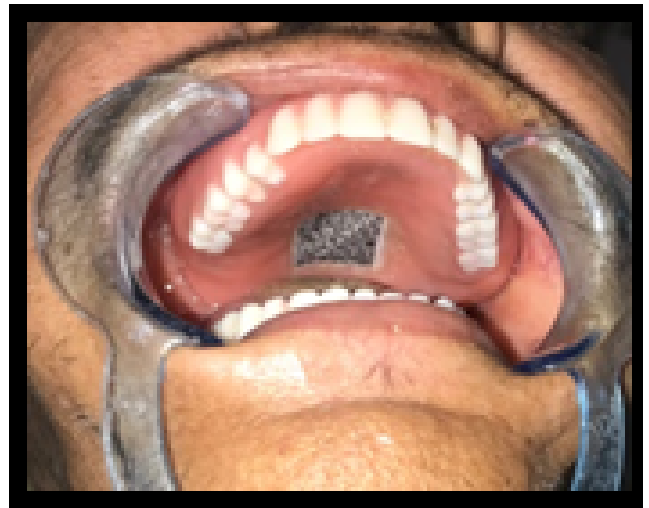**Fig. 4:** Definitive prosthesis



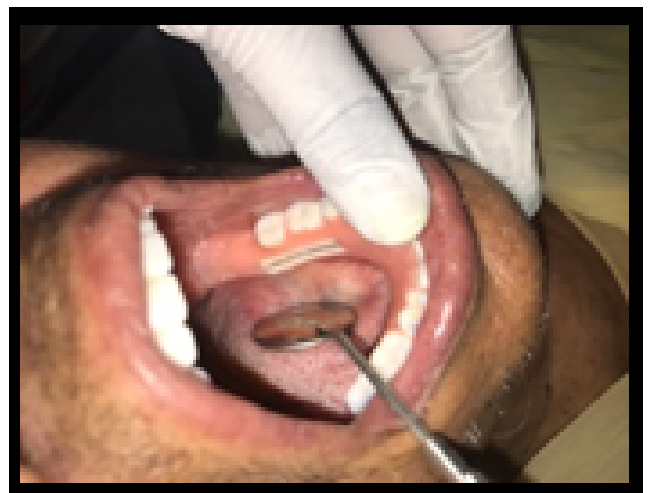**Fig. 5:** QR code scanned



**Fig. 6:** Information retrieved after scanning code



**Fig. 7:** Maxillary denture insitu



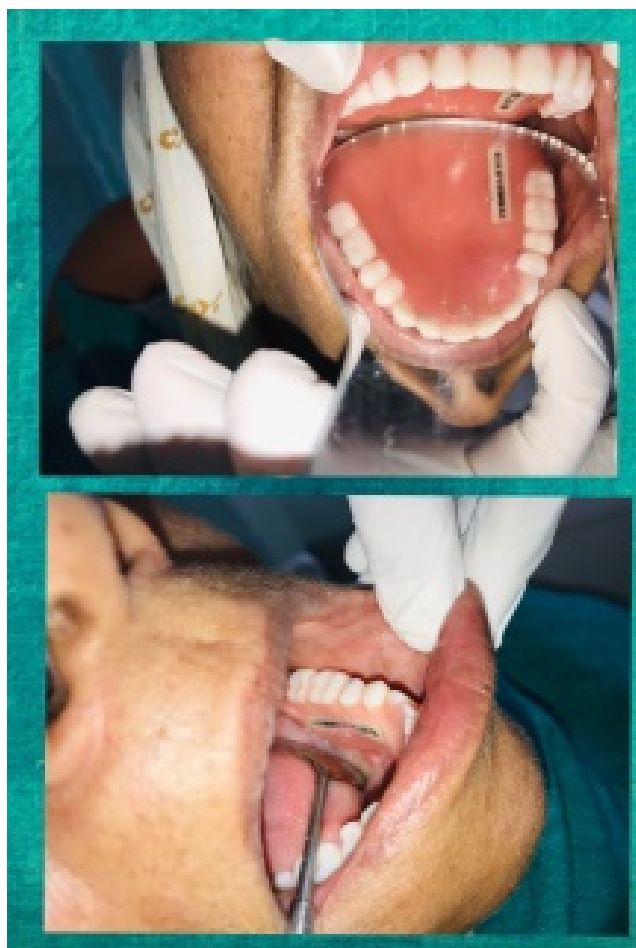**Fig. 8:** Mandibular denture insitu

maxillary and mandibular denture on the palatal region and distolingual flange respectively (Figure 9).

3. Denture insertion was done and post-operative instructions were given to the patient and follow up was done.

### 2.3. Case 3

1. A camp was conducted in a village where multiple patients with complete edentulism reported and wants the treatment of same.
2. To fabricate dentures of all patients was a meticulous procedure and requires some identification mark so patients were informed about the denture marking procedure. Almost all the patients agreed for the denture identification techniques.

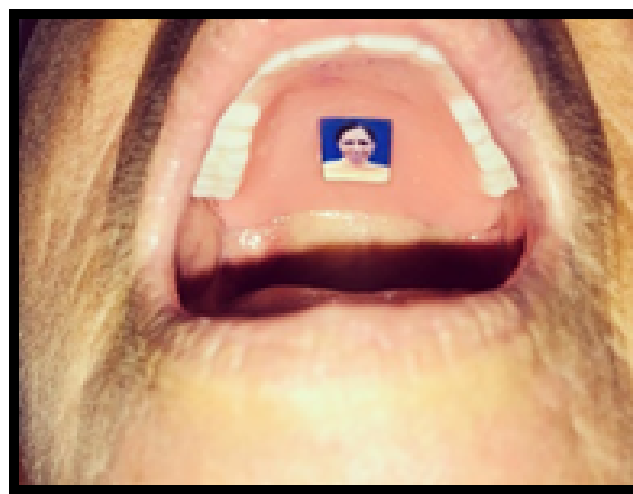


**Fig. 9:** Definitive prosthesis

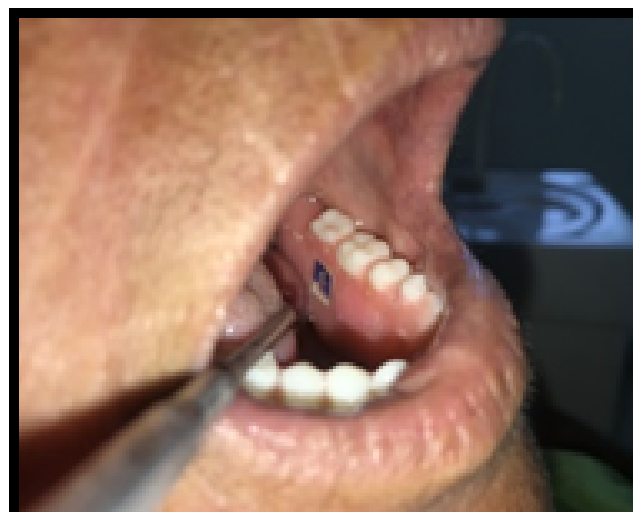3. So, conventional denture fabrication was done and then photographs of patients were incorporated on the palatal region on the maxillary denture (Figure 10) and distolingual flange on the mandibular denture (Figure 11).
4. This procedure helped us to identify the dentures of different patients and all the patients gave positive response.

### 3. Discussion

Forensic dentistry includes various odontological parameters such as bite marks identification, DNA fingerprinting, cheiloscopy and rugoscopy. These markers have little but effective use in completely edentulous patients. A prosthodontist play a major role in fabrication of prosthesis as identification tool for requirement of medico- legal investigation.<sup>5</sup> Dental records of edentulous patients are often less due to lack of record keeping and infrequent follow up of the patients by the dental practitioners. Therefore, the provision of some form of



**Fig. 10:** 10: Maxillary prosthesis insitu



**Fig. 11:** Mandibular prosthesis insitu

permanent denture labeling or marking can serve as a tool to these problems. Denture markers play an important role in forensic sciences and also in identifying a person in any road traffic accident, bombings, terrorism, air crashes, typhoons, tsunami etc. Denture marking systems can be divided to two broad categories as surface marking and inclusion methods. Surface marking methods involves- Engraving method, Embossing method, Invisible ink method, Fiber tip pen method, Heath's method, Stevensons method, Weckers electro pen method, Laser etching method, Onion skin paper method, Denture bar coding method. Inclusion methods include- Lose inclusion method, Youngs method, Dippenars method, Reasons method, Clear acrylic T bar method, Olivers method, Lenticular card method, Bar coding method, Radio frequency identification tag, Lead foil method, Metallic band according to Swedish guidelines, Photograph inclusion method, Min I Dent method, Data

matrix code, Microlabelling, Cast embossed identification plate, Ceramic crown engraving method, Memory card method.<sup>6</sup> Denture marking has more advantages like its significant application in personal identification in case of accidents, disasters and mass destruction of human beings, wars, also in identifying lost or misplaced dentures in health care centers, in a coma or unconscious person, diagnostic and decision support in medico legal issues, identification among geriatric patients in institutes. It also has advantage in dental camps conducted by various institutes and government hospitals that fabricate dentures of multiple people in a single camp, as conducted by Punjab government twice a year.

This article describes easy and very cost effective way of denture labeling. The equipment required are easily available in many institutes, dental laboratory or dental clinic. The procedure could be easily performed by dental auxiliary personnel thereby reducing workload for the dentist.

Denture marking has certain disadvantages like if the denture labelling systems are placed on the intaglio (impression) surface they become invisible when relining is done, after inclusion of the marker in the dentures, changing the patients detail becomes a tedious job, some denture marking systems requiring special equipment to read the data like barcodes, memory card which cannot be obtained quickly in cases of emergencies like road accidents, mass disasters etc., surface engraving methods leads to food lodgment.

#### 4. Conclusion

Identification is an essential requirement of any medicolegal investigation because a wrong identity may pose a problem in delivering justice. There is a strong need to adopt an international policy for denture marking and international collaboration should be encouraged, with different opinions from the world-wide community of forensic odontologists. Prosthodontists play a very important role in forensic dentistry as they are concerned with fabrication of

various prosthesis that can serve as an important tool for identification.

#### 5. Conflicts of Interest

The authors declare that there are no conflicts of interest regarding the publication of this paper.

#### 6. Source of Funding

None.

#### References

1. Pathak C, Pawah S, Sikri A, Rao I. Unique denture identification system for all indian nationals. *Contemporary Clinical Dentistry*. 2018;9:185–192.
2. Jain AR, Sindhu P, Krishnan CJ, Chandran CR. A new alternative technique for denture identification. *World J Dent*. 2015;6(3):188–92.
3. Barde S. A Multimodal Biometric System-Aadhar Card. i-manager's *Journal on Image Processing*. 2018;5(2):1–1.
4. Rajendran V, Karthigeyan S, Manoharan S. Denture marker using a two-dimensional bar code. *Journal of Prosthetic Dentistry*. 2012;107(3):207–215.
5. Mohan J, Kumar CD, Simon P. Denture marking” as an aid to forensic identification. *The Journal of Indian Prosthodontic Society*. 2012;12(3):131–137.
6. Kareker N, Aras M, Chitre V. A review on denture marking systems: a mark in forensic dentistry. *The Journal of Indian Prosthodontic Society*. 2014;14(1):4–13.

#### Author biography

**Surbhi Sharma**, Post Graduate 2nd Year

**Reeta Jain**, Professor and Head

**Shanta Chopra**, Senior Lecturer

**Shaveta Kaushal**, Reader

**Cite this article:** Sharma S, Jain R, Chopra S, Kaushal S. Denture marking as a forensic tool- Case series. *IP Ann Prosthodont Restor Dent* 2021;7(4):235-239.