

Content available at: <https://www.ipinnovative.com/open-access-journals>

International Journal of Oral Health Dentistry

Journal homepage: www.ijohd.org

Original Research Article

A clinico-histological comparative evaluation of healing of periodontal flaps when approximated with silk sutures and n-butyl cyanoacrylate

Himanshu Aeran^{1,*}, Amrinder Singh Tuli², Ila Sharma²¹Dept. of Prosthodontics Crown and Bridge, Seema Dental College and Hospital, Rishikesh, Uttarakhand, India²Dept. of Periodontology, Seema Dental College and Hospital, Rishikesh, Uttarakhand, India

ARTICLE INFO

Article history:

Received 25-05-2022

Accepted 01-06-2022

Available online 03-09-2022

Keywords:

Modified flap operation

Silk sutures

N-butyl cyanoacrylate

Healing

Excisional biopsy

ABSTRACT

Background: Periodontitis is an inflammatory disease which results by the interaction between bacteria leading to inflammation and destruction of the connective tissue attachment apparatus. Flap surgeries are most frequently employed treatment modality for deep periodontal pockets. Over the decades, many suture materials like silk and nylon are being used for the approximation of the flaps. In the present scenario of periodontal advancements, fibrin glue manifests to be a great alternative to flap approximation with better clinical and histological results.

Aim & Objectives: This randomized clinico-histological study aims to compare the healing of modified flap operation when approximated with Silk suture and N-butyl cyanoacrylate bioadhesive.

Materials and Methods: Thirty patients were recruited in this clinico-histological study. In Group A, surgical site was approximated by 3-0 black braided silk sutures (@TRUSILK) and in Group B, N-butyl cyanoacrylate bioadhesive (@EPICLOS) was used by driplets for flap approximation. Patients were recalled for removal of sutures and any cyanoacrylate present after 1 week of surgery. All the parameters (clinical and histological) were taken at baseline and at 7th day.

Results: On intra and inter group comparison all the clinical parameters i.e., Gingival index (GI), Papillary Marginal Attachment (PMA) Index, Turesky-Gilmore-Glickman modification of Quigley Hein Plaque Index (TQHPI), Wound healing index (WHI) and histological parameters i.e., inflammatory cells and vascularity shows significant reduction at 7th day in group B (N-butyl-cyanoacrylate).

Conclusion: N-butyl-cyanoacrylate (Group B) is more effective in reducing the clinical and histological parameters than Silk sutures (Group A).

This is an Open Access (OA) journal, and articles are distributed under the terms of the [Creative Commons Attribution-NonCommercial-ShareAlike 4.0 License](https://creativecommons.org/licenses/by-nc-sa/4.0/), which allows others to remix, tweak, and build upon the work non-commercially, as long as appropriate credit is given and the new creations are licensed under the identical terms.

For reprints contact: reprint@ipinnovative.com

1. Introduction

Periodontitis is caused by the interaction between bacteria that infect the periodontal pockets and their epithelial lining resulting in inflammatory reactions and destruction of the connective tissue attachment apparatus of the disease.¹ The periodontal flap surgeries are one of the most routinely used surgical treatment modality, specifically in deep periodontal pockets.² The flap approximation post-surgery

is essential for reattachment.³ Over the decades, various suture materials like silk, catgut, polylactic acid and nylon are used for the flap closure, but many problems are in correlation with the use of sutures in periodontal flap surgeries.⁴ With the advancements in periodontal surgeries, fibrin glue proves to be an excellent alternative for flap approximation with better clinical and histological results. Hence, the overall purpose of this clinico-histological study is an attempt to clinically compare and histologically evaluate the healing of periodontal flaps when approximated with silk sutures and N-butyl cyanoacrylate.⁵

* Corresponding author.

E-mail address: drhimanu4@gmail.com (H. Aeran).

2. Materials and Methods

This study was accomplished in the Periodontology department, Seema Dental College and Hospital, Rishikesh, Uttarakhand with the approval of ethical committee. The subjects were selected from out-patient department. The study included the patients of age 25-60 years including both genders, periodontitis with probing pocket depth (PPD) of ≥ 5 mm and clinical attachment level loss and patients who were maintaining good oral hygiene. The study excluded pregnant females or lactating women, patients with tobacco intake history in and/or smoking, allergic reaction or hypersensitivity to the product utilized in the study and uncooperative patients.

2.1. Study design

Sample size: 30 patients were recruited for the study. Modified flap operation given by Kirkland, 1931 was performed for pocket reduction therapy and the patients were then be randomly allotted into 2 groups (A & B) for the clinico-histological study.

Group A- The surgical site was closed using simple loop with 3-0 black braided silk sutures (@TRUSILK)(Figure 3).

Group B- The surgical site was closed by the application of N-butyl-cyanoacrylate bioadhesive (@EPICLOS) (Figure 2) which was applied by dribblets on the flap margins.

All the patients recalled for suture removal and any bioadhesive present after 1 week of surgery. GI, PMA Index, TQHPI and WHI were recorded for two groups at baseline and at 7th day. For histological parameters, the gingival tissue secured from the interdental tooth region of both the groups (A and B), which is further fixed and stained for assessment of healing. Gingival tissue was histologically examined and healing rates were compared for both the groups on the basis of epithelium, inflammatory cells, connective tissue and vascularity.

3. Results

All the parameters scores were statistically analyzed. For intra and intergroup comparison paired and unpaired ‘t’ test was used respectively. In this clinic-histological study mean difference in GI scores on intragroup comparison from baseline to 7th day were statistically significant in both the groups with $p < 0.001$. On intergroup comparison, Group II showed lesser mean scores indicating better gingival health with Epiclos (Table 1). PMA index scores on intragroup comparison from baseline to 7th day were statistically significant in both the groups with $p < 0.001$ (Table 2). On intergroup comparison, Epiclos had lesser mean scores than Silk group. The mean TQHPI scores on intragroup comparison from baseline to 7th day were statistically significant in two groups with $p < 0.001$. On intergroup

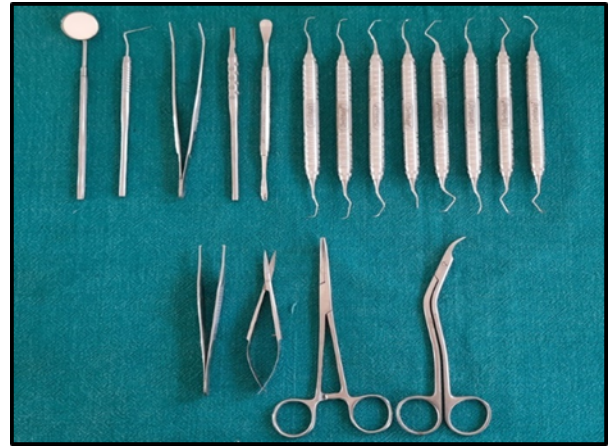

Fig. 1: Armamentarium used

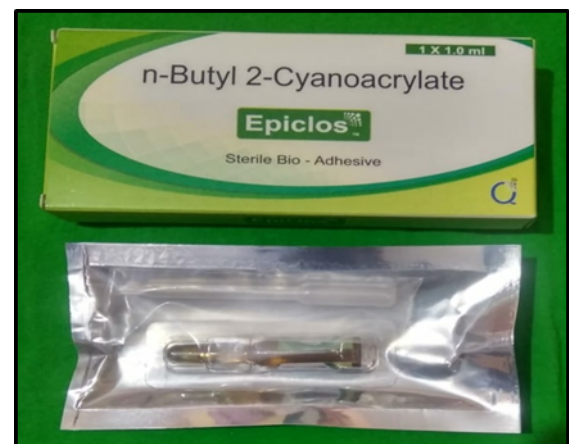

Fig. 2: N-Butyl cyanoacrylate

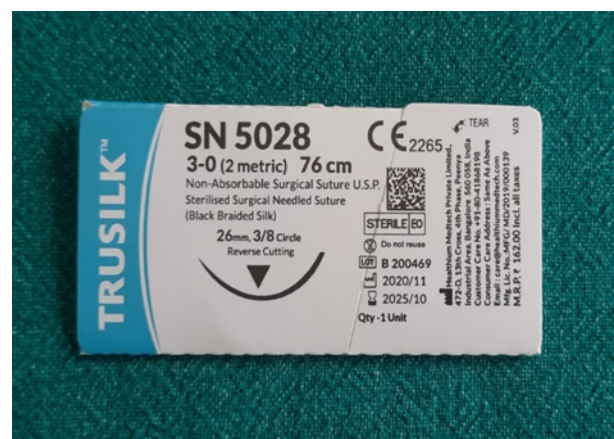

Fig. 3: 3-0 Black braided silk suture

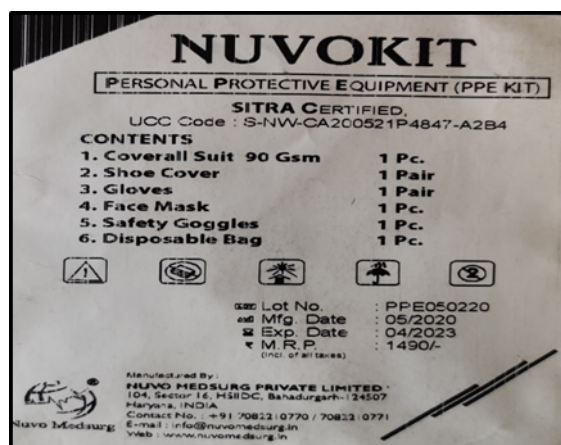

Fig. 4: Personal protective equipment

comparison, mean values shows statistically significant difference between the two groups (Table 3). Comparing two groups (Trusilk & Epiclos), mean healing index scores at 7th day of Group I and Group II was significant (Table 4). The mean values of Group I (Trusilk) and Group II (Epiclos) for Inflammatory cells were recorded which was lesser for epiclos (Table 5). The mean values of Group I (Trusilk) and Group II (Epiclos) for vascularity were recorded which was significantly greater in group I.

4. Discussion

Over the past several decades, periodontal therapy has been modified to achieve optimal health, function and aesthetics of the dentition. A variety of surgical techniques developed to restore the lost periodontal tissues due to destructive periodontal diseases.⁶ Over the decades, various suture materials like silk, catgut and polylactic acid are used for the flap approximation. Silk sutures are most commonly used for the approximation of wound edges, but it provides site for secondary infection due to its wicking effect. Therefore, need for an alternative is felt.⁷ The N-Butyl-2-cyanoacrylate has been widely used in dentistry as it provides immediate hemostasis, rapid adhesion to tissues in the presence of moisture as the molecules react and form a tight chain between the two surfaces which is to be bonded.⁸ In the present study healing assessment of periodontal flap when closed with 3-0 black braided silk suture and N-butyl cyanoacrylate bioadhesive was done and all the parameters were statistically analyzed using paired and unpaired 't' test.⁹ In this study, on intergroup comparison, Group II showed lesser GI mean scores indicating better gingival health with Epiclos. Manimegalai AG et al checked efficacy of fibrin adhesive (Tisseel®) and silk suture on wound closure after periodontal surgical procedures where they concluded that there was a decrease in GI scores postoperatively in Tisseel® group than in cases treated with sutures.¹⁰ Which is further supported

by Saquib AS et al where they concluded that GI score obtained at cyanoacrylate sites was lesser as compared to suture sites with statistical significance at seventh day indicating lesser gingival inflammation when approximated with cyanoacrylate.¹¹ Kulkarni S et al. also concluded in their study that the GI scores of sutures and cyanoacrylates showed statistically significant difference at 7th day. In this study, PMA index scores on intragroup comparison from baseline to 7th day were statistically significant in both the groups with $p < 0.001$.¹² In accordance with a study conducted by AlJasser RN et al visible plaque index was used to evaluate the oral hygiene status and gingival health at baseline and throughout the study in which no statistically significant difference was seen between the two groups.¹³ Whereas Saquib AS et al. concluded that Plaque index score obtained at adhesive sites was lesser as compared to suture sites with statistical significance at seventh day indicating better plaque control when approximated with cyanoacrylate as compared to silk sutures.¹¹ Whereas Surya S et al. demonstrated statistically significant lesser mean plaque score in cyanoacrylate group as compared to suture group.¹⁴ Comparing two groups (Trusilk & Epiclos) Pe' rez M et al concluded that healing index scores were better in N-butyl-2-cyanoacrylate based tissue adhesive. Healing of surgical wound was very good, bleeding was rapidly controlled, and no adverse effects (mucosal ulcerations, pain & discomfort) were observed.¹⁵ Whereas a study reported by Rewainy M et al showed no significant difference between two groups (3/0 silk suture and PeriAcryl 90 group) in wound dehiscence assessment after 2, 3 and 7 days.¹⁶ Oladega AA et al in their randomized controlled study concluded that no significant difference was observed in the mean wound dehiscence between the two groups (cyanoacrylate adhesive and silk suture).¹⁷ A study conducted by Sagar P et al. reported that isoamyl cyanoacrylate can be used for approximation as inflammation and oedema were not present in maximum number of cases at the 15th postoperative day.¹⁸ Whereas Barreno AC et al. concluded in their histological evaluation that polymorphonuclear infiltrate was lower in cyanoacrylate when compared to other used materials. The mean values of Group I (Trusilk) and Group II (Epiclos) for vascularity were recorded which was significant.¹⁹ In accordance with the study conducted by Vastani A et al. patients biopsied on the seventh postoperative day for inflammatory cell infiltration and vascularity which were higher on the sutured side compared with the glued side.²⁰

5. Conclusion

As per the results of this study, approximation of periodontal flap using silk suture and N-butyl-cyanoacrylate (bioadhesive) are effective in reducing the GI scores, PMA index scores, TQHP index scores but use of N-

Table 1: Intergroup comparison of Mean Gingival index for Group A versus Group B for 7 days interval (Trusilk vs Epiclos)

Parameter	Groups	Mean ± Std. Deviation	Mean Difference from baseline	t value	P value
Mean Gingival Index	Group I	1.292 ± 0.148	0.267 ± 0.040	6.570	<0.001*
	Group II	1.036 ± 0.153			

Table 2: Intergroup comparison of Papillary Marginal Attachment Index for Group A versus Group B for 7 days interval (Trusilk vs Epiclos)

Parameter	Groups	Mean + Std. Deviation	Mean Difference from baseline	t value	P value
Papillary Marginal Attachment Index	Group I	71.266 ± 15.438	20.733 + 5.211	3.979	<0.001*
	Group II	50.533 ± 12.999			

Table 3: Intergroup comparison of Turesky-Gilmore-Glickman modification of Quigley Hein Plaque Index for Group A versus B for 7 days interval (Trusilk vs Epiclos)

Parameter	Groups	Mean + Std. Deviation	Mean Difference from baseline	t value	P value
Turesky-Gilmore-Glickman modification of QHPI	Group I	1.260 ± 0.154	0.246 ± 0.063	3.870	0.001*
	Group II	1.014 ± 0.192			

Table 4: Intergroup comparison of Healing Index for Group A versus Group B for 7 days interval (Trusilk vs Epiclos)

Parameter	Groups	Mean + Std. Deviation	Mean Difference from baseline	t value	P value
Healing Index	Group I	1.107 ± 0.105	0.082 + 0.030	2.692	0.012*
	Group II	1.025 ± 0.052			

Table 5: Intergroup comparison for inflammatory cells for Group A versus Group B for 7 days interval (Trusilk vs Epiclos)

Parameter	Groups	Mean + Std. Deviation	Mean Difference from baseline	t value	P value
Inflammatory	Group I	22.800 ± 8.71	10.000 ± 2.591	3.858	.001*
	Group II	12.800 ± 4.98			

Table 6: Intergroup comparison for vascularity for Group A versus Group B for 7 days interval (Trusilk vs Epiclos)

Parameter	Groups	Mean + Std. Deviation	Mean Difference from baseline	t value	P value
Vasculature	Group I	6.868 ± 3.522	3.533 ± 1.021	3.459	0.002*
	Group II	3.333 ± 1.799			

butyl-cyanoacrylate is more effective. Both the treatment modalities have better score of WHI but the reduction in inflammation is more in bioadhesive group. On histological examination, number of inflammatory cells and vascularity is more in silk group as compared to bioadhesive group, whereas connective tissue fibers are more dense in bioadhesive group. On the other hand, Group B i.e., N-butyl-cyanoacrylate is more effective in reducing the clinical and histological parameters.

6. Source of Funding

None.

7. Conflict of Interest


None.

References

1. Abullais AS, Chavan A, Dani NH, Alqahtani NA, Alqahtani SM, Priyanka N. Comparative evaluation of N-butyl cyanoacrylate and silk sutures on healing of periodontal flaps: A clinical and histological evaluation. *Kathmandu Univ Med J.* 2018;63(3):253–8.
2. Knott PD, Zins JE, Banbury J, Djohan R, Yetman RJ, Papay F. A Comparison of Dermabond Tissue Adhesive and Sutures in the Primary Repair of the Congenital Cleft Lip. *Ann Plast Surg.* 2007;58(2):121–5.
3. Khurana JV, Mali AM, Mali RS, Chaudhari AU. Comparative evaluation of healing after periodontal flap surgery using isoamyl-2-cyanoacrylate (bioadhesive material) and silk sutures: A split-mouth clinical study. *J Indian Soc Periodontol.* 2016;20(4):417–22.
4. Jathal B, Trivedi A, Bhavsar N. Use of fibrin glue in periodontal flap surgery. *J Indian Soc Periodontol.* 2008;12(1):21–5.
5. Kumar MS, Natta S, Shankar G, Reddy SHK, Visalakshi D, Seshiah GV. Comparison between Silk Sutures and Cyanoacrylate Adhesive in

- Human Mucosa- A Clinical and Histological Study. *J Int Oral Health*. 2013;5(5):95–100.
6. Basil AM, Ambooken M, Mathew JJ, Thomas L. Cyanoacrylate tissue adhesives: a practical alternative to sutures? *J Ind Dent Assoc Kochi*. 2020;2(1):12–5.
 7. Joshi AD, Saluja H, Mahindra U, Halli R. A Comparative Study: Efficacy of Tissue Glue and Sutures after Impacted Mandibular Third Molar Removal. *J Maxillofac Oral Surg*. 2011;10(4):310–5.
 8. Setiya S, Halli R, Shah A, Chhabaria G, Singh T. Comparative evaluation of efficacy of tissue glue and sutures after surgical removal of impacted mandibular third molars - A prospective controlled clinical study. *J Oral Maxillofac Surg Med Pathol*. 2014;313:1–6.
 9. Chandra S, Shashikumar P, Nisha S. Comparative Evaluation of N-Butyl Cyanoacrylate with Braided Silk Suture after Periodontal Flap Surgery: A Randomized Controlled Trial. *World J Dent*. 2021;12(4):328–32.
 10. Manimegalai AG. A comparative study on the efficacy of a commercial fibrin adhesive (Tisseel) vis-à-vis silk suture on wound closure following periodontal surgical procedures. *J Indian Soc Periodontol*. 2010;14(4):231–5.
 11. Saquib AS, Chavan A, Dani NH, Al-Qahtani NA, Al-Qahtani SM, Priyanka N. Comparative Evaluation of N-Butyl Cyanoacrylate and Silk Sutures on Healing of Periodontal Flaps: A Clinico Histological Evaluation. *Kathmandu Univ Med J*. 2018;16(63):253–8.
 12. Kulkarni S, Dodwad V, Chava V. Healing of periodontal flaps when closed with silk sutures and N-butyl cyanoacrylate: A clinical and histological study. *Indian J Dent Res*. 2007;18(2):72–7.
 13. Aljasser RN, Alsarhan MA, Alotaibi DH, Aloraini S, Alnuwaiser R, Alotaibi A, et al. Comparison of Polymeric Cyanoacrylate Adhesives with Suturing in Free Gingival Graft Stability: A Split Mouth Trial. *Polymers (Basel)*. 2021;13(20):3575.
 14. Surya S, Gundannavar G, Chatterjee A. Comparative evaluation of healing after periodontal flap surgery using isoamyl 2- cyanoacrylate and silk sutures: A Split mouth clinical study. *Int J Sci Res*. 2018;7(5):31–3.
 15. rez MP, ndez IF, rquez DM, Bretan RMG. Use of N-Butyl-2-Cyanoacrylate in Oral Surgery: Biological and Clinical Evaluation. *Artif Organs*. 2000;24(3):241–3.
 16. Rewainy M, Osman S, El-Prince N. The use of n-butyl cyanoacrylate adhesive in the closure of mucoperiosteal flap after the surgical extraction of impacted mandibular third molar. *Alex Dent J*. 2015;40:152–9.
 17. Oladega AA, James O, Adeyemo WL. Cyanoacrylate tissue adhesive or silk suture for closure of surgical wound following removal of an impacted mandibular third molar: A randomized controlled study. *J Craniomaxillofac Surg*. 2019;47(1):93–8.
 18. Sagar P, Prasad K, Lalitha RM, Ranganath K. Cyanoacrylate for Intraoral Wound Closure: A Possibility? *Int J Biomater*. 2015;2015:1–6. doi:10.1155/2015/165428.
 19. Barreno AC, Vergiu CC, Malatto JR, Ramos EA, Chessa JR. Biocompatibility of n-butyl-cyanoacrylate compared to conventional skin sutures in skin wounds. *Revista Odontol Mexicana*. 2013;17(2):81–9.
 20. Vastani A, Maria A. Healing of Intraoral Wounds Closed Using Silk Sutures and Isoamyl-2-Cyanoacrylate Glue: A Comparative Clinical and Histologic Study. *J Oral Maxillofac Surg*. 2013;71(2):241–8.

Author biography

Himanshu Aeran, Director Principal, Professor & Head
 <https://orcid.org/0000-0002-7723-7108>

Amrinder Singh Tuli, Professor and Head

Ila Sharma, Post Graduate Student

Cite this article: Aeran H, Tuli AS, Sharma I. A clinico-histological comparative evaluation of healing of periodontal flaps when approximated with silk sutures and n-butyl cyanoacrylate. *Int J Oral Health Dent* 2022;8(3):222-226.