

Content available at: <https://www.ipinnovative.com/open-access-journals>

Indian Journal of Pathology and Oncology

Journal homepage: [www.ijpo.co.in](http://www.ijpo.co.in)

## Original Research Article

## Fore-arm rhabdomyosarcoma in neurofibromatosis type 1: A unique case

Vikas Kakkar<sup>1</sup>, Dheeraj Makkar<sup>2,\*</sup><sup>1</sup>Dept. of Surgery, Sri Guru Ram Das Institute of Medical Sciences and Research, Punjab, India<sup>2</sup>Dept. of Orthopedics, NC Medical College, Panipat, Haryana, India

## ARTICLE INFO

## Article history:

Received 17-05-2022

Accepted 06-06-2022

Available online 26-08-2022

## Keywords:

Rhabdomyosarcoma

Neurofibromatosis 1

Histopathology

Gorlin syndrome

## ABSTRACT

Rhabdomyosarcoma (RMS) is the commonest soft sarcoma in kids, with alveolar and embryonal variants distinguishable by histopathology and, more significantly, molecular biology. RMS occurs intermittently in a substantial proportion of cases without a predisposing condition. Nevertheless, it is well established that certain hereditary factors enhance the likelihood of developing RMS. Beckwith–Wiedemann syndrome, Gorlin syndrome, Costello, NF1, and Li Fraumeni syndromes are some of them. These syndromes present with RMS during childhood.

A 47-year-old female with NF 1 discovered a lump in her right forearm one year prior to presentation. When the patient noticed ulceration on the swelling, she sought medical attention. A tumor was detected in the center of the right forearm via MRI, and it was suspected to be a cystic or myxoid soft-tissue tumor, rhabdomyosarcoma or a peripheral neural tumor.

We classified the tumor as stage 4 due to axillary lymph node involvement and lung metastasis. Histopathology confirmed rhabdomyosarcoma. The patient then received radiotherapy and chemotherapy, and her tumor went into remission.

After confirming NF1 syndrome, we advise patients to adhere to the standard cancer screening protocol. The screening would assist in the earlier diagnosis of tumors, leading to a reduction in complications.

This is an Open Access (OA) journal, and articles are distributed under the terms of the [Creative Commons Attribution-NonCommercial-ShareAlike 4.0 License](https://creativecommons.org/licenses/by-nc-sa/4.0/), which allows others to remix, tweak, and build upon the work non-commercially, as long as appropriate credit is given and the new creations are licensed under the identical terms.

For reprints contact: [reprint@ipinnovative.com](mailto:reprint@ipinnovative.com)

## 1. Introduction

Rhabdomyosarcomas (RMS), the most frequent type of soft tissue sarcoma, constitute 4.5% of all pediatric cancers but are rare in adults.<sup>1</sup> Following Wilms tumor and neuroblastoma, it is the most prevalent extracranial solid tumor in children. RMS belongs to the primitive neuroectodermal tumors (PNET) group of tumors. These are composed of small blue round cells and include neuroblastoma and lymphoma.<sup>2</sup>

In terms of age at manifestation, there appears to be a bimodal pattern, peaking between 2-6 years and then at adolescence.<sup>3</sup> While most occurrences of RMS are

sporadic, the condition has been correlated with hereditary diseases such as Li Fraumeni. Beckwith–Wiedemann syndrome, Gorlin syndrome, Costello syndrome, Noonan syndrome, and neurofibromatosis type I.<sup>2,4</sup>

RMS has two major subcategories: alveolar and embryonic. Alveolar RMS has a distinct alveolar architecture, with tumor cells nestled between collagenous septa. Embryonic type with myoblastic and stellate cells shows an undeveloped stage of development. Additionally, two uncommon RMS subtypes consist of sclerosing or spindle-cell RMS and pleomorphic RMS.<sup>1,5</sup>

We present a unique case of spindle cell RMS in a 47-year-old female who reported to our institute with complaints of bleed and ulceration from the right forearm.

\* Corresponding author.

E-mail address: [makkardheeraj@gmail.com](mailto:makkardheeraj@gmail.com) (D. Makkar).

## 2. Case Presentation

A 47-year-old female presented to our institution with a six-month history of right forearm swelling. The swelling gradually increased in size and was painful. The patient went to a local hospital and performed a tissue biopsy from the swelling. The pathologist reported an inadequate sample from the biopsy. Fifteen days later, the swelling gradually increased after the surgery with a cut-through of sutures due to friable skin being accompanied by ulceration and bleeding (Figure 1). The patient did not report any recent traumatic event or hurt to her forearm. There was no history of weight loss, loss of appetite, or any related systemic symptoms. The patient had a family history of peripheral nerve tumors in her sister. The past history was remarkable for neurofibroma in the neck and radiation of pain to the forearm, which was relieved with conservative management. The neck neurofibroma was non-progressive and did not cause any subsequent problems. There was no relevant personal history.

### 2.1. Examination

In addition to neurofibromas, we found a firm, oval, eight-by-five-centimeter bulge was found in the middle of the right forearm. The growth edges were diffuse, and the mass appeared tethered to the underlying muscle. The ulceration measured approximately five × four centimeters and had friable margins and well edges. (Figure 1) The patient also reported increased soreness and paresthesia in her index and middle fingers commencing four days prior to her hospitalization. Similarly, we examined the forearm's radial and ulnar nerve involvement, but it was normal.

### 2.2. Diagnosis

As part of a standard laboratory evaluation, we assessed the Complete blood count, electrolytes, kidney function, liver function, and urinalysis. We also performed venous ultrasonography and an X-ray to rule out thrombosis and detect bone involvement. MRI examination of the right forearm revealed a multilobulated mass measuring 6 cm x 5.8 cm x 10.8 cm in the center of the right forearm. (Figure 2) With a more than 180 degrees contact angle, the lesion compressed the radial artery and the median nerve posteromedially. There were no bone erosions, and the tumor reached the ulceration edges through subcutaneous planes. Ultrasound of the abdomen revealed fatty degenerative signs of grade 1. Subcutaneous neurofibromas and thyroid nodules in the right lobe were spotted during a neck ultrasound. The right axillary lymph nodes were seen on the chest CT scan, with the most prominent node measuring 3.8cm x 3.2cm x 2.9cm. A calcified hilar lymph node and bilateral lung metastasis were also found; the primary lung metastasis was 4.4cm x 3.2cm x 2.8cm.

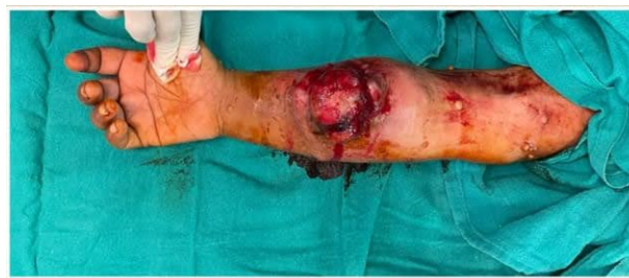We referred the patient for an ophthalmologic examination and MR imaging of the brain and spine to assess any occult malignancy. The test findings were negative for cancers.

### 2.3. Treatment

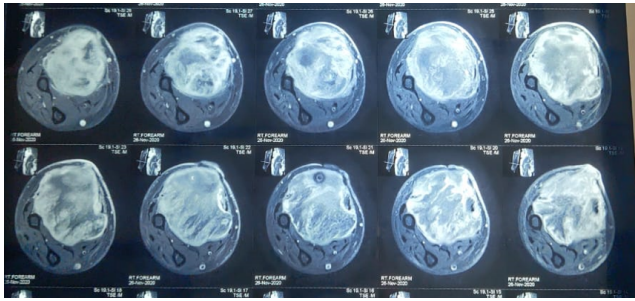
We classified rhabdomyosarcoma as stage 4 cancer according to the American Joint Cancer Committee Classification System.<sup>6</sup> We further categorized it as T2b N1M1 (stage 4) because of the involvement of the axillary lymph nodes and lung metastasis. The patient was scheduled for immediate primary resection of the tumor under general anesthesia and tourniquet control, following consultation with the Plastic surgery and Radiotherapy departments.

Following a meticulous dissection around the radial artery and median nerve via a modified Henry approach, the entire tumor was removed with a 2 cm safety margin. (Figure 4) After removal, the mass appeared grey to yellow in color and gelatinous in appearance. It measured 17cmX10cmX6.5cm. The skin defect was closed with a free flap from the ipsilateral thigh. The histopathology report revealed tumor cells arranged in a herringbone pattern, with occasionally interspersed strap cells. (Figure 7) The tumor cells were immunopositive for myogenin/myoD/desmin and negative for S100/SoX10/calponin confirming spindle cell rhabdomyosarcoma.

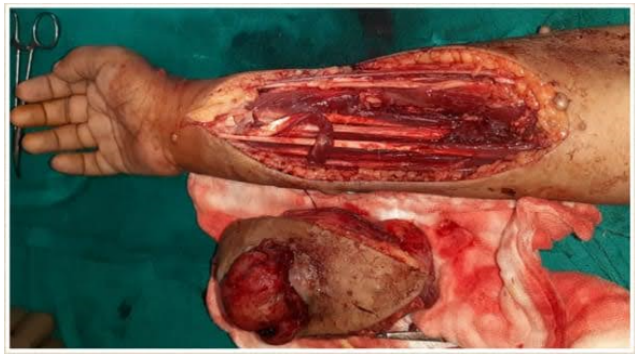After the surgery, suture removal was done after twelve days without complications. (Figure 5) The preoperative paresthesia of the patient was relieved, and she had a preserved hand function. She was advised radiation treatment for 25 days, followed by six cycles of chemotherapy. The chemotherapy cycles were scheduled every three weeks and consisted of vincristine, actinomycin-D, and cyclophosphamide (VAC) drugs. After approximately 12 weeks of standard chemotherapy, we evaluated the patients' response to treatment with an MRI. (Figure 6) The patient's repeat MRI did not show any remnant mass. The patient did not complete the chemotherapy or report for follow-up.



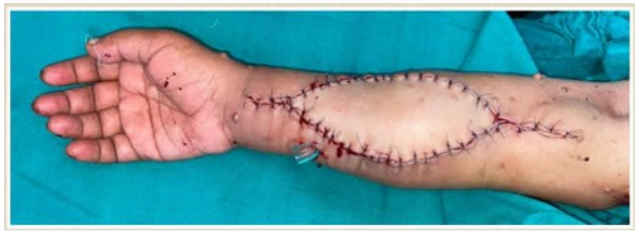**Fig. 1:** A swelling and ulceration present on the right forearm. Neurofibromas are also present



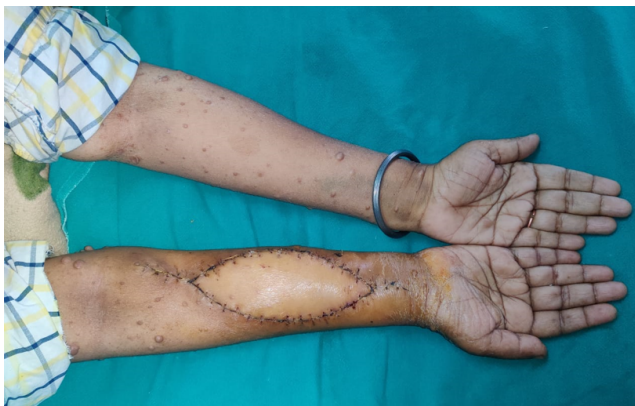**Fig. 2:** MRI of forearm showing a mass on the volar aspect of forearm



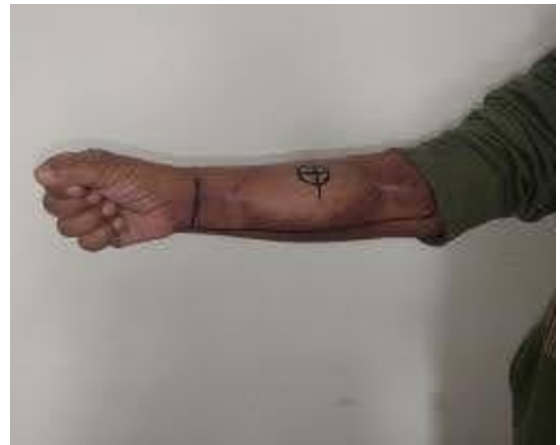**Fig. 3:** The tumor mass was excised via the modified Henry approach. The radial artery is saved, seen in the superior part of the surgical wound. Palmaris longus tendon is sacrificed



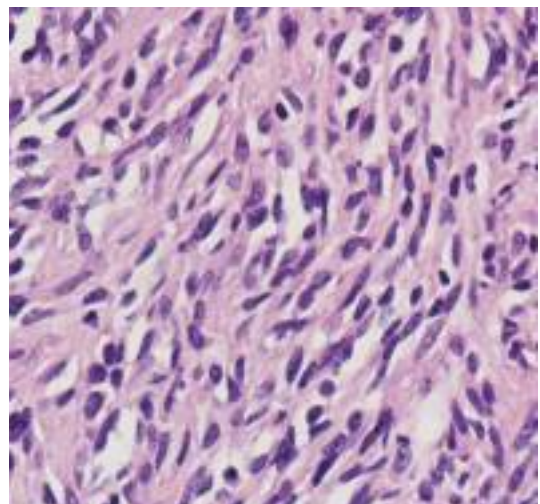
**Fig. 4:** Closure of skin gap with a free flap



**Fig. 5:** Uneventful suture removal after 12 days



**Fig. 6:** Follow-up after three months with an intact hand function



**Fig. 7:** Histopathology image showing spindle shaped cells

### 3. Discussion

Alterations in the Neurofibromin gene cause Neurofibromatosis type 1; these are encoded on the long arm of chromosome 17 and affect between 1/3000 and 4000 individuals globally.<sup>6</sup>

Clinical evaluation is the way to diagnose when at least two of the symptoms listed in Table 1 are present.<sup>7,8</sup>

Bowing of the long bones, particularly the tibia or pseudarthrosis, occurs in approximately 2% of persons with NF1<sup>9</sup> Scoliosis, osteoporosis, and non-ossifying fibroma are other orthopedic ailments affecting NF1 patients.<sup>7</sup>

Several tumors are also associated with NF1. The plexiform neurofibroma is the most common tumor and the primary cause of morbidity in NF1 patients.<sup>6</sup> NF1 is also related to various malignancies, including optic gliomas, juvenile myelomonocytic leukemia (JMML), pheochromocytomas, brain tumors, gastrointestinal stromal tumors, glomus tumors, and

**Table 1:** Diagnostic criteria for Type 1 Neurofibromatosis (NIH consensus development conference 1988)

1.	Six or more café' au lait macules (.0.5 cm in children or 1.5 cm in adults) are considered clinically significant.
2.	Two or more neurofibromas on the skin or under the skin, or one plexiform neurofibroma
3.	Freckling of the axilla or groin
4.	Glioma of the optic nerve route
5.	Greater than two Lisch nodules (iris hamartomas seen on slit-lamp examination)
6.	Osseous dysplasia (dysplasia of the sphenoid wing, bowing of long bones, pseudarthrosis)
7.	First-degree relative affected with NF1

juvenile xanthogranulomas.<sup>6</sup> The least common type of tumor in NF1 is rhabdomyosarcoma, and it occurs in the extremities in seven percent of NF1 patients.<sup>10</sup>

Rhabdomyosarcomas are mainly the tumors of children, while our patient presented in adulthood. Although the predominant type in adults is pleomorphic, the subtype present in our patient was spindle cell RMS. The spindle cell RMS is predominant in males, unlike in our case.<sup>11</sup>

### 3.1. Prognosis

Different variables, many of which are clearly delineated in the pediatric age group, influence the outcome of RMS. Favorable characteristics include histology subtype, primary anatomical site, age at onset, operative removal, occurrence or absence of metastases, and tumor size. An embryonal subtype of RMS possesses a superior outcome, while pleomorphic has a worse prognosis. A better prognosis can be attributed to the tumors located in orbits, the non-parameningeal head and neck, and the genitourinary system, urinary tract, and prostate. Patients under ten years of age fare better than adults.<sup>12</sup> Another significant element favoring the prognosis is the absence of metastases at the time of diagnosis, total gross surgical resection, and the size of less than or equal to 5 cm. The study by Little et al. reveals that the most prominent favorable prognostic factor is a size of fewer than 5 centimeters and is statistically significant.<sup>10</sup>

### 4. Conclusion

We present a rare case of rhabdomyosarcoma of the forearm in an adult with Neurofibromatosis type 1. The goal of surgical intervention should be limb preservation, if conceivable. Consequently, multidisciplinary therapy is needed. Hence, the fundamental guideline "life over limb" must be considered in malignant growth or recurrence circumstances. We recommend adequate excision and restorative techniques such as segmental bone excision and vascular reconstruction, nerve repair, grafting, and free flaps to provide optimal daily functioning.

### 5. Clinical message

The following clinical implications can be drawn from our case report. Physicians should persuade the patients to follow the recommended screening protocol for tumors after diagnosing NF1 syndrome. For pathological, biological, and cytogenetic studies, a sufficient quantity of tissue should be acquired through an open biopsy. The status and size of lymph nodes are crucial components of pre-treatment staging and have prognostic significance.

### 6. Declaration of Interest

We did not receive any specific support from funding agencies in the public, commercial, or not-for-profit entities.

### 7. Ethical Statement

We explained the procedure to the patient in her native language and obtained her approval to submit the article and accompanying photographs for publication.

### Acknowledgment


We are grateful to the Pathology Department of the SGRD Institute of Medical Sciences and Research for their outstanding work on our patient.

We also want to acknowledge the efforts of Dr. Chaitanya Bedi, the surgery resident at SGRD Institute of Medical Sciences and Research, for patient data procurement.

### References

- Agaram NP. MYOD1-mutant spindle cell and sclerosing rhabdomyosarcoma: an aggressive subtype irrespective of age. A reappraisal for molecular classification and risk stratification. *Mod Pathol.* 2019;32(1):27–36.
- Dasgupta R, Fuchs J, Rodeberg D. Rhabdomyosarcoma. *Semin Pediatr Surg.* 2016;25(5):276–283.
- Ingle KM, Cohen-Gogo S, Gupta AA. Systemic therapy in pediatric-type soft-tissue sarcoma. *Curr Oncol.* 2020;27:6–16.
- Giannikopoulos P, Parham DM. Rhabdomyosarcoma: How Advanced Molecular Methods Are Shaping the Diagnostic and Therapeutic Paradigm. *Pediatr Dev Pathol.* 2021;24(5):395–404.
- Demellawy DE, McGowan-Jordan J, Nanassy JD, Chernetsova E, Nasr A. Update on molecular findings in rhabdomyosarcoma. *Pathology.* 2017;49(3):238–246.
- C P, H T, Im F, Dn C, U. The NF1 somatic mutational landscape in sporadic human cancers. *Human genomics.* 2017;11(1).
- Ferner RE. Guidelines for the diagnosis and management of individuals with neurofibromatosis 1. *J Med Genet.* 2007;44(2):81–88.
- "Neurofibromatosis. Conference statement. National Institutes of Health Consensus Development Conference. vol. 45; 1988.
- Br K. Diagnostic outcome in children with multiple café au lait spots. *Pediatrics.* 1992;90(6).
- Little DJ. Adult rhabdomyosarcoma: outcome following multimodality treatment. *Cancer.* 2002;95(2):377–388.
- RI L, Eh S, Ed H. PLEOMORPHIC RHABDOMYOSARCOMATA OF THE EXTREMITIES AND LIMB GIRDLES: A CLINICOPATHOLOGICAL STUDY. vol. 47. Accessed; 1965. Available from: <https://pubmed.ncbi.nlm.nih.gov/14299664/>.

12. Ruiz-Mesa C, Goldberg JM, Munoz AJC, Dumont SN, Trent JC. Rhabdomyosarcoma in adults: new perspectives on therapy. *Curr Treat Options Oncol*. 2015;16(6):27–27.

**Dheeraj Makkar**, Assistant Professor  <https://orcid.org/0000-0002-8498-7935>

### Author biography

**Vikas Kakkar**, Associate Professor

**Cite this article:** Kakkar V, Makkar D. Fore-arm rhabdomyosarcoma in neurofibromatosis type 1: A unique case. *Indian J Pathol Oncol* 2022;9(3):261-265.