

Content available at: <https://www.ipinnovative.com/open-access-journals>

Indian Journal of Pathology and Oncology

Journal homepage: www.ijpo.co.in

Case Report

Secretory carcinoma of the breast- A rare case report

G Gopu¹, Bharathi Vidya Jayanthi², S Palaniraj^{3,*}

¹Dept. of Surgical Oncology, Madras Medical College, RGGGH, Chennai, Tamil Nadu, India

²Dept. of Pathology, Institute of Pathology, Madras Medical College, RGGGH, Chennai, Tamil Nadu, India

³Dept. of General Surgery, Madras Medical College, RGGGH, Chennai, Tamil Nadu, India



ARTICLE INFO

Article history:

Received 04-12-2021

Accepted 03-02-2022

Available online 28-05-2022

Keywords:

Oncology treatment

Secretory carcinoma

ABSTRACT

Secretory carcinoma of breast represent a rare subtype of carcinoma breast with a incidence of less than 0.15%. Though initially thought to be limited to children. Later it was recognised that it may occur in adult as well. It has an indolent course and carries favourable prognosis. It is a slow growing tumour and it is associated with good long-term survival. Breast imaging usually mimics a benign tumour. Immunohistochemistry and cytogenetic analysis of tumour are crucial for confirmation of SBC. Currently there is no established guidelines regarding the best treatment strategy for patients with SBC. BCS with sentinel nodes biopsy is at present the first choice treatment. Further research for identification of the specific gene mutation may pave for targeted molecular therapies for this disease.

This is an Open Access (OA) journal, and articles are distributed under the terms of the [Creative Commons Attribution-NonCommercial-ShareAlike 4.0 License](https://creativecommons.org/licenses/by-nc-sa/4.0/), which allows others to remix, tweak, and build upon the work non-commercially, as long as appropriate credit is given and the new creations are licensed under the identical terms.

For reprints contact: reprint@ipinnovative.com

1. Introduction

Secretory carcinoma of breast represent a rare subtype of carcinoma breast with a incidence of less than 0.15%.¹ WHO has defined the secretory carcinoma as a “A rare low grade Translocation associated invasive carcinoma with a solid microcystic & tubular architecture composed of cells that produce intracellular & extracellular secretory material.”² Initially this was referred as juvenile breast carcinoma due to earlier reports stating increased incidence in children. Later it was recognized that it may occur in adult as well.³ This tumour is usually negative for hormone receptors & don't express HER2 receptors.⁴ This carcinoma has a indolent course even in setting with nodal metastasis & carries a favourable prognosis.

2. Case Report

18 year old female presented with Lump in left breast for 10 years. Clinical examination revealed a firm mass in outer quadrant of size 8*8cm with skin fixity. No nodes were palpable in Axilla. Right side breast was normal. FNAC revealed fibroadenosis with extensive fibrocystic changes. MRI showed an ill-defined lesion with diffusion restriction and low ADC. The solid lesion showed heterogenous enhancement on contrast administration Suggestive of Phylloides tumour. So the patient was proceeded with wide local excision of the tumour along with the involved skin. Post operative histopathology revealed a neoplasm arranged in papillary, pseudopapillary, glandular, microglandular and solid pattern with marked extracellular and luminal eosinophilic secretion seen throughout the tumour. Dense sclerotic stroma extending in between tumour cell identified. Tumour cells were infiltrating into stroma showing desmoplasia and lymphocytic infiltration hemosiderin laden

* Corresponding author.

E-mail address: tmbsuresh@gmail.com (S. Palaniraj).

macrophages and hemorrhage. Immunohistochemistry revealed strong positive for S-100 and mammoglobin. Tumour showed moderate positive in focal areas for CD 56 and membranous positive for E cadherin. Tumour showed negative for CA 125, TTF, WT-1, CK 20, p63. Regarding hormonal receptor status, It showed weak to moderate positive for ER and PR . Negative for HER2. Ki67 less than 5%. Diagnosis of secretory carcinoma of breast was made with the above mentioned pathological evidences. Later patient was managed with modified radical mastectomy with breast reconstruction.

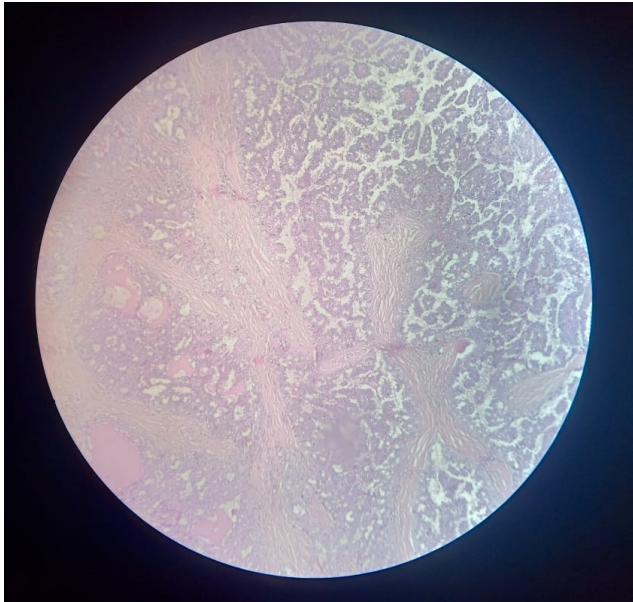


Fig. 1:

3. Discussion

Secretory carcinoma of breast is an extremely rare entity of breast malignancy. It can involve individual of any age group ranging from 3 to 87 years old with the average age of presentation being 33 years of age.⁵ This disease has a more preponderance towards female with male female ratio being 1:6. But the nature of this tumour is found to be more aggressive in men than female as per latest reports. This tumour has an indolent course presenting as a painless slow growing well defined mass predominantly involving subareolar region with the average size of the tumour being 3cm. 15% of the individual will have nodal involvement at the time of diagnosis as per some literature.⁶ Though uncommon, distant metastasis at presentation has also been observed.⁷ Sonographic findings include a hypochoic round or oval or tubular mass, microlobulated, usually single closely mimicking a benign tumour or well-circumscribed carcinoma. In mammography, SBC usually presents as a distinctly spiculated lesion or as a discrete, lobulated, solitary mass with smooth or irregular borders,

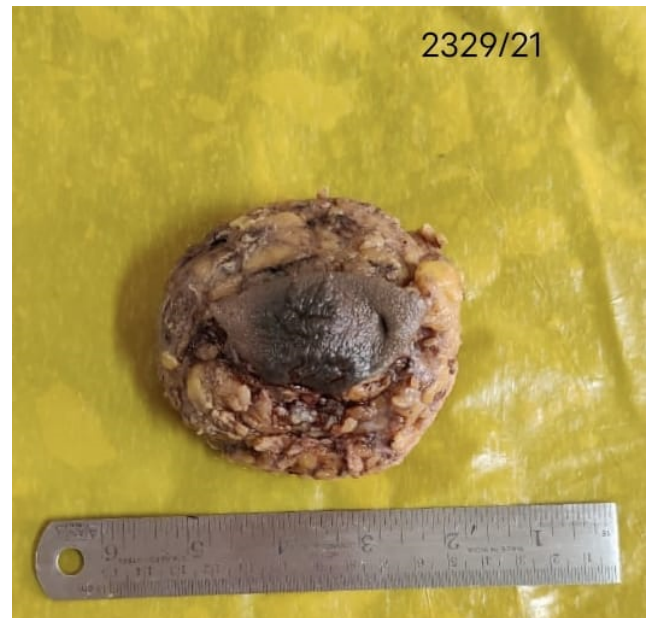

Fig. 2:

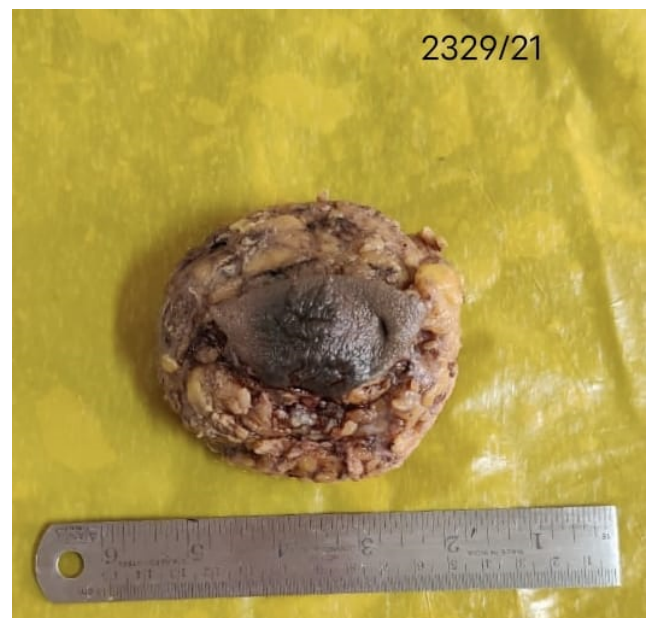

Fig. 3:

which may mimic a fibroadenoma.⁸ The typical slow growth of the tumour and non specific findings in imaging makes the diagnosis of SBC a challenging one. There are wide range of conditions which can mimic SBC which includes various benign conditions and malignant tumours (mucinous carcinoma, and apocrine carcinoma, cystic hypersecretory hyperplasia, juvenile papillomatosis with apocrine metaplasia, etc).

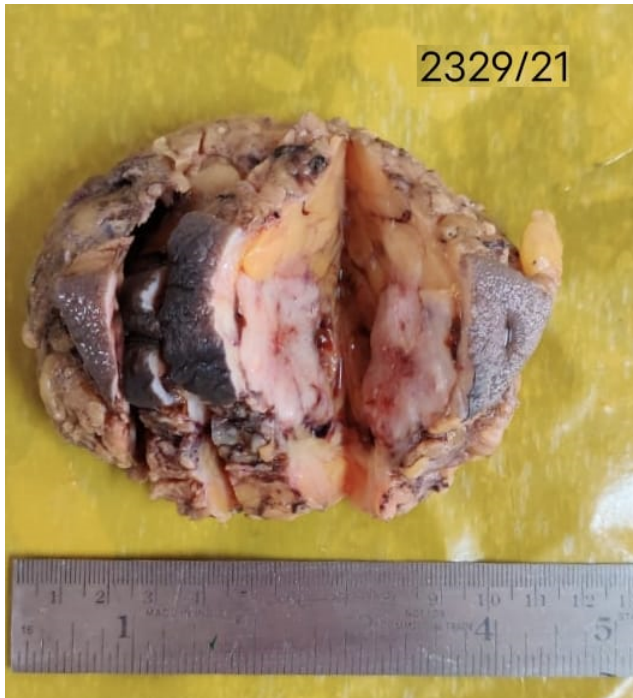


Fig. 4:

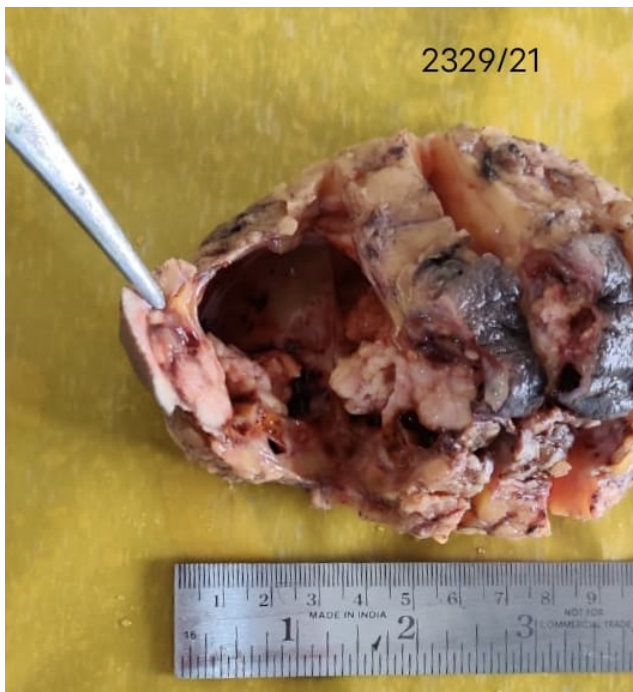


Fig. 5:

Lack of myoepithelial cells on tissue biopsy may be used to differentiate secretory carcinoma breast from other differential diagnosis. Various cytological patterns have been observed in secretory carcinoma breast which includes microcystic, ductal, solid and sometimes involving all the three pattern. The tumor cells are polygonal with granular eosinophilic cytoplasm. This tumour has a characteristically low mitotic activity with very minimal or no atypia. Granular eosinophilic cytoplasm and intra or extracellular secretion of the tumour cells are the two distinct cytopathological features of secretory carcinoma breast. Further analysis reveals the intra and extracellular secretions of tumour is found to be mucicarmine and PAS positive with diastase resistant. Though it may look well circumscribed clinically and during macroscopic examination, foci of invasion into the surrounding breast tissue has been noticed along with the features of ductal carcinoma insitu which can lead to local recurrence if the tumour is not completely excised. The significance of Fine needle aspiration cytology has been well established in pediatric age group while it is of little use in adult. Core needle biopsy has been preferred in adults.

The IHC markers of secretory carcinoma Breast is usually found to be triple negative⁸ along with recently identified t (12;15) ETV6 - NTRK3 balanced translocation fusion gene. This balanced translocation is recognized as first of its kind to be identified in a breast carcinoma and is well known to be recognized with two morphologically similar mesenchymal tumour of pediatric age group i.e., mesoblastic nephroma and congenital fibrosarcoma. SBC is associated with a characteristic balanced translocation, t(12;15) (p13;q25). This translocation is known to be oncogenic also in another types of neoplasia. It affects genes ETV6 (TEL) on the chromosome 12 and NTRK3 (TRKC) on the chromosome 15. The most often it leads to the breakage in the intron 5 of the gene ETV6 and the intron 15 of the gene NTRK3 which forms a fusion gene; or more accurately a protein, which has an N-terminal helix-loop-helix (HLH) domain of the highly expressed transcription factor ETV6 linked to tyrosine kinase domain of the gene NTRK3. The ligand dependent HLH based dimerization of the chimeric protein followed by the activation of NTRK 3 tyrosine kinase domain takes place. This activated tyrosine kinase, further, through various of signal pathways plays a predominant role in the cell transformation. The differential diagnosis with acinic carcinoma is based on the absence of the ETV6-NTRK3 translocation in acinic carcinomas. The primary modality of treatment for secretory carcinoma breast is surgery; but, due to lack of proper reports and rare incidence, There is no proper protocol for the management of this tumour. In the view of late local recurrence, many has advocated mastectomy as treatment of choice for these patients.⁹ Breast Conservative surgery with later reconstructive procedure is found to be of greater

benefit particularly in younger patients in whom breast development has not been completed. The incidence of axillary lymph node involvement is identified to be around 30% regardless of the gender. So an axillary lymph node dissection is highly recommended for the tumour more than 2cm.¹⁰ Recent reports suggest the sentinel node biopsy to be more useful in decision making prior to node dissection. Chemotherapy and radiotherapy have been tried for SBC but found to be of little use. This seems to be a peculiar feature as congenital fibrosarcomas and mesoblastic nephromas are highly sensitive to traditional chemotherapeutic drugs. Currently the above mentioned treatment options are reserved only for SBC presenting at advanced stage. The identification of the specific genetic mutation may be helpful for gene based molecular therapies for this tumour.

4. Conclusion

Although SCBs are generally associated with a favorable prognosis, our study and review demonstrate that a subset of SCBs may develop distant metastases. Further studies are warranted to identify markers predictive of more aggressive clinical behavior in this rare breast cancer subtype.

5. Source of Funding

The authors declare no conflict of interest.

6. Conflict of Interest

None.

References

1. Laé M, Fréneaux P, Sastre-Garau X, Chouchane O, Sigal-Zafrani B, Vincent-Salomon A. Secretory breast carcinomas with ETV6-NTRK3 fusion gene belong to the basal-like carcinoma spectrum. *Mod Pathol.* 2009;22(2):291–8.
2. Lakhani SR, Ellis IO, Schnitt SJ, Tan PH, van de Vijver M. WHO Classification of Tumours of the Breast. 4th ed. Lyon: IARC; 2012.
3. Tavassoli FA, Norris J. Secretory carcinoma of the breast. *Cancer.* 1980;45(9):2404–13.
4. Amott DH, Masters R, Moore S. Secretory carcinoma of the breast. *Breast J.* 2006;12(2):183.
5. Kawase K, Iwase K, Miyakawa S. A case of secretory carcinoma of the breast in an elderly Japanese woman. *Gan No Rinsho.* 1989;35(8):943–947.
6. Vieni S, Cabibi D, Cipolla C, Fricano S, Graceffa G, Latteri MA. Secretory breast carcinoma with metastatic sentinel lymph node. *World J Surg Oncol.* 2006;4:88. doi:10.1186/1477-7819-4-88.
7. Tavassoli FA, Devilee P. World Health Organization Classification of Tumors. In: Tumors of the Breast and Female Genital Organs. Lyon, France: IARC Press; 2003.
8. Lee SG, Jung SP, Lee HY, Kim S, Kim HY, Kim I, et al. Secretory breast carcinoma: a report of three cases and a review of the literature. *Oncol Lett.* 2014;8(2):683–6.
9. Arce C, Cortes-Padilla D, Huntsman DG. Secretory carcinoma of the breast containing the ETV6-NTRK3 fusion gene in a male: case report and review of the literature. *World J Surg Oncol.* 2005;3:35.
10. Richard G, Hawk JC, Baker AS, Austin RM. Multicentric adult secretory breast carcinoma: DNA flowcytometric findings, prognostic features, and review of the world literature. *J Surg Oncol.* 1990;44(4):238–44.

Author biography

G Gopu, HOD

Bharathi Vidya Jayanthi, HOD

S Palaniraj, General Surgeon  <https://orcid.org/0000-0002-3740-4530>

Cite this article: Gopu G, Jayanthi BV, Palaniraj S. Secretory carcinoma of the breast- A rare case report. *Indian J Pathol Oncol* 2022;9(2):173-176.