

Content available at: <https://www.ipinnovative.com/open-access-journals>

Indian Journal of Obstetrics and Gynecology Research

Journal homepage: www.ijogr.org

Case Report

Interesting case of dyspnea during COVID-19 pandemic

Isha Nandal^{1,*}, Rajvir Kaur¹, S P S Kochar¹

¹Dept. of Obstetrics & Gynaecology, SGT Medical College, Gurugram, Haryana, India



ARTICLE INFO

Article history:

Received 15-09-2021

Accepted 12-01-2022

Available online 08-11-2022

Keywords:

Dyspnea

Mitral stenosis

Pregnancy

COVID- 19

ABSTRACT

Dyspnea in pregnancy may be due to causes other than COVID-19 infection also and these should not be ignored. Various causes include exacerbation of asthma, cardiac illnesses, severe anaemia etc. Complication risk depends on type and severity of the underlying pathology. Mitral stenosis (MS) is the most common acquired valvular heart disease seen in pregnant women and is mostly rheumatic in origin. We report a case of 29-year-old female with 38 weeks gestation who presented with complain of shortness of breath and coughing for one week. She was diagnosed as case of severe mitral stenosis and moderate pulmonary hypertension with congestive heart failure (NYHA IV). This case highlights the importance to rule out the other causes of dyspnea like severe anemia and cardiac diseases even in patients with suspicion of COVID-19 infection. All respiratory symptoms should not be ascribed to COVID-19 infection and proper evaluation of patients should be conducted.

This is an Open Access (OA) journal, and articles are distributed under the terms of the [Creative Commons Attribution-NonCommercial-ShareAlike 4.0 License](https://creativecommons.org/licenses/by-nc-sa/4.0/), which allows others to remix, tweak, and build upon the work non-commercially, as long as appropriate credit is given and the new creations are licensed under the identical terms.

For reprints contact: reprint@ipinnovative.com

1. Introduction

Pregnant women are particularly at risk for poor outcomes as a result COVID-19 infection. Not only the disease itself can result in severe illness but diagnosing the underlying condition can also become challenging due to the risk of spread of COVID-19. Dyspnea in pregnancy may be due to causes other than COVID-19 infection also and these should not be ignored. Various causes include exacerbation of asthma, cardiac illnesses, severe anaemia etc. Complication risk depends on type and severity of the underlying pathology. Mitral stenosis (MS) is the most common acquired valvular heart disease seen in pregnant women and is mostly rheumatic in origin. Other causes of valvular heart disease include mitral valve prolapse, prior endocarditis and valvular disease associated with disorders like systemic lupus erythematosus, marfan's syndrome and inflammatory vascular disorders.¹

Risk of developing complications in patients of mitral stenosis increases in pregnancy as a result of altered physiology like increased cardiac output, heart rate and intravascular volume along with decreased systemic vascular resistance.² Here we report a case of 29-year-old female with 38 weeks gestation who presented with shortness of breath and cough for one week.

2. Case Report

We report a case of 29-year-old female with 38 weeks gestation who presented with complain of shortness of breath and coughing for one week. There was no history of any symptoms before this during pregnancy and no significant past history of any chronic illness. On examination her BP- 110/60, PR- 90 regular, RR- 16/min, Temp- afebrile, CVS- parasternal heave present, grade 3/4 middiastolic rumbling murmur at mitral area and loud P2. Although the suspicion of COVID-19 infection was there due to positive history of close contact but her COVID-19

* Corresponding author.

E-mail address: ishadahiya2018@gmail.com (I. Nandal).

RT-PCR came negative. She gave no history suggestive of previous rheumatic fever episodes. There was no significant obstetric history in the past. ECG showed sinus tachycardia, right bundle branch block (RBBB), right axis deviation and biatrial enlargement (Figure 1).

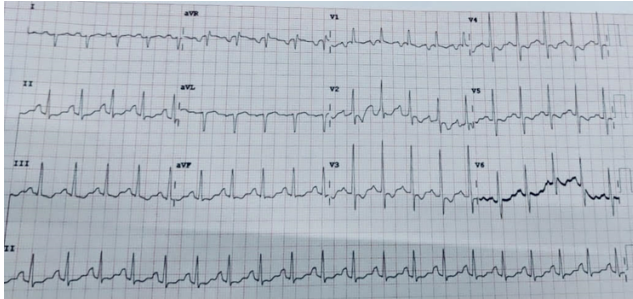


Fig. 1: ECG showing sinus tachycardia, RBBB, right axis deviation and biatrial enlargement

Cardiology consultation was taken. She was diagnosed as case of severe mitral stenosis and moderate pulmonary hypertension with congestive heart failure (NYHA IV). Normally, mitral valve orifice area is 4 to 5 cm² by planimetry in 2 D echocardiography (Figure 2). Our patient had valve area of just 0.76 cm². In view of her deteriorating condition, she underwent emergency LSCS. She gave birth to a healthy baby and is planned for PTMC procedure on follow up.

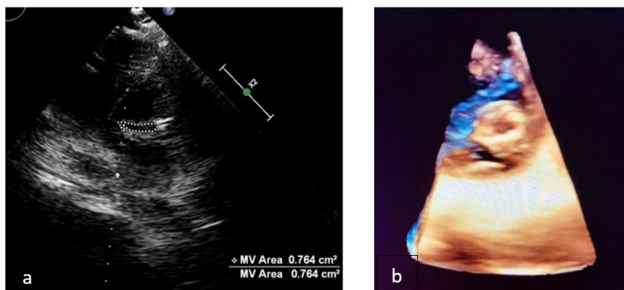


Fig. 2: a: 2D Echo PSAX view showing Severe Mitral Stenosis; b: 3D Echo showing severe mitral stenosis

3. Discussion

Mitral stenosis is the most common heart disease found to be complicating pregnancy in tertiary care hospitals of India.³ Symptomatic severe mitral stenosis is one of the WHO Risk Class IV categories under the Classification of Maternal Cardiovascular Risk. Severe mitral stenosis is mostly poorly tolerated in pregnancy because of significant increases in plasma volume and heart rate. Although MS frequently follows acute rheumatic fever episodes, fewer than half of patients with MS remember contracting rheumatic fever. Risks of fetal complications like premature

birth and intrauterine growth restriction is also higher in these patients.⁴

Regarding the mode of delivery, for most patients with cardiac disease, vaginal delivery is feasible and preferable due to association of fewer complications. However, some conditions warrant cesarean delivery like patient anticoagulated with warfarin or suffering from severe heart failure, dilated aorta, severe pulmonary hypertension or aortic stenosis. 67% of patients with severe mitral stenosis develop peripartum heart failure even if previously asymptomatic.^{5,6}

Management of these patients include beta blockers, diuretics and bed rest. Ideally percutaneous transvenous mitral commissurotomy (PTMC) is recommended before conception as it remains a high risk procedure during pregnancy. The intrapartum PTMC is indicated only in persistently symptomatic patients with suitable valvular anatomy and are in second or third trimester.⁷ Combined valvular pathologies like mitral stenosis with mitral regurgitation require surgical valve replacements and are not amenable to percutaneous interventions. With the advancement in therapeutic options, the mortality rate of pregnant women with cardiac diseases is lower in mitral stenosis in comparison to other heart diseases like Eisenmenger's syndrome, Marfan's syndrome with aortopathy and pulmonary vascular obstructive disease.⁸

4. Conclusion

This case highlights the importance to rule out the other causes of dyspnea like severe anemia and cardiac diseases even in patients with suspicion of COVID-19 infection. All respiratory symptoms should not be ascribed to COVID-19 infection and proper evaluation of patients should be conducted. Education patients is necessary to decrease maternal and fetal mortality. A multidisciplinary approach in diagnosis and management is needed to treat cardiac diseases complicating pregnancy.

5. Source of Funding

None.

6. Conflict of Interest

None.

References

1. Thorne S. Pregnancy and native heart valve disease. *Heart*. 2016;102(17):1410–7.
2. Tsiaras S, Poppas A. Mitral valve disease in pregnancy: outcomes and management. *Obstet Med*. 2009;2(1):6–10.
3. Bhatla N, Lal S, Behera G. Cardiac disease in pregnancy. *Int J Gynaecol Obstet*. 2003;82(2):153–9.
4. Silversides C, Colman J, Sermer M, Siu S. Cardiac Risk in Pregnant Women with Rheumatic Mitral Stenosis. *Am J Cardiol*. 2003;91(11):1382–5.

5. Hagen IV, Thorne S, Taha N, Youssef G, Elnagar A, Gabriel H, et al. Pregnancy outcomes in women with rheumatic mitral valve disease. Results from the Registry of Pregnancy and Cardiac Disease. *Circulation*. 2018;137(8):806–16.
6. Youssef G. Mitral stenosis in pregnant patients. *J Cardiol Pract*. 2018;16:1–6.
7. Firouzi A, Samiei N, Ahmadi S, Naderi N, Sadeghipour P, Sanati HR, et al. Percutaneous Transluminal Mitral Commissurotomy in Pregnant Women with Severe Mitral Stenosis. *Tehran Heart Cent*. 2019;14(1):12–7.
8. Sawhney H, Aggarwal N, Suri V, Vasishta K, Sharma Y, Grover A. Maternal and perinatal outcome in rheumatic heart disease. *Int J Gynaecol Obstet*. 2003;80:9–14.

Author biography

Isha Nandal, PGT

Rajvir Kaur, PGT

S P S Kochar, Professor and HOD

Cite this article: Nandal I, Kaur R, Kochar SPS. Interesting case of dyspnea during COVID-19 pandemic. *Indian J Obstet Gynecol Res* 2022;9(4):558-560.