

Content available at: <https://www.ipinnovative.com/open-access-journals>

Indian Journal of Obstetrics and Gynecology Research

Journal homepage: [www.ijogr.org](http://www.ijogr.org)

## Case Report

# A rare case report of anterior vaginal wall cyst

J Jayasree<sup>1</sup>, S S R Mudanur<sup>1,\*</sup>, Eshwer Chand A<sup>1</sup>

<sup>1</sup>Dept. of Obstetrics and Gynaecology, Shri B.M. Patil Medical College, BLDE (DU), Vijayapura, Karnataka, India



### ARTICLE INFO

#### Article history:

Received 23-01-2022

Accepted 21-02-2022

Available online 20-05-2022

#### Keywords:

Benign

Excision

Mucinous cyst

Vagina

### ABSTRACT

**Background:** Vaginal wall mucinous cyst is very rare benign condition, and it is non-invasive in nature, it can be mistaken as urethral diverticulum, inclusion cyst, Gartner cyst. Cyst may cause symptoms if it increase in size then cyst excision is the treatment of choice.

**Case Report:** 35 yrs old woman presented with chief complaints of mass per vaginam since 6yrs, white discharge per vaginam since 6yrs, difficulty in micturation since 6 months, dysparunia since 3 months, on examination diagnosis is second degree UV prolapsed with cervicitis with cystocele and rectocele with anterior vaginal wall cyst, vaginal hysterectomy with cystocele and rectocele repair with excision of anterior vaginal wall cyst specimen sent for HPR and shows uterus with cervicitis with ulceration, secretory endometrium and benign mucinous cyst of ant vaginal wall.

**Conclusion:** Vaginal wall mucinous cyst is rare condition, cyst is completely excised but long term surveillance to be done for recurrence.

This is an Open Access (OA) journal, and articles are distributed under the terms of the [Creative Commons Attribution-NonCommercial-ShareAlike 4.0 License](https://creativecommons.org/licenses/by-nc-sa/4.0/), which allows others to remix, tweak, and build upon the work non-commercially, as long as appropriate credit is given and the new creations are licensed under the identical terms.

For reprints contact: [reprint@ipinnovative.com](mailto:reprint@ipinnovative.com)

## 1. Introduction

Vaginal cysts are rare and diagnosed incidentally, cystic lesion may arise from all the vaginal walls, usually from lateral vaginal walls and rarely may extended into fornix. Depending upon histopathology cyst are classified into squamous inclusion cyst, mesonephric or gartners duct cyst, mullerian or paramesonephric cyst, bartholian cyst.<sup>1,2</sup> The cyst may present with different sign and variety of symptoms. Here we are presenting a rare case report of anterior vaginal wall cyst.

## 2. Case Report

A patient of 35 years old woman presented to OPD with complaining of mass per vaginam since 6yrs, white discharge per vaginam since 6yrs, difficulty in micturation since 6 months, dyspareunia sine 3months. Patient had no

previous medical disorders and surgical operations. attain menarche at the age of 13 yrs, with regular menstrual cycle and LMP 45 days back, she is para 3 living 3, with marital life 15 yrs, and her last child birth 8 yrs back.

On General physical examination vitals signs are normal, cardiac and respiratory system is normal. On per abdomen examination –abdomen is soft, non tender, no palpable mass is palpated. On per speculum examination-white discharge is seen, uterine prolapse is seen.

On per vaginal examination-UV prolapse of 2<sup>nd</sup> degree is noted, with a cyst of size 5\*4cm is palpated at left anterior and left lateral wall of the vagina at the level of mid vagina, which is cystic in nature and non tender.

### 2.1. Diagnosis

Second degree UV prolapse with cervicitis with cystocele and rectocele with anterior vaginal wall cyst.

\* Corresponding author.

E-mail address: [dr.jayasreedy.j@gmail.com](mailto:dr.jayasreedy.j@gmail.com) (S. S. R. Mudanur).

## 2.2. Management

All the investigation of the patients are with in normal limit and posted for surgery vaginal hysterectomy with urethrocele and rectocele repair with cyst excision.

Intra operative-on dissection of cyst- thick, chocolate colour mucinous secretions are seen.

There are no post-operative complications.

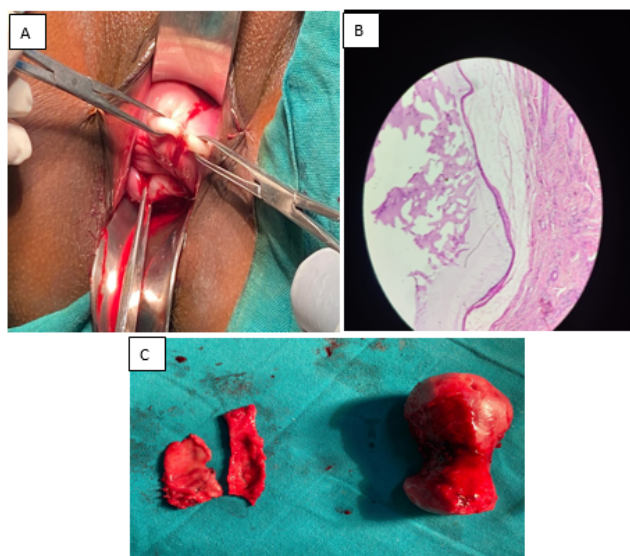
## 2.3. Histo-pathology report

Gross Morphology- Uterus measure 7\*4\*4cm, Cervix is congested, Cyst wall of size 5cm is seen Microscopy-cervix –Chronic cervicitis, Noatypia seen Endometrium – Secretory, no malignancy CYST WALL-Shows columnar epithelium over fibrocollagenous wall.

## 2.4. Impression

Chronic cervicitis with ulceraton, Secretory endometrium (hysterectomy specimen).

Anterior vaginal wall- Benign mucinous cyst.



**Fig. 1:** A: Intraoperative image of vaginal wall cyst; B: Microscopic section of vaginal wall cyst; C: Cut section of vaginal wall cyst

## 3. Discussion & Conclusion

Most of the vaginal cyst are asymptomatic and treatment is not needed prevalence is 1 in 200<sup>3</sup> patient may complain of mass per vaginum, vaginal discomfort, dyspareunia, vaginal pain. The vaginal wall cyst should be differentiated from cystocele and rectocele by examination location of the cyst excludes from Bartholin's cyst endometriotic cyst should be ruled out by absence of cyclical abdominal pain during menstrual cycle.

Mullarian cyst are the most common cyst seen in the vaginal wall, mostly they are located anteriolaterally, usually single sometimes multifocal.<sup>4,5</sup> During embryonic development paramesonephric duct (mullarian duct) fuses distally and forms uterus, cervix and upper part of vagina, these are lined by pseudostratified columnar epithelium mesonephric duct (wolffian duct) regress in females the derivatives of these ducts seen with in the vaginal walls.

Gartner's cyst is less common, most commonly seen anteriolateral vaginal walls and it is associated with abnormalities of metanephric duct like ectopic ureter, unilateral ureter and renal hypoplasia.<sup>6,7</sup>

Gartner's cyst contain basement membrane and smooth muscle layer. Clear distinguish from mesonephric and paramesonephric duct by histochemical staining paramesonephric cyst mucin and periodic acid schiff positive, mesonephric duct are devoid of they are negative.<sup>6</sup>

Transvaginal ultrasound and magnetic resonance imaging is done to see exact location, number and its extension,<sup>8</sup> MRI is imaging modality of choice to know characteristic of the tumour<sup>6</sup> treatment includes surgical excision of the cyst it may include incision and drainage or marsupialization of the cyst, during surgery injury should be avoided to urethra and bladder usage of laser reduces complication like post-operative pain, dyspareunia and hemorrhage.

This is a rare case of benign mucinous cyst of anterior vaginal wall.

## 4. Source of Funding

None.

## 5. Conflict of Interest

The authors declare no conflict of interest.

## References

- Pradhan S, Tobon H. Vaginal cysts: a clinicopathological study of 41 cases. *Int J Gynecol Pathol.* 1986;5(1):35–46.
- Junaid TA, Thomas SM. Cysts of the vulva and vagina: a comparative study. *Int J Gynaecol Obstet.* 1981;19(3):239–43.
- Kondi-Pafiti A, Grapsa D, Papakonstantinou K, Kairi-Vassilatou E, Xasiakos D. Vaginal cysts: a common pathologic entity revisited. *Clin Exp Obstet Gynecol.* 2008;35(1):41–4.
- Wai CY, Corton MM, Miller M, Sailors J, Schaffer JJ. Multiple vaginal wall cysts: diagnosis and surgical management. *Obstet Gynecol.* 2004;103(5 Pt 2):1099–102.
- Hwang JH, Oh MJ, Lee NW, Hur JY, Lee KW, Lee JK. Multiple vaginal mullerian cysts: a case report and review of literature. *Arch Gynecol Obstet.* 2009;280(1):137–9.
- Eilber KS, Raz S. Benign cystic lesions of the vagina: a literature review. *J Urol.* 2003;170(3):717–22.
- Montella JM. Vaginal mullerian cyst presenting as a cystocele. *Obstet Gynecol.* 2005;105(5 Pt 2):1182–4.
- Pradhan J, Tobon H. Vaginal cysts: a clinicopathological study of 41 cases. *Int J Gynecol Pathol.* 1986;5(1):35–46.

## Author biography

**J Jayasree**, Junior Resident  <https://orcid.org/0000-0001-6181-6589>

**S S R Mudanur**, Professor

**Eshwer Chand A**, Intern

**Cite this article:** Jayasree J, Mudanur SSR, Chand A E. A rare case report of anterior vaginal wall cyst. *Indian J Obstet Gynecol Res* 2022;9(2):305-307.