

Content available at: <https://www.ipinnovative.com/open-access-journals>

Indian Journal of Clinical and Experimental Ophthalmology

Journal homepage: [www.ijceo.org](http://www.ijceo.org)

## Original Research Article

## A clinical study to evaluate recurrence of pterygium after primary surgery and its management

Shweta Walia<sup>1</sup>, Divya Khandelwal<sup>1,\*</sup>, Neetu Kori<sup>1</sup>, Vijay Bhaisare<sup>1</sup>, Preeti Rawat<sup>1</sup>, Manushree Gautam<sup>1</sup><sup>1</sup>Dept. of Ophthalmology, MGM Medical College, Indore, Madhya Pradesh, India

## ARTICLE INFO

## Article history:

Received 18-07-2021

Accepted 16-09-2021

Available online 31-03-2022

## Keywords:

Recurrence

Pterygium

Conjunctival limbal autograft

Histopathology

Mitomycin C

## ABSTRACT

**Background:** Recurrence is a significant problem after pterygium excision. Therefore in this study its risk factors and management is discussed.**Aims:** This study was conducted to observe recurrence after conjunctival limbal autograft (CLAU) & to evaluate different factors related with recurrence of pterygium and assessing its different management methods.**Materials and Methods:** Hundred & seven patients with primary pterygium were examined, excised by CLAU and histopathology sample sent. The outcomes were assessed in terms of clinically significant recurrence till 6 months follow-up. Early topical mitomycin-C (MMC) 0.02% QID for a week was given to avoid resurgence of clinically significant pterygium, however if developed then excised by CLAU (if <4mm) or AMG (Amniotic membrane grafting) (if > 4mm).**Results:** Out of total cases, 57% were females. Histopathology findings include Epithelial Hyperplasia (80.4%), vascularity overwhelms fibrosis (39.1%), vascularity similar to fibrosis (28.3%), fibrosis overwhelms vascularity (34.8%), perivascular stromal inflammation (54.3%), diffuse stromal inflammation (37.0%). The following variables were significantly associated (p<0.05) with the recurrence: age, redness & thickness, higher vascularity, diffuse inflammation.**Conclusions:** Factors such as younger age group, higher redness and thickness of pterygium, more vascularity, and diffuse inflammation on histopathological examination can be considered as a risk factor for recurrence. However, occupation, location, and type of pterygium were found not to be related to recurrence. Although no clinically significant recurrence was seen after mitomycin c eyedrops, but no significant correlation can be made.**Key Messages:** Young patients having pre-operative features like red and fleshy pterygium, along with vascularity more than fibrosis and diffuse inflammation on histopathological examination should be followed strictly and managed intensely.This is an Open Access (OA) journal, and articles are distributed under the terms of the [Creative Commons Attribution-NonCommercial-ShareAlike 4.0 License](https://creativecommons.org/licenses/by-nc-sa/4.0/), which allows others to remix, tweak, and build upon the work non-commercially, as long as appropriate credit is given and the new creations are licensed under the identical terms.For reprints contact: [reprint@ipinnovative.com](mailto:reprint@ipinnovative.com)

## 1. Introduction

Since many pages about pterygium are yet to unfold, therefore title ophthalmic enigma has been given to this disease.<sup>1</sup>

Clinically, it has been defined as a wing shaped lesion encroaching from the bulbar conjunctiva onto the cornea in a wing shaped manner. The pathogenesis of pterygium has a multifactorial mechanism, which is still fascinating many research scholars. However, many have found involvement of factors such as inflammation, granulation tissue proliferation, and vascularization in its

\* Corresponding author.

E-mail address: [divyambbs1994@gmail.com](mailto:divyambbs1994@gmail.com) (D. Khandelwal).

pathogenesis.<sup>2,3</sup>

Previous studies highlighted that feature such as grade, laterality, size of pterygium & histopathological parameters like inflammation, vascularity & fibrosis might have some correlation with recurrence.

Many treatment modalities had been developed and researched throughout ages to attain minimal recurrence with minimum damage to ocular surface and quick rehabilitation with excellent cosmesis. However, surgical excision remains the sole definitive method. Among different surgical modalities, Conjunctival autograft was more efficient in terms of pterygium recurrence after a 6-month follow-up, especially in recurrent pterygia.<sup>4</sup> The most common complication encountered after pterygium excision is recurrence, especially after bare sclera technique, and represents a significant surgical problem.<sup>5</sup> Sang Beom et al. in their reported an 18.8% (28/149) recurrence rate in 1 year study period after Conjunctival Limbal Autograft surgery.<sup>6</sup> Since recurrence is a very common complication of pterygium surgeries, therefore this study was conducted to assess the recurrence rate of pterygium after CLAU, the role of morphological & histopathological features in its development & also to establish the role of topical mitomycin c (0.02%) eyedrop as a therapy to halt the resurgence of clinically significant recurrence.

## 2. Materials and Methods

This study was carried out for 1 year in 107 eyes having pterygium, attending eye OPD at a tertiary care hospital. All due permissions from ethical committee and consent from patients were taken before conducting this study.

After enrolling patient, following findings were noted after examination on slit-lamp biomicroscope such as site of pterygium (nasal/temporal), type of pterygium (stationary/progressive/regressive). Inclusion criteria was patients with pterygium undergoing surgery for decreased visual acuity and/or cosmetic reasons and presented during first 6 months and patients having age group of 20-70 years. Patients having pseudo-ptyerygium, coexisting conjunctival diseases, fibrovascular proliferation of the conjunctiva secondary to injury, a severe ocular surface disease such as blepharitis, severe dry eye syndrome, and systemic pathology that could affect wound healing after ocular surgery were excluded from the study. Grading system used to assess pterygium morphology was A) Anatomical position of the abnormal fibrovascular head

Grade 1: between the limbus and a point midway between the limbus and pupillary margin; grade 2: head of pterygium reaching the pupillary margin; and grade 3: beyond the pupillary margin.<sup>7</sup>

Grading for redness severity<sup>8</sup>

Grade 1: No/mild redness/faint pinkish hue Grade 2: Scattered Small Scattered areas of moderate redness; and Grade 3: Diffuse redness with congested vessels

Thickness Grading-as per Tan et al classification<sup>9</sup>

Grade 1-Atrophic, Grade 2- Intermediate, Grade 3-Fleshy

After examination, excision of pterygium was done by conjunctival limbal autograft surgery.

### 2.1. Surgical technique (CLAU)

Prior to surgery Sensory and motor nerve block was achieved using peribulbar anaesthesia given with 2% lignocaine & 2% bupivacaine. Under aseptic precautions, painting and draping was done. Lid was separated using universal wire speculum. Body and neck were separated using iris repositor & cut from the underlying sclera. Head was separated & dissected from cornea. Conjunctival-limbal autograft were placed over bare sclera. Antibiotic drops were instilled and eye was patched & bandaged.

### 2.2. Histopathology sampling

All the primary pterygium specimens after excision, were placed in 10% formalin & sent for the histopathological assessment.

Histopathological parameters were classified into three groups –

1. Epithelial hyperplasia(present/absent)
2. Vascularity & fibrosis in the stroma (Predominant vascularity /Predominant fibrosis / No significant difference)
3. Inflammatory cells in stroma (mild perivascular/diffuse)

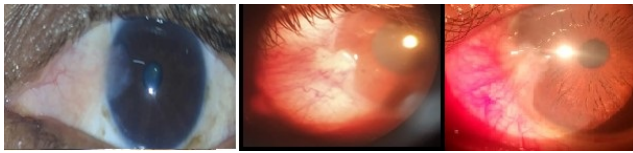
Post-operatively patients were followed up on the 2nd day, 1<sup>st</sup> week, 4<sup>th</sup> week, 2<sup>nd</sup> month, 4<sup>th</sup> month, and 6<sup>th</sup> month for recurrence.

The results of preoperative morphological and histopathological characteristics of pterygium were then compared and findings were correlated with those having recurrence.

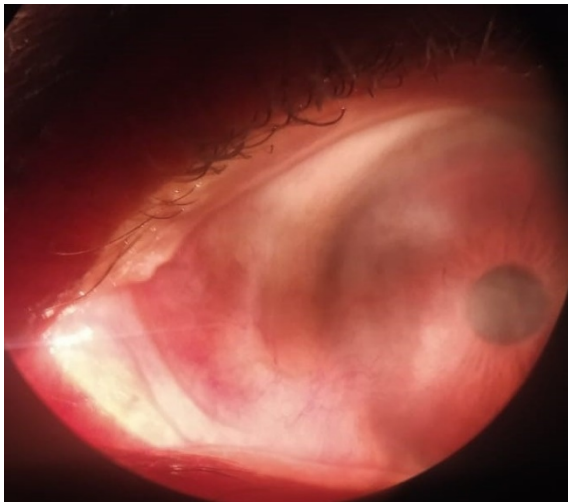
If clinically insignificant recurrence, as shown in Figure 2 (we defined it as only episcleral vessels were seen without any conjunctival soft tissue encroaching upon cornea) was seen, then the patient will be managed by topical mitomycin C drops 0.02% (prepared by reconstituting 2ml mitomycin C injection into 8 ml 0.5% carboxymethylcellulose eyedrop). But if clinically significant recurrent pterygium developed, then those cases were managed by the CLAU (if size < 4mm) or Amniotic membrane grafting (if size > 4mm).

## 3. Results

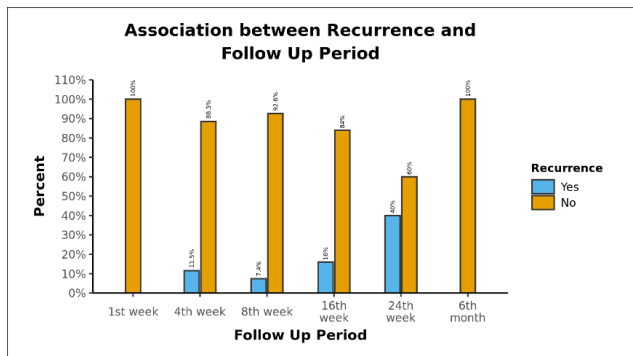
The present study has been carried out on a series of 107 eyes of 107 pterygium cases who attended eye OPD. All cases of the pterygium were surgically excised using conjunctival limbal autograft and recurrence was noted.



**Fig. 1:** Redness grading pterygium



**Fig. 2:** Clinically insignificant recurrent pterygium



**Fig. 3:** Showing association between recurrence and follow up period

The analysis was done using SPSS software, 20.0 version, IBM, Chicago after excel sheet data entry, p-value <0.05 was considered statistically significant.

Table 1 was showing demographic details of patients showing mean age, female & male population, occupational details, eyes involved, and site of pterygium.

Table 2 was showing association morphological grading with recurrence of pterygium.

Table 3 was showing correlation between histopathological findings and recurrence. Epithelial hyperplasia, perivascular inflammation was found predominantly in pterygium tissue.H

The following variables were significantly associated (p<0.05) with the variable 'Recurrence': Age (years), Redness and thickness (morphological grading), Higher relative vascularity & Diffuse Stromal Inflammation on histopathology.

Out of 17 patients, 14 patients had clinically significant recurrence, while 3 of them had clinically insignificant recurrence.

Association of follow up period was also found to be significantly associated as shown in Figure 3, maximum recurrence was reported at 24<sup>th</sup> week follow up visit.

#### 4. Discussion

Pterygium was a common ocular condition being worldwide in distribution. As the management of pterygium remained unsettled it presents a challenge to the present day ophthalmic surgeons, mainly because of its regrowing tendency despite many medical and surgical treatment options. Vinay Nangia and co-workers noticed a high pterygium incidence in 40 + years,<sup>10</sup> similar to our study.

Females were predominantly affected in our study (n=61, 56%).Most of the previous studies have shown an increased incidence of pterygium in males, as men were commonly involved in outdoor works. But study by Hua Zhong et al supported this finding.<sup>11</sup> Our study population contained participants coming from low socioeconomic backgrounds. In these communities, females were commonly occupied in outdoor work. This might be a reason for an increased number of female pterygium cases in our study.

Vinay Nangia and co-workers found a higher incidence in outdoor workers.<sup>10</sup>In our study also, higher incidence was seen among outdoor workers. However, this finding might be biased because our study population had patients from lower socioeconomic background, who mainly work in outdoor environment.

In our study, in all cases, pterygium was nasally located except 2 which were seen temporally. Hilgers J in their explained nasal predominance of pterygium and role of UV light in its pathogenesis.<sup>12</sup> Kobayashi and Kohshima suggested that nasal predominance of pterygium might be due to total internal reflection of light and two anterior ciliary arteries on the nasal side & tear pooling.<sup>13</sup>

T. Vijaya Priya et al concluded that amongst different types of pterygium, the incidence of progressive type is higher.<sup>14</sup>This study supported our findings, as in our study, 74.8% participants had the progressive type of pterygium.

Ip, Mathew et al (2015) postulated that Fuchs spots may represent precursor lesions to UV-associated ocular surface pathology and found in recurrence cases.<sup>15</sup> In our study, although Fuchs spots were found in 5 recurrence cases out of 17, however it was found to be significantly correlated with recurrence similar to previous studies. Since its ideal examination was done by in vivo confocal microscopy, therefore many findings on slit lamp might have been

**Table 1:** Demographic Details of patients (n=107)

Basic Details	Mean $\pm$ SD    Median (IQR)    Min-Max    Frequency (%)
<b>Age (Years)</b>	44.94 $\pm$ 13.28    45.00 (35.00-55.50)    21.00 - 70.00
<b>Age</b>	
21-30 Years	19 (17.8%)
31-40 Years	25 (23.4%)
41-50 Years	29 (27.1%)
51-60 Years	16 (15.0%)
61-70 Years	18 (16.8%)
<b>Gender</b>	
Male	46 (43.0%)
Female	61 (57.0%)
<b>Occupation</b>	
Indoor	40 (37.4%)
Outdoor	67 (62.6%)
<b>Eye</b>	
RE	55 (51.4%)
LE	52 (48.6%)
<b>Location</b>	
Nasal	105 (98.1%)
Temporal	2 (1.9%)

**Table 2:** Morphological grading

Parameters	Recurrence		p value
	Yes(n = 17)	No(n = 90)	
<b>Morphological Grading: Location</b>			0.360 <sup>2</sup>
Grade 1	0 (0.0%)	5 (100.0%)	
Grade 2	8 (12.9%)	54 (87.1%)	
Grade 3	9 (22.5%)	31 (77.5%)	
<b>Morphological Grading: Redness***</b>			0.010 <sup>2</sup>
Grade 1	1 (3.6%)	27 (96.4%)	
Grade 2	10 (15.6%)	54 (84.4%)	
Grade 3	6 (40.0%)	9 (60.0%)	
<b>Morphological Grading: Thickness***</b>			<0.001 <sup>3</sup>
Grade 1	2 (3.3%)	58 (96.7%)	
Grade 2	6 (18.8%)	26 (81.2%)	
Grade 3	9 (60.0%)	6 (40.0%)	

\*\*\*Significant at  $p < 0.05$ , 1: Wilcoxon-Mann-Whitney U Test, 2: Fisher's Exact Test, 3: Chi-Squared Test

**Table 3:** Histopathological parameters and recurrence

Parameters	Recurrence		p value
	Yes(n = 17)	No(n = 90)	
HPE: Epithelial Hyperplasia (Present)	16 (94.1%)	65(72.4%)	0.124 <sup>2</sup>
HPE: Vascularity Overwhelms Fibrosis (Present)***	12 (70.6%)	17 (20.7%)	<0.001 <sup>3</sup>
HPE: Vascularity Similar to Fibrosis (Present)	3 (17.6%)	31 (34.5%)	0.315 <sup>2</sup>
HPE: Fibrosis Overwhelms Vascularity (Present)	3 (17.6%)	40 (44.8%)	0.062 <sup>3</sup>
HPE: Perivascular Stromal Inflammation (Present)***	3 (17.6%)	68 (75.9%)	<0.001 <sup>3</sup>
HPE: Diffuse Stromal Inflammation (Present)***	15 (88.2%)	6 (6.9%)	<0.001 <sup>3</sup>

\*\*\*Significant at  $p < 0.05$ , 1: Wilcoxon-Mann-Whitney U Test, 2: Fisher's Exact Test, 3: Chi-Squared Test

missed.

The study done by Anguria P (2014) reported 27% of recurrence,<sup>16</sup> while in our study, recurrence was seen in 15.88% of patients 6 months after CLAU surgery. Nuzzi et al. in their study found that recurrence was more common in the younger age group. They also showed the role of current active growth, preexisting disfiguration of the lacrimal caruncle, ocular motility restriction, concurrent ocular surface inflammation, fibrogenic constitution, and family history.<sup>17</sup>

In our study also the variables such as younger age group (21-40 years), redness and thickness of pterygium, higher relative vascularity, and diffuse inflammation on histopathological examination were found significantly associated with recurrence. Conversely occupation, laterality, location, and type of pterygium were found not to be related to recurrence.

Sang Beom et al. also found morphological factors and vascularity factors on impression cytology to be associated with higher risk of recurrence.<sup>6</sup>

These findings supported that apart from degenerative factors, proliferative activity also contribute in pathogenesis of pterygium. However, studies by Nassar Moustafa et al. and Fadime Nehoglu showed that there was no significant difference between primary and recurrent pterygia in histopathological features.<sup>18,19</sup>

In our study, after recurrence we managed early (clinically insignificant pterygium) with topical 0.02% mitomycin C eyedrops QID weekly. We noted that redness had been subsided after weekly dosages. In all 3 patients, ocular irritation and discomfort were noted. In 1 patient conjunctival granuloma was noted after its use.

Hayasaka S et al. noted that recurrence after 0.02% mitomycin C use in primary pterygium was 7%, while if used after recurrent pterygia rates were reduced.<sup>20</sup> In our study, only 3 patients were followed up in early recurrence phase. Rest all cases, visited our OPD after development of clinically significant recurrence due to COVID lockdown. That's why no significant association can be made regarding use of topical mitomycin C in halting early pterygium recurrence.

In our study, we also used the CLAU and AMG techniques in clinically significant cases. In recurrence of size >4mm, the AMG technique was used. While in cases having a size < 4mm, the CLAU technique was used.

## 5. Conclusion

As per the findings of our study we can conclude that, higher vascularity and stromal inflammation with fleshy pterygium tissue are the main factors amounting to recurrence of pterygium. This indicated that detailed preoperative slit lamp examination and excised histopathological tissue can be used to predict patients (especially younger ones) having higher tendency towards recurrence, which will definitely

help in its early management. This also suggested role of vascular growth factors and inflammatory cytokines in the pathogenesis of recurrent pterygium, although we didn't compare histopathological parameters of primary and recurrent pterygium in our study, as histopathological samples of only primary pterygium were sent.

Also, we can't prove the significance of topical mitomycin C eyedrop, in management of early recurrence, further studies will be required to establish this role.

## 6. Source of Funding

None.

## 7. Conflict of Interest

None.

## References

1. Coster D. Pterygium - An ophthalmic enigma. *Br J Ophthalmol.* 1995;79:304–5.
2. Girolamo ND, Chui J, Coroneo MT, Wakefield D. Pathogenesis of pterygia: role of cytokines, growth factors, and matrix metalloproteinases. *Prog Retin Eye Res.* 2004;23(2):195–228.
3. Li DQ, Lee SB, Gunja-Smith Z, Liu Y, Solomon A, Meller D, et al. Overexpression of collagenase (MMP-1) and stromelysin (MMP-3) by pterygium head fibroblasts. *Arch Ophthalmol.* 2001;119(1):71–80.
4. Clearfield E, Hawkins BS, Kuo IC. Conjunctival autograft versus amniotic membrane transplantation for treatment of pterygium: findings from a Cochrane systematic review. *Am J Ophthalmol.* 2017;182:8–17.
5. Yaisawang S, Piyapattanakorn P. Role of postoperative topical corticosteroid in recurrence rate after pterygium excision with conjunctival autograft. *J Med Assoc Thai.* 2003;86(Suppl 2):5215–23.
6. Han SB, Jeon HS, Kim M, Lee SJ, Yang HK, Hwang JM, et al. Risk Factors for Recurrence After Pterygium Surgery: An Image Analysis Study. *Cornea.* 2016;35(8):1097–1103.
7. Maheshwari S. Pterygium induced corneal refractive changes. *Indian J Ophthalmol.* 2007;55(5):383–6.
8. Safi H, Kheirkhah A, Mahbod M, Molaei S, Hashemi H, Jabbarvand M. Correlations Between Histopathologic Changes and Clinical Features in Pterygia. *J Ophthalmic Vis Res.* 2016;11(2):153–8.
9. Tan DT, Chee SP, Dear KB, Lim AS. Effect of pterygium morphology on pterygium recurrence in a controlled trial comparing conjunctival autografting with bare sclera excision. *Arch Ophthalmol.* 1997;115(10):1235–40.
10. Nangia V, Jonas JB, Nair D, Saini N. Prevalence and Associated Factors for Pterygium in Rural Agrarian Central India. The Central India Eye and Medical Study. *PLoS One.* 2013;8(12):e82439.
11. Zhong H, Cha X, Wei T, Lin X, Li X, Li J, et al. Yuansheng Yuan; Prevalence of and Risk Factors for Pterygium in Rural Adult Chinese Populations of the Bai Nationality in Dali: The Yunnan Minority Eye Study. *Invest Ophthalmol Vis Sci.* 2012;53(10):6617–21.
12. Hilgers J. Pterygium: Its incidence, heredity, and etiology. *Am J Ophthalmol.* 1960;50:635–44.
13. Kobayashi H, Kohshima S. Unique morphology of the human eye. *Nature.* 1997;387(6635):767–8.
14. Priya TV, Rathinakumar, Amudha P, Venipriya S, Devi KR. Prevalence and types of pterygium in a tertiary hospital in Puducherry. *Indian J Clin Exp Ophthalmol.* 2018;4(2):245–8.
15. Ip MH, Chui JJ, Tat L, Coroneo MT. Significance of Fuchs Flecks in Patients With Pterygium/Pinguecula: Earliest Indicator of Ultraviolet Light damage. *Cornea.* 2015;34(12):1560–3.
16. Anguria P, Ntuli S, Carmichael T. Young patient's age determines pterygium recurrence after surgery. *Afr Health Sci.* 2014;14(1):72–6.

17. Nuzzi R, Tridico F. How to minimize pterygium recurrence rates: clinical perspectives. *Clin Ophthalmol*. 2018;12:2347–62.
18. Nassar MK, El-Sebaey AR, Abdel-Rahman MH, El-Ghonemy K, Shebl AM. Clinical, pathological, and molecular aspects of recurrent versus primary pterygium. *Menoufia Med J*. 2014;27(2):386–94.
19. Nuhoglu F, Turna F, Uyar M, Ozdemir FE, Eltutar K. Is there a relation between histopathologic characteristics of pterygium and recurrence rates. *Eur J Ophthalmol*. 2013;23(3):303–8.
20. Hayasaka S, Noda S, Yamamoto Y, Setogawa T. Postoperative instillation of low-dose mitomycin C in the treatment of primary pterygium. *Am J Ophthalmol*. 1988;106(6):715–8.

**Divya Khandelwal**, Resident Doctor  <https://orcid.org/0000-0001-6581-0459>

**Neetu Kori**, Associate Professor

**Vijay Bhaisare**, Professor and Head

**Preeti Rawat**, Professor

**Manushree Gautam**, Assistant Professor

## Author biography

**Shweta Walia**, Professor

**Cite this article:** Walia S, Khandelwal D, Kori N, Bhaisare V, Rawat P, Gautam M. A clinical study to evaluate recurrence of pterygium after primary surgery and its management. *Indian J Clin Exp Ophthalmol* 2022;8(1):103-108.