

Content available at: <https://www.ipinnovative.com/open-access-journals>

Indian Journal of Clinical and Experimental Ophthalmology

Journal homepage: www.ijceo.org

Review Article

Newer glaucoma surgeries: A review

Pragati Tiwari¹, Amit Raj^{1,*}¹Dept. of Ophthalmology, All India Institute of Medical Sciences, Patna, Bihar, India

ARTICLE INFO

Article history:

Received 25-02-2022

Accepted 22-03-2022

Available online 31-03-2022

Keywords:

Microinvasive glaucoma surgeries (MIGS)

Glaucoma

intraocular pressure (IOP) reduction 1

ABSTRACT

With sophisticated diagnostic modalities used in glaucoma now-a-days, the demand for more accurate and precise intraocular pressure control is also rising. Glaucoma has seen myriad of treatment modalities including medical, laser and surgical. This article focuses on the newer glaucoma surgeries, viz-a-viz microinvasive glaucoma surgeries (MIGS) that has seen immense experimental and clinical research with favourable results. MIGS works via various mechanisms, by-passing trabecular meshwork by implanting a stent or excising the trabecular tissue, enhancing aqueous outflow through Schlemm's canal or suprachoroidal space, and shunting the aqueous to the subconjunctival space. In this article we describe each of these procedures with the results on their efficacy and safety.

This is an Open Access (OA) journal, and articles are distributed under the terms of the [Creative Commons Attribution-NonCommercial-ShareAlike 4.0 License](https://creativecommons.org/licenses/by-nc-sa/4.0/), which allows others to remix, tweak, and build upon the work non-commercially, as long as appropriate credit is given and the new creations are licensed under the identical terms.

For reprints contact: reprint@ipinnovative.com

1. Introduction

Glaucoma is the second leading cause of irreversible blindness worldwide with an estimated 79.6 million people being affected.¹ Estimated prevalence in India is 11.2 million in people aged beyond 40 years of age.^{2,3} Timely diagnosis and early management form the pillars for combating this morbid and mortal disease. Controlling the intraocular pressure (IOP) is the only modifiable risk factor. With medical management including topical anti-glaucoma medications (AGMs) being the first line of treatment, more often than not surgical treatment is necessitated. Long term use of topical AGMs carries compliance issues and an economical burden on the patient with their own set of side effect profile. In order to reduce the number of AGMs usage and have a better IOP control, surgical modalities have a more effective role. Filtering procedures being the gold standard, glaucoma drainage devices have also been extensively studied. These procedures albeit effective, are invasive ones. This calls for a need for alternative modalities

that have a better safety profile, are less invasive and are effective. This requirement paved the path for microinvasive glaucoma surgeries (MIGS). It is the authors' aim to establish a concise understanding of the procedures involved in MIGS, the various devices used in MIGS, their associated complications and their safety & efficacy.

2. Discussion

2.1. Why the need for MIGS?

With the poor compliance to topical ocular hypotensive medications and the various complications of a filtering procedure (bleb-related and otherwise), there was a need for a mid-way modality that has the advantage of good efficacy and non-invasiveness with a reduced dependence on topical ocular hypotensive medications thereby cutting down the financial burden on the patient. This was met by microinvasive (minimally invasive) glaucoma surgeries.

* Corresponding author.

E-mail address: dramitraj@aaimspatna.org (A. Raj).

2.2. What is MIGS?

This terminology was coined by Iqbal Ike Ahmed in 2009. It was believed to be a revolution in glaucoma surgeries. Microinvasive glaucoma surgeries have five features.⁴

1. *ab interno*: It requires a microincisional approach through clear cornea with a direct visualisation of the angle structures.
2. Minimally traumatic: These procedures aim at preserving the normal anatomy and physiology of the anterior chamber angle. It enhances the existing aqueous outflow and is therefore, biocompatible. It also spares the conjunctiva for future filtration surgeries.
3. Good efficacy: Defined as ability to reduce IOP 20% from the baseline and/or reduce usage of at least 1 AGM.
4. High safety profile: The risk of complications like hypotony, choroidal effusions and hemorrhages seen with other surgical procedures is less.
5. Rapid recovery: It entails quick patient recovery and can also be combined with cataract surgery.

The mechanisms by which various MIGS devices enhance the existing aqueous outflow are multi-fold. Figure 1 enlists the various MIGS according to the mechanisms of action.

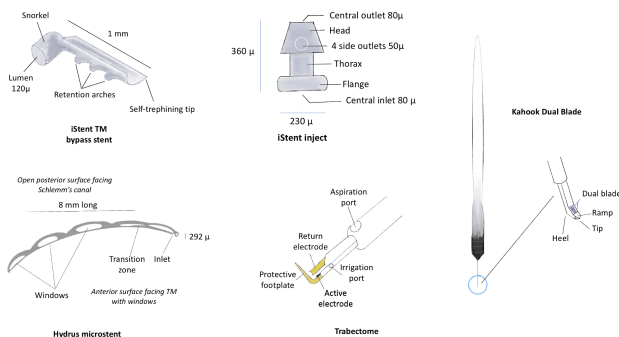


Fig. 1: Microinvasive glaucoma surgeries (MIGS) devices acting by trabecular meshwork by-pass and excision (iStent, iStent inject, hydrus microstent, trabectome, kahook dual blade)

In this review we are describing each MIGS and their efficacy and safety profiles.

2.2.1. iStent (Glaukos, Laguna Hills, CA, USA)

It is an L-shaped, heparin-coated, titanium implant that is implanted into the Schlemm's canal through the trabecular meshwork using a preloaded injector. It received its FDA approval in 2012. It is composed of a snorkel and a body containing a lumen. The body has three retention arches, that safeguards its placement within the Schlemm's canal (Figure 2). The end of the body has a self-trephining tip that aids its injection.⁵ The applicator containing iStent is devised for right eye and left eye. The surgical technique

involves making a clear corneal incision temporally and injecting the device in the lower nasal ACA. To obtain a good view of ACA, the patient's head is turned away from the surgeon by approximately 35 degrees and the microscope turned towards the surgeon by approximately 35 degrees, making a total of 70 degrees. Applicator is introduced through the corneal incision, a direct gonioscope (e.g. Swan Jacob gonioscope) placed onto the cornea and the tip of iStent is introduced at a 15 degrees angle to the meshwork to aid entry into the meshwork. The remaining body of iStent is then introduced further under the meshwork, into the Schlemm's canal. Once this is achieved, the button on the applicator is pressed which releases the device and the snorkel is visible lying over the meshwork. Blood reflux seen in the Schlemm's canal seen while injecting the device confirms its correct placement. Single or multiple iStent can be injected based upon the required IOP control. It can be combined with phacoemulsification; the device being introduced after cataract surgery through the temporal clear corneal incision.

In a multi-centred RCT conducted by the US iStent study group, they compared IOP control in patients with mild to moderate glaucoma undergoing phacoemulsification alone and those undergoing phacoemulsification with iStent trabecular meshwork by-pass stent. They randomized 240 eyes into two groups, of which 117 eyes underwent combined procedure and 123 eyes underwent cataract surgery alone. At 24 months follow-up, 61% patients undergoing iStent implantation with cataract surgery achieved an IOP of ≤ 21 mm Hg without any ocular hypotensive medications as compared to 51% patients of the control group (statistically significant). There was no significant difference between the two groups in terms of CDVA, visual field and pachymetry, deeming iStent implantation a safe modality. Complications include intraoperative stent malposition, iris touch, endothelial touch and stent removal and replacement. Postoperatively, stent obstruction and stent malposition were also found.⁶ In another study, efficacy of two iStent implanted during standard phacoemulsification was assessed in 63 eyes with mild to advanced glaucoma whose IOP was well-controlled on topical medications. At 2 years follow-up, there was 10% IOP reduction with $p < 0.001$ and 28% eyes were not on any topical ocular hypotensive.⁷

2.2.2. iStent inject (Glaukos, Laguna Hills, CA, USA)

This device is similar to iStent, also termed as the second generation iStent. It received its FDA approval in 2018. Its composition is similar to that of first generation iStent, but design is different. It is a 360 μ long device with a head, thorax and flange. The head, containing a central outlet and 4 side outlets, is inserted into the Schlemm's canal, with the thorax traversing the thickness of the meshwork and flange is projecting into the ACA (Figure 2). The applicator

contains two preloaded stents that are placed 2-3 clock hours apart in the nasal angle. The surgical technique is similar to that of first generation iStent.⁴

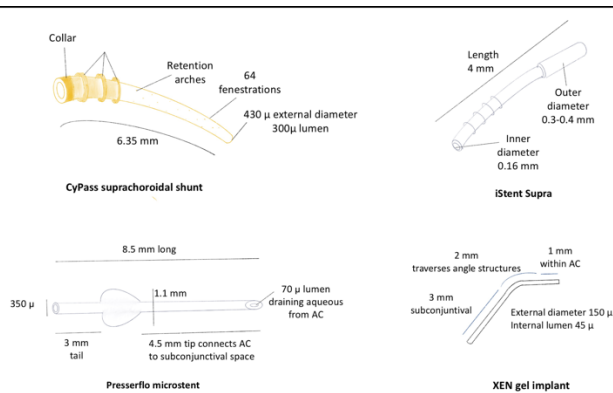


Fig. 2: Suprachoroidal devices (CyPass, iStent Supra) and devices acting by shunting aqueous to the subconjunctival space (Preserflo microstent, XEN gel implant)

Samuelson et al., with the iStent inject study group conducted an RCT where they randomized 505 eyes in a 3:1 ratio into standard phacoemulsification with iStent inject and phacoemulsification alone. They published results at 2 years follow-up. They showed that 75.8% of treatment eyes versus 61.9% of control eyes experienced $\geq 20\%$ reduction from baseline in unmedicated diurnal IOP ($P < 0.005$), and mean reduction from baseline was greater in treatment eyes than in control eyes ($P < 0.001$). Also, 63.2% of treatment eyes versus 50.0% of control eyes had month 24 medication-free diurnal IOP ≤ 18 mmHg.⁸

2.2.3. Hydrus microstent (Ivantis, Inc., Irvine, CA, USA)

This microstent is a crescent-shaped, non-luminal, windowed Schlemm canal scaffold made of nitinol. It is 8 mm long and is implanted through the meshwork via a 1-1.5 mm incision into the Schlemm's canal (Figure 2). It provides an alternate route to aqueous that otherwise faces resistance at the juxtacanalicular segment of the TM and inner wall of Schlemm's, and further provides an intracanalicular scaffold for the canal, exposing outflow to multiple collector channels.⁹ As a result, the Schlemm's canal is dilated for a span of nearly 90° and the trabecular resistance is also by-passed. Hence, it is said to have dual mechanisms of action. The device is preloaded in an injector that has tracking wheel, which on rotating releases the microstent into the canal.¹⁰ The landmark HORIZON study, a multicentre RCT, released their 3 years follow-up results. They had randomized 369 eyes with POAG and visually significant cataract, into Hydrus microstent (HMS) group and no microstent (NMS) group after an uneventful phacoemulsification in a ratio of 2:1. The 3-year follow-up results revealed a significant reduction in postoperative

topical ocular hypotensive usage from baseline compared to the control group [0.4 ± 0.8 in the microstent group and 0.8 ± 1.0 in the CS group ($P < 0.001$)]. 73% eyes in HMS group compared to 48% in NMS group were medication free at the end of 3 years ($p < 0.001$). The cumulative probability of incisional glaucoma surgery was also significantly lower in the microstent group.¹¹

The compare study, another RCT compared the efficacy of Hydrus and two iStent implants for standalone treatment of open-angle glaucoma. 152 eyes with OAG and a preoperative IOP ranging between 23-39 mm Hg were randomized equally into the two groups. At the end of 1 year, compared to the iStent group, Hydrus showed higher rate of complete surgical success, defined as IOP ≤ 18 mmHg, no glaucoma medications and freedom from repeat glaucoma surgery ($p < 0.001$).¹²

2.2.4. Trabectome (NeoMedix Corporation, Tustin, CA, USA)

Trabectome is a microelectrosurgical device (Figure 2) used to perform trabeculectomy by an ab interno approach (AIT). A segment of trabecular meshwork and the inner wall of the Schlemm's canal is stripped resulting in exposure of more collector channels to the aqueous outflow. The Trabectome is a single-use, disposable handpiece with the footplate angled at 90° , containing bipolar electrodes. The console includes irrigation & aspiration unit and an electrocautery generator. The hand-piece is introduced from the temporal side to the nasal angle and the tip of the footplate is inserted within the Schlemm's canal. The aspiration and cautery are activated with the help of a foot switch and device is advanced along the TM either in clockwise or anticlockwise fashion, stripping the meshwork and the inner wall of Schlemm's canal. Continuous irrigation occurs to dissipate the heat of the cautery. Histological examination of angles treated by Trabectome have revealed a disruption of TM and inner wall of Schlemm's without damage to the surrounding structures.¹³ It received its FDA approval in 2004. Kaplowitz et al published a meta-analysis of ab interno trabeculectomy using Trabectome. They defined success as IOP ≤ 21 mmHg with a 20% drop from the baseline and no requirement of a repeat surgery. They analysed the efficacy of AIT as a standalone procedure and also in combination with phacoemulsification. The IOP drop in AIT group was 39% (10.5 ± 1.9 mmHg), with eyes requiring 0.99 ± 0.54 or fewer topical hypotensive and a success rate of $46 \pm 34\%$ at the end of two years. Phaco-AIT group showed an IOP drop of 27% (6.24 ± 1.98 mmHg), with eyes requiring 0.76 ± 0.35 or fewer topical hypotensive and a success rate of $85 \pm 7\%$ at the end of two years.¹⁴ Jea SY et al compared the outcomes of trabeculectomy (with MMC) with AIT in a retrospective, cohort study. The IOP drop was better in cases with trabeculectomy with only 10.8% eyes requiring subsequent surgery (compared to 43.5% in AIT eyes) and

the success rate at 2 years was 76.1% (compared to 22.4% in AIT eyes).¹⁵

2.2.5. Gonioscopy-assisted transluminal trabeculotomy (GATT)

Trabeculotomy involves enhancing the aqueous outflow through Schlemm's canal without the formation of a bleb. The previous techniques require an ab externo approach that is more invasive. Grover et al. described an ab interno approach for circumferential trabeculotomy which is conjunctival sparing and is minimally invasive. A suture (prolene) or a microcatheter (with an illuminating tip, commercially available as iTrack surgical system) is inserted via a temporal corneal incision into the Schlemm's canal of nasal ACA under gonioscopic visualisation. This is further advanced using microsurgical forceps through the canal circumferentially 360°. The catheter tip is then externalized through the temporal incision following which traction is placed on the proximal aspect of the catheter, thus creating a 360° trabeculotomy.¹⁶ This technique is shown to be useful in various forms of open angle glaucoma including secondary open angle glaucoma (pseudoexfoliative, pigmentary, uveitic, steroid-induced), congenital glaucoma, juvenile open angle glaucoma and also in failed trabeculectomy.¹⁷⁻¹⁹ GATT using prolene suture has also shown favourable surgical outcomes.²⁰ In a meta-analysis of GATT performed in patients with open angle glaucoma, the mean IOP is said to be reduced by 9.81 mmHg, with 1.68 reduction in number of medications and a success rate of 85%.²¹

2.2.6. Kahook dual blade goniotomy (KDGB)

Introduced in 2015, Kahook dual blade (New World Medical, Rancho, Cucamonga, CA) is an ab interno goniotomy instrument specialized for mechanical excision of TM. It has the following parts: a pointed tip (pierces the TM), a ramp (elevates & stretches TM), dual blades (excises a strip of TM) and a heel (prevents damage to the underlying Schlemm's canal) (Figure 2).²²

In a study by Greenwood et al, conducted on 71 eyes with majority cases of POAG, and other glaucoma including angle-closure, pigmentary, pseudoexfoliative, and normal tension glaucoma, they performed KDBG and assessed its outcomes. At 6 months, the baseline IOP reduced significantly from 17.4 mmHg to 12.8 mmHg. They reported the most common complication as intraoperative blood reflux during surgery (39.4%).²³ In another study, 12 months results of KDBG with cataract surgery compared with cataract surgery alone in patients with angle closure glaucoma showed good results in the goniotomy group in terms of IOP control and postoperative medication usage.²⁴

2.2.7. CyPass Microstent (Transcend Medical, Inc., Menlo Park, CA)

CyPass is the first commercially available suprachoroidal MIGS device that is inserted ab interno into the suprachoroidal space using an inserter. It is a 6.35 mm long polyamide tube with a 300µ lumen, bearing 64 fenestrations to facilitate additional lateral flow (Figure 3). It has 3 retention rings that act as reference points and aid in positioning the device.⁴ CyPass is loaded onto the retractable guidewire of the insertion device. The implant is then inserted into the AC through the corneal incision and advanced towards the scleral spur under gonioscopic visualization. The tip of the guidewire is engaged with the iris root, and then passed into the supraciliary space, thereby creating a small cyclodialysis cleft. The guidewire is then advanced to complete insertion of the microstent into the supraciliary space. After confirming that the retention rings are engaged, the guidewire is retracted and the insertion device withdrawn from the eye.²⁵ The COMPASS trial was a multicentre RCT which evaluated the 2-year safety and efficacy of CyPass for treating mild to moderate POAG combined with phacoemulsification. They reported significant reduction in IOP in the stent group compared to the non-stent group.²⁶ The 3-year extension of COMPASS trial, assessed the safety and effectiveness of Cypass. This 5-year results from the COMPASS XT study revealed a significant difference in the mean endothelial cell density between the microstent and control group. Primarily owing to endothelial cell loss, CyPass was recalled by FDA on October 24, 2018.²⁷ COMPASS and COMPASS XT together represent the longest and largest completed MIGS trial to date.

2.2.8. XEN gel microstent (Allegan, Dublin, Ireland)

Another suprachoroidal device which establishes a direct, permanent communication between the AC and subconjunctival space. It is a 6 mm long, hydrophilic collagen cylindrical implant composed of crosslinked porcine gelatin (Figure 3). The commercially available implant at present is XEN-45 (45 indicates the lumen diameter in microns). It works on the Hagen- Poiseuille principle and claims to provide 6-8 mm Hg internal pressure resistance and hence, prevent post-operative hypotony.²⁸ It can be implanted via both ab interno and ab externo approach. ab interno approach of XEN gel stent was approved by FDA in 2016. Off-label use of XEN implanted via an ab externo approach has also been evaluated.

Grover et al evaluated the safety and efficacy of XEN Gel microstent in 65 eyes with refractory glaucoma with mitomycin C and found significant IOP reduction (9.1 mmHg) and reduction in ocular hypotensive use (3.5 to 1.7) at the end of 12 months. (28) 32.3% cases required bleb needling in this study and hypotony was observed in 24.6% cases. Less common complications included hyphema, stent

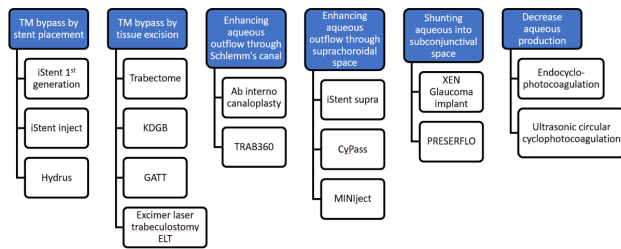


Fig. 3: Classification of microinvasive glaucoma surgeries (MIGS) based on mechanisms of action

migration, stent exposure, endothelial touch, and bleb-related complications.

Various studies have been published including utilizing XEN as a standalone procedure in pseudophakic eyes and combining it with phacoemulsification in phakic eyes.²⁹ It has also been used in refractory glaucomas other than POAG, including pseudoexfoliation glaucoma, uveitic glaucoma, even congenital glaucoma with favourable results.^{30–32}

2.2.9. iStent supra

Also called the 3rd generation iStent by Glaukos, it is a 4mm long ridged, curved, suprachoroidal device composed of polyethersulfone and titanium (Figure 3). It is available preloaded in an injector and is inserted ab interno into the suprachoroidal space. It has received its European CE mark but the FDA approval is pending. Myers et al evaluated the outcomes of 2 iStent, one iStent Supra and postoperative prostaglandin analogues in patients with refractory OAG.³³ Further studies commenting on its efficacy and safety are still underway.

2.2.10. Preserflo microshunt

A new glaucoma drainage microtube (Figure 3) by Santen Pharmaceutical Co. Ltd., Osaka, Japan is made of a unique material called 'SIBS' (poly styrene-block-isobutylene-block-styrene) was designed to achieve significant, long-term IOP control in a more simple, safe and less invasive manner. In experimental studies, SIBS has been found to be more biocompatible and to incite less inflammation.³⁴

The device has been approved in Europe but its approval by the FDA is still pending. In a study by Riss et al, 45.3% IOP reduction was achieved in 91 eyes at one year follow-up. Complications included hypotony and hyphema, neither of which required any surgical intervention.³⁵

3. Conclusion

Glaucoma management has witnessed vistas of innovations especially implantable devices aiming at a more predictable IOP control and successful outcomes in refractory glaucomas. Apart from the bulky glaucoma drainage devices, the demand for a less invasive surgical technique

was met with the advent of microinvasive glaucoma surgeries. With promising results in various glaucomatous scenarios, the practicality of these devices should be faced, especially in developing countries, where awareness and diagnosis of glaucoma is still a challenge. Diagnostic challenges aside, the availability and cost-effectiveness of these devices needs to be taken into consideration too. Cost comparisons of various devices have been made with long-term ocular hypotensive medication usage.^(36,37) The poor long-term adherence to topical medications and their side effects makes such devices a promising modality in the management of glaucoma.

4. Source of Funding

None.

5. Conflict of Interest


The authors declare no conflict of interest.


References

1. Quigley HA, Broman AT. The number of people with glaucoma worldwide in 2010 and 2020. *Br J Ophthalmol.* 2006;90(3):262–7.
2. George R, Ve RS, Vijaya L. Glaucoma in India: Estimated Burden of Disease. *J Glaucoma.* 2010;19(6):391–7.
3. Maurya RP. Glaucoma burden: Indian scenario. *Indian j Clin Exp Ophthalmol.* 2017;3(4):387–8.
4. Saheb H, Ahmed IIK. Micro-invasive glaucoma surgery: current perspectives and future directions. *Curr Opin Ophthalmol.* 2012;23(2):96–104.
5. Nichamin LD. Glaukos iStent® Trabecular Micro-Bypass. *Middle East Afr J Ophthalmol.* 2009;16(3):138–40.
6. Craven ER, Katz LJ, Wells JM, Giamporcaro JE. Cataract surgery with trabecular micro-bypass stent implantation in patients with mild-to-moderate open-angle glaucoma and cataract: two-year follow-up. *J Cataract Refract Surg.* 2012;38(8):1339–45.
7. Buffet J, Brasnu E, Baudouin C, Labbé A. Efficacy of 2 Trabecular Micro-Bypass Stents During Phacoemulsification for Mild to Advanced Primary Open-angle Glaucoma Controlled With Topical Hypotensive Medications. *J Glaucoma.* 2017;26(12):1149–54.
8. Samuelson TW, Sarkisian SR, Lubeck DM, Stiles MC, Duh YJ, Romo EA, et al. Randomized, Controlled Pivotal Trial of an Ab Interno Implanted Trabecular Micro-Bypass in Primary Open-Angle Glaucoma and Cataract: Two-Year Results. *Ophthalmology.* 2019;126(6):811–21.
9. Johnstone MA, Saheb H, Ahmed IIK, Samuelson TW, Schieber AT, Toris CB. Effects of a Schlemm canal scaffold on collector channel ostia in human anterior segments. *Exp Eye Res.* 2014;119:70–6.
10. Samet S, Ong JA, Ahmed IIK. Hydrus microstent implantation for surgical management of glaucoma: a review of design, efficacy and safety. *Eye Vis.* 2019;6:32.
11. Ahmed I, Rhee DJ, Jones J, Singh IP, Radcliffe N, Gazzard G, et al. Three-Year Findings of the HORIZON Trial: A Schlemm Canal Microstent for Pressure Reduction in Primary Open-Angle Glaucoma and Cataract. *Ophthalmology.* 2021;128(6):857–65.
12. Ahmed IIK, Fea A, Au L, Ang RE, Harasymowycz P, Jampel HD, et al. A Prospective Randomized Trial Comparing Hydrus and iStent Microinvasive Glaucoma Surgery Implants for Standalone Treatment of Open-Angle Glaucoma: The COMPARE Study. *Ophthalmology.* 2020;127(1):52–61.
13. Francis BA, See RF, Rao NA, Minckler DS, Baerveldt G. Ab interno trabeculectomy: development of a novel device (Trabectome) and

- surgery for open-angle glaucoma. *J Glaucoma*. 2006;15(1):68–73.
14. Kaplowitz K, Bussell II, Honkanen R, Schuman JS, Loewen NA. Review and meta-analysis of ab-interno trabeculectomy outcomes. *Br J Ophthalmol*. 2016;100(5):594–600.
 15. Jea SY, Francis BA, Vakili G, Filippopoulos T, Rhee DJ. Ab interno trabeculectomy versus trabeculectomy for open-angle glaucoma. *Ophthalmology*. 2012;119(1):36–42.
 16. Grover DS, Godfrey DG, Smith O, Feuer WJ, De Oca IM, Fellman RL, et al. Gonioscopy-assisted transluminal trabeculectomy, ab interno trabeculectomy: technique report and preliminary results. *Ophthalmology*. 2014;121(4):855–61.
 17. Grover DS, Godfrey DG, Smith O, Shi W, Feuer WJ, Fellman RL. Outcomes of Gonioscopy-assisted Transluminal Trabeculectomy (GATT) in Eyes With Prior Incisional Glaucoma Surgery. *J Glaucoma*. 2017;26(1):41–5.
 18. Grover DS, Smith O, Fellman RL, Godfrey DG, Butler MR, De Oca IM. Gonioscopy assisted transluminal trabeculectomy: an ab interno circumferential trabeculectomy for the treatment of primary congenital glaucoma and juvenile open angle glaucoma. *Br J Ophthalmol*. 2015;99(8):1092–6.
 19. Boese EA, Shah M. Gonioscopy-assisted Transluminal Trabeculectomy (GATT) is An Effective Procedure for Steroid-induced Glaucoma. *J Glaucoma*. 2019;28(9):803–7.
 20. Aktas Z, Ucgul AY, Bektas C, Karamert S. Surgical Outcomes of Prolene Gonioscopy-assisted Transluminal Trabeculectomy in Patients With Moderate to Advanced Open-Angle Glaucoma. *J Glaucoma*. 2019;28(10):884–8.
 21. Guo CY, Qi XH, Qi JM. Systematic review and Meta-analysis of treating open angle glaucoma with gonioscopy-assisted transluminal trabeculectomy. *Int J Ophthalmol*. 2020;13(2):317–24.
 22. Seibold LK, Soohoo JR, Ammar DA, Kahook MY. Preclinical Investigation of Ab Interno Trabeculectomy Using a Novel Dual-Blade Device. *Am J Ophthalmol*. 2013;155(3):524–9.
 23. Greenwood MD, Seibold LK, Radcliffe NM, Dorairaj SK, Aref AA, Román JJ, et al. Goniotomy with a single-use dual blade: Short-term results. *J Cataract Refract Surg*. 2017;43(9):1197–201.
 24. Dorairaj S, Tam MD, Balasubramani GK. Twelve-month outcomes of excisional goniotomy using the Kahook Dual Blade® in eyes with angle-closure glaucoma. *Clin Ophthalmol Auckl NZ*. 2019;13:1779–85.
 25. Hoeh H, Vold SD, Ahmed IK, Anton A, Rau M, Singh K, et al. Initial Clinical Experience With the CyPass Micro-Stent: Safety and Surgical Outcomes of a Novel Supraciliary Microstent. *J Glaucoma*. 2016;25(1):106–12.
 26. Vold S, Ahmed IIK, Craven ER, Mattox C, Stamper R, Packer M, et al. Two-Year COMPASS Trial Results: Supraciliary Microstenting with Phacoemulsification in Patients with Open-Angle Glaucoma and Cataracts. *Ophthalmology*. 2016;123(10):2103–12.
 27. Reiss G, Clifford B, Vold S, He J, Hamilton C, Dickerson J, et al. Safety and Effectiveness of CyPass Supraciliary Micro-Stent in Primary Open-Angle Glaucoma: 5-Year Results from the COMPASS XT Study. *Am J Ophthalmol*. 2019;208:219–25.
 28. Sheybani A, Reitsamer H, Ahmed I. Fluid Dynamics of a Novel Micro-Fistula Implant for the Surgical Treatment of Glaucoma. *Invest Ophthalmol Vis Sci*. 2015;56(8):4789–95.
 29. Rather PA, Vold S, McFarland M. Twelve-month outcomes of an ab interno gelatin stent combined with cataract surgery or as a standalone procedure in pseudophakic eyes with open-angle glaucoma. *J Cataract Refract Surg*. 2020;46(8):1172–9.
 30. Gillmann K, Bravetti GE, Mermoud A, Rao HL, Mansouri K. XEN Gel Stent in Pseudoexfoliative Glaucoma: 2-Year Results of a Prospective Evaluation. *J Glaucoma*. 2019;28(8):676–84.
 31. Smith OU, Grover DS, Emanuel ME, Godfrey DG, Fellman RL. XEN Gel Stent in Pediatric Glaucoma. *J Glaucoma*. 2020;29(4):19–22.
 32. Qureshi A, Jones NP, Au L. Urgent Management of Secondary Glaucoma in Uveitis Using the Xen-45 Gel Stent. *J Glaucoma*. 2019;28(12):1061–6.
 33. Myers JS, Masood I, Hornbeak DM, Belda JJ, Auffarth G, Jünemann A, et al. Prospective Evaluation of Two iStent® Trabecular Stents, One iStent Supra® Suprachoroidal Stent, and Postoperative Prostaglandin in Refractory Glaucoma: 4-year Outcomes. *Adv Ther*. 2018;35(3):395–407.
 34. Pinchuk L, Wilson GJ, Barry JJ, Schoepfoerster RT, Parel JM, Kennedy JP. Medical applications of poly(styrene-block-isobutylene-block-styrene) (“SIBS”). *Biomaterials*. 2008;29(4):448–60.
 35. Riss I, Battle J, Pinchuk L, Kato YP, Weber BA, Parel JM. One-year results on the safety and efficacy of the InnFocus MicroShunt™ depending on placement and concentration of mitomycin C. *J Fr Ophthalmol*. 2015;38(9):855–60.

Author biography

Pragati Tiwari, Junior Resident  <https://orcid.org/0000-0002-5034-4501>

Amit Raj, Additional Professor & Head  <https://orcid.org/0000-0001-7012-9967>

Cite this article: Tiwari P, Raj A. Newer glaucoma surgeries: A review. *Indian J Clin Exp Ophthalmol* 2022;8(1):3–8.