

Content available at: <https://www.ipinnovative.com/open-access-journals>

Indian Journal of Clinical and Experimental Ophthalmology

Journal homepage: www.ijceo.org

Original Research Article

A clinico epidemiological study of retinitis pigmentosa and associated syndromes – A prospective observational study

Balaji Gopinath¹, Niranjan Karthik Senthil Kumar^{2,*}¹Government Omadurar Medical College, Chennai, Tamil Nadu, India²Regional Institute of Ophthalmology and Government Ophthalmic Hospital, Chennai, Tamil Nadu, India

ARTICLE INFO

Article history:

Received 30-12-2021

Accepted 12-07-2022

Available online 06-10-2022

Keywords:

Syndromic associations

Bardet biedl syndrome

ABSTRACT

Aim: To analyze clinico-epidemiological trends in Retinitis Pigmentosa (RP) cases and syndromes associated with RP.**Materials and Methods:** This is a prospective observational case series. All cases found to have clinical features suggestive of RP were studied. The period of study was for twelve months. Detailed history taking, General and ocular examinations were performed meticulously to look for various associations and findings related to RP.**Results:** Among 55 patients of Primary RP, 38 (69%) were males and 17 (31%) females. 69.9% had the onset in 1st decade, 14.5% in 2nd decade and 16.36% beyond 2nd decade. In 1st decade of life, pattern of inheritance showed a predominance of autosomal recessive pattern (34.5%) followed by sporadic (27.2%). 30 out of 55 cases (54%) had positive family history of night blindness while remaining 25(46%) were sporadic in nature. 40 (72.7%) had typical RP, 4 cases had atypical RP (7.2%) and 11 (20%) syndromic RP. Of 11 cases which had syndromic associations, most common was Usher syndrome being 5 (45%). Regarding treatment, myopia was corrected with best glasses in 25 cases and 5 required low vision aids. 35 cases (64%) maintained visual acuity and fields.**Conclusion:** Retinitis pigmentosa presents in an isolated or syndromic manner (20%). Periodic testing helps in timely detection of progression of disease. Correction of refractive error and use of low vision aids allows patients to pursue many activities of daily living better. Supportive genetic counselling and utility of ERG in detecting early loss of photoreceptor function.This is an Open Access (OA) journal, and articles are distributed under the terms of the [Creative Commons Attribution-NonCommercial-ShareAlike 4.0 License](https://creativecommons.org/licenses/by-nc-sa/4.0/), which allows others to remix, tweak, and build upon the work non-commercially, as long as appropriate credit is given and the new creations are licensed under the identical terms.For reprints contact: reprint@ipinnovative.com

1. Introduction

Retinitis pigmentosa (RP) is a clinically and genetically heterogeneous group of inherited retinal disorders characterized by diffuse progressive dysfunction of predominantly rod photoreceptors, with subsequent degeneration of cone photoreceptors, and retinal pigment epithelium (RPE). Since RP is a collection of many different genetic disorders, the etiology is quite variable. RP may occur as an isolated sporadic disorder, or be

inherited as autosomal dominant, autosomal recessive or X-linked. RP may also be associated with certain systemic disorders which are usually autosomal recessive. There are many genes associated with RP for which a patient can undergo genetic testing. Histopathologic studies suggest that RP results from a primary defect in the rod and cone photoreceptors. Systemic associations noted with these syndromes; Laurence-Moon-Biedl syndrome is characterized by retinitis pigmentosa, obesity, hypogonadism, polydactyly and mental deficiency. Cockayne's syndrome comprises retinitis pigmentosa, progressive infantile deafness, dwarfism, mental retardation,

* Corresponding author.

E-mail address: s.niranjankarthik96@gmail.com (N. K. S. Kumar).

nystagmus and ataxia. Refsum's syndrome is characterized by retinitis pigmentosa, peripheral neuropathy and cerebellar ataxia, Usher's syndrome includes retinitis pigmentosa and labyrinthine deafness. Hallgren's syndrome comprises retinitis pigmentosa, vestibulo-cerebellar ataxia, congenital deafness and mental deficiency.

2. Materials and Methods

This was a prospective descriptive study where clinical material was obtained from patients attending ophthalmology department, in a tertiary eye care hospital during the period from April 2018 to March 2019. The ethical clearance was obtained from institutional ethical committee before starting the study. All the cases found to have clinical features suggestive of RP were taken up for the study. Detailed history was obtained about presenting ocular complaints including age of onset the earliest symptoms, mode of onset and progress. Associated ocular and systemic features were documented. Family history including consanguinity of parents was elicited. General examination was performed to identify syndromic associations. Opinions from ENT (for Audiometry), Psychiatry (for I.Q. Assessment), Endocrinology (for Hormonal Imbalance) and Neurology departments were sought. Ocular examination for ocular deviation, compensatory head posture, restriction of movements. Anterior segment was examined under direct illumination and under slit lamp to detect any abnormalities like keratoconus, posterior sub-capsular cataract, vitreous opacities and open angle glaucoma.

Visual acuity was assessed with Snellen's test types. Refractive state of the eyes were assessed using cycloplegic refraction. Visual fields were assessed by Listers perimeter and Bjerrum's screen. Colour vision was tested with Ishihara's chart. Intra ocular pressure was recorded with Schiotz Tonometer. Fundus was examined by direct and indirect ophthalmoscopy and with Goldman's three mirror lens. Peripheral retina was examined for the presence of thinning, pigmentary changes, tessellation and white glistening spots and bone spicule like pigmentation. Cases presenting with systemic features were also photographed. Audio metric assessment was done at the department of ENT. Cardio vascular system, respiratory system, GIT and central nervous system examination was done for all the patients to detect any abnormalities. Cycloplegic refraction was done for all the cases and glass prescription was given for the best possible corrected visual acuity. All the patients were treated with oral vitamin A (15000 I.U. of retinyl palmitate). Patients were followed up on monthly basis for six months. During each visit visual acuity and visual fields were assessed. Superficial temporal artery ligation was done in 10 out of 55 cases. Cases having visual acuity of less than 6/60 were excluded. Cases selected for ligation were admitted and subjected to surgery under local anaesthesia.

STA ligation was done on both sides. Cases were followed for six months and any improvement in visual acuity and visual field was noted.

3. Results

During the period from April 1999 to March 2000, 55 case of primary Retinitis Pigmentosa attended the outpatient Department and the study was conducted on these patients. There were 38 males and 17 females. Males constituted 69% and females 31% of cases in this study. The age of the patient's varied from 1 year to 59 years (Figure 1). Of these 30.9% of cases were between 21-30 years and 28.8% between 11-20 years of age. Out of 55 cases, 46 were Hindus, 3 Muslims and 6 Christians. Of 55 cases, 41 were living in rural area and 14 were living in urban areas. Only 12.72% of patients in this study were illiterate. Onset in the 1st decade of life. 69.9% was observed in 1st decade, 14.5% in the 2nd decade of life and 16.36% beyond 2nd decade. Majority of cases i.e. 50.9% of males and 18.1% of females had their onset in the first decade of life 34.5% of Autosomal Recessive, 1.8% of Autosomal Dominant, 3.6% X-Linked recessive, 27.2% sporadic had their onset in 1st decade. It was delayed beyond 20 years only in 7.2% of sporadic cases (Table 1). Night blindness was the initial symptom in all the patients, visual field loss was present in 37 cases (67.2%) and visual loss was the complaint in 18 cases (32.7%).

Out of the 55 cases examined, 30 had family history of night blindness whereas 25 had no history of RP and no history of consanguinity among parents (Sporadic/Simplex Or Multiplex Cases). These 25 cases were assumed to be sporadic ones. Out of 30 cases with positive family history 6 cases had history of RP in the ascendants or descendants and were considered to be having autosomal dominant RP(ADRP). 22 cases had RP in siblings or collaterals and are considered to have an autosomal recessive RP(ARRP). 2 cases were male siblings with all their female siblings healthy. These were considered as X-Linked recessive cases. Among hereditary group, history of consanguinity among parents was present in 21 (70%) cases and 9(30%) had non consanguineous parents. Out of these 21 cases with consanguineous parents 19 are AR type (90.4%) and 2 were X linked RP. No consanguinity was seen in autosomal dominant RP. Out of 22 cases of ARRP 19 cases had history of consanguinity and 3 cases had no history of consanguinity. Both the cases of X-Linked RP that were seen had history of consanguinity.

Out of 55 cases examined 40 (72.7%) had typical RP, 4 case had atypical RP (7.2%) and 11 (20%) syndromic RP. Out of 4 atypical cases 3 were diagnosed as Retinitis Punctata albescens and one case as inverse RP. Of the syndromic RP cases, 5 cases were diagnosed as Usher's syndrome, 4 cases as Bardet Biedl syndrome (Figure 3) and 2 cases as Cockayne's syndrome (Figure 2).

Out of 40 cases of typical RP, 10 cases were sporadic, 12 were autosomal recessive, 6 were autosomal dominant and 2 were X-linked recessive. All 4 cases of atypical RP, were autosomal recessive.

Out of 11 syndromic RP cases 3 were sporadic and 8 were autosomal recessive cases. Severity of the disease was assessed by recording the corrected visual acuity and visual field in each eye separately. Visual acuity was graded as Good (6/6), fair(6/6p-6/36) and poor (<6/36). A total of 110 eyes (55 RE and 55 LES) were tested for visual acuity. The corrected visual acuity was normal in (6/6) in 4 eyes (3.6%), between (6/6 P to 6/36) in 44 eyes (40%) and less than 6/36 in 62 eyes. Out of 44 eyes with ARRP (22 cases), 2 had good visual acuity, 22 had fair visual acuity and 20 had poor visual acuity. Out of 12 eyes with ADRP (6 cases) 2 had fair visual acuity, 10 had poor visual acuity. All the 4 eyes (2 cases), 2 had fair visual acuity, 10 had poor visual acuity. All the 4 eyes (2 cases) with X-Linked RP had poor visual acuity. Out of 50 eyes with sporadic RP (25 cases), 2 eyes had good visual acuity, 20 eyes had fair visual acuity and 28 eyes had poor acuity. Most common visual field defect was generalized constriction of visual field (Tubular Field). Out of 110 eyes of 55 cases, Field charting was possible only in 48 eyes. The remaining 62 eyes had poor visual acuity making field charting impossible. Out of 48 eyes, 34 had generalized constriction, 10 had mid peripheral ring scotoma, 4 had no field defect.

The most common ocular abnormality seen was myopia and posterior sub-capsular cataract (Table 2). These were common in ARRP and sporadic cases. Macular dystrophy was seen in 3 cases (5.45%). Myopia was seen in 25 cases and posterior sub-capsular cataract in 6 cases. Patients above 40 years showed age related changes. Posterior sub-capsular cataract and macular dystrophy was the cause of decreased central visual acuity in 10 RP cases. Squint was seen in 2 cases and glaucoma and nystagmus in one case. In this study I came across 11 cases RP associated with systemic features. Out of 11 cases 5 were Usher's syndrome. Of these 5 cases 2 were type I and 3 were type II Usher's syndrome. 4 were male and 1 female. Systemic features noted were deafness (measured by audiometry) and vestibular disturbance. 3 cases had typical RP fundus picture and 2 cases had atypical RP. 3 cases had Autosomal Recessive inheritance. 4 cases (2 male and 2 female) had features of Bardet Biedl syndrome. Systemic features noted were polydactyly, obesity, hypogonadism and mental retardation (By Bhatia's short scale intelligence performance). The fundus picture was that of typical RP. 3 cases had Autosomal Recessive inheritance. In both cases fundus picture was that of salt and pepper variety and one had poor visual acuity. Systemic features noted were short stature, bird like facies, premature ageing, photosensitivity to light and mild mental retardation.

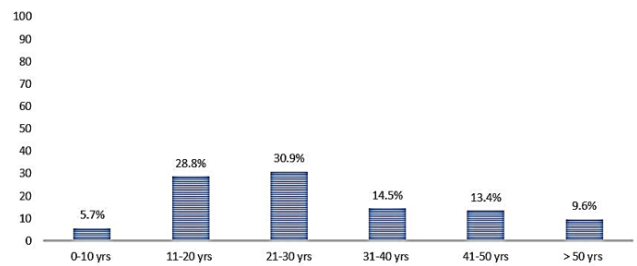


Fig. 1: Age group of patients

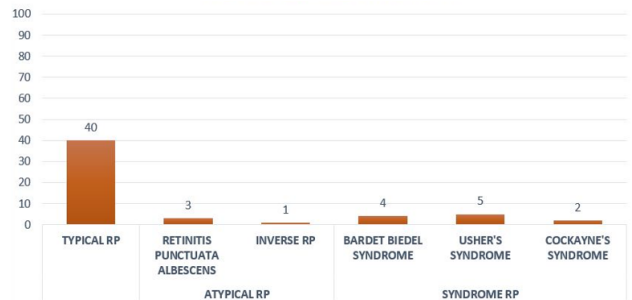


Fig. 2: Clinical types of RP

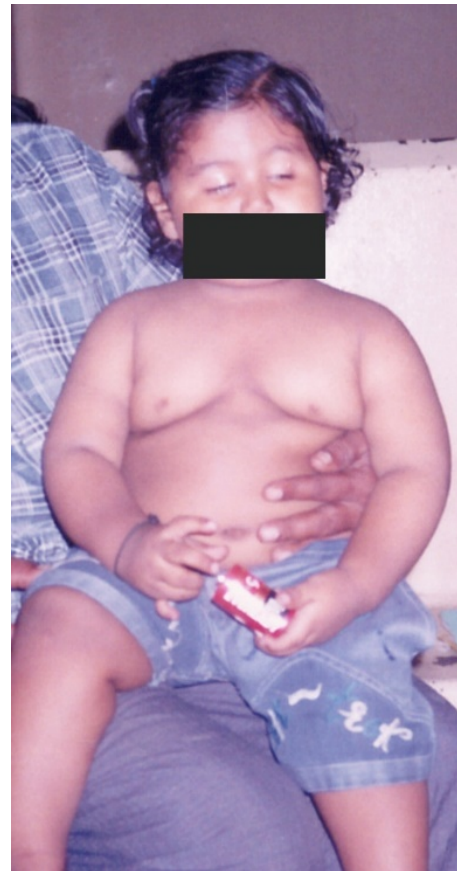

Fig. 3: Bardet-Biedl syndrome

Table 1: Onset of RP in different genetic types

| Age of onset (Years) | AR | | AD | | XR | | Sporadic | | Total | |
|-------------------------|-----|------|-----|------|-----|-----|----------|-----|-------|------|
| | No. | % | No. | % | No. | % | No. | % | No. | % |
| 0-10 | 19 | 86.3 | 1 | 16.6 | 2 | 100 | 15 | 60 | 37 | 67.2 |
| 11-20 | 3 | 13.6 | 3 | 50 | - | - | 6 | 24 | 12 | 21.8 |
| >20 | - | - | 2 | 33.3 | - | - | 4 | 16 | 6 | 10.9 |
| Total | 22 | 100 | 6 | 100 | 2 | 100 | 25 | 100 | 55 | 100 |

Table 2: Associated ocular conditions

| Associated ocular conditions | ARRP | | ADRP | | XL RP | | Sporadic | | Total | |
|--------------------------------|------|------|------|------|-------|---|----------|----|-------|------|
| | No. | % | No. | % | No. | % | No. | % | No. | % |
| Keratoconus | - | - | - | - | - | - | - | - | - | - |
| Glaucoma | 1 | 4.5 | - | - | - | - | - | - | 1 | 1.8 |
| Posterior subcapsular cataract | 3 | 13.6 | - | - | - | - | 3 | 12 | 6 | 10.9 |
| Nystagmus | - | - | - | - | - | - | 1 | 4 | 1 | 1.8 |
| Squint | 1 | 4.5 | - | - | - | - | 1 | 4 | 2 | 3.6 |
| Vitreous opacities | - | - | - | - | - | - | - | - | - | - |
| Myopia | 19 | 86.3 | 1 | 16.6 | - | - | 5 | 20 | 25 | 45.4 |
| Macular dystrophy | 1 | 4.5 | 1 | 16.6 | - | - | 1 | 4 | 3 | 5.4 |

4. Discussion

In this study the males constituted 69% and females constituted 31%. This conforms with the observation of Nettleship¹ (1907-1903) that the males are more commonly affected. Francois and Verriest (1956)² had published almost identical data. The increased incidence of RP in males is attributed to the occurrence of X-Linked Recessive transmission (which affects males only) in some cases and the protective action of female sex hormones and the effect of lyonization. The mean age of the patients was 28.24 in this study. More than 50% of the patients were in the second and third decades of their life. 69% had their onset of initial symptom of night blindness before 10 years of age, whereas 14.5% had the onset between 11-20 years. Onset is delayed beyond 20 years of age in 16.3% of cases. This is in agreement with the descriptions of Gerald Fishman (1987)³ that the onset is usually in the first or second decade of life. The gradual onset and slow progression of the disease explain the delay in the presentation of the patient to the ophthalmologist. 83% of the patients were Hindus and 10.9% were Christians and 5.4% were Muslims. This distribution is in concordance with the demographic pattern of the suburbs of Madurai. According to Duke Elder⁴ no race is exempt or particularly more prone to develop it. 74.5% of patients were living in rural areas whereas 25.4% of patients were from urban areas. Atmospheric pollution which is significant in urban areas does not seem to have any influence in the development of this disease (Merin and Auerbach)⁵ 87.2% of patients had some degrees of education (Primary, secondary school or University) and only 12.72% of patients were illiterate. RP as such does not affect intelligence

or mental development. But the deterioration in the quality of vision must have caused drop out in education. The classic work of Nettleship (1907-1908)¹ on 976 affected families comprising 1681 affected persons showed hereditary transmission in approximately half the cases. Among the hereditary RP, autosomal recessive is the most common from though Autosomal Dominant and X-Linked Recessive forms are also reported. Francois² has put the figures as 37% Autosomal Recessive, 19.5% Autosomal Dominant, 4.5% X-LR and 39%. Although all cases of true RP are believed to be genetic, there is no family history of affected relatives in 15-63% of cases (Richard).⁶ Difficulties in estimation of the percentage of simplex cases that represent AR inheritance have contributed to sizable errors. For example, the study by Ammann et al⁷ over estimated AR cases in Switzerland at 90% and under estimated AD and X-Linked Recessive cases at 9% and 1% respectively. In this study 45.4% cases were sporadic and 40% were Autosomal Recessive, 10.9% were Autosomal Dominant and 3.6% were X-Linked Recessive. This is in agreement with the estimates of percentages of all RP by Richard Weleber.⁶ [ARRP 13%-69% (average 41%), ADRPN 10% - 24% (average 16%), X-Linked Recessive 5%-21% (average 9%)]. Nettleship¹ showed that there is equal number of consanguineous and non-consanguineous marriages in families affected by RP. In his study of 976 families he found heredity with consanguinity in 230 (23.5%) heredity without consanguinity in 226 (23%) cases. Among hereditary types with consanguinity was present in 70% of cases whereas heredity without consanguinity was present in 30% of cases. Out of 21 cases with history of consanguinity, 19 belong to ARRP and 2 belong to

X-LRP. History of consanguinity was not seen in any of the ADRP cases. Out of 55 RP cases, 38.1% cases were with the history of consanguinity and 61.8% cases were without consanguinity. Hence among hereditary group consanguinity plays a role in the transmission of RP. In this study, severity of the disease, as assessed by age of onset, corrected visual acuity, visual field examination and associated less changes were reported to be varying. According to Botermans⁸ the disease is more severe in males and in autosomal recessive and X-Linked recessive cases. It is less severe in females and in Autosomal Dominant and sporadic cases. A.T. Moore et al⁹ after studying 24 cases of RP with incomplete penetrance in 4 families, found that the age of onset was before 10 years of age in 50% cases, between 11 and 20 years in 29% cases and beyond 20 years in 21% cases. In our study, the age of onset shows that with regard to age of onset, the severity is less in Autosomal Dominant and sporadic cases. This is in agreement with the conclusion of Botermans.⁸ Severity of visual field defects was comparable in males and females. Generalized constriction (most severe form) was seen in 78.9% of males and 40% of females. Autosomal Recessive and X-Linked cases showed greater reduction in visual field. The incidence of cataract is equal between Autosomal Recessive and sporadic cases compared to nil cases in Autosomal Recessive and XR cases. Incidence of myopia is more in Autosomal Recessive cases (86.3%) compared to 16.6% of Autosomal Recessive and 20% of sporadic cases. Macular dystrophy is equal in Autosomal Recessive, Autosomal Dominant and sporadic cases. These findings show that Autosomal Dominant is the least severe form and X linked is the most severe form. Of the 55 patients included in the study, association of the eye disorder with systemic syndrome was found in 11 of 55 cases of primary pigmentary retinal dystrophy. 5 of the 55 were Usher's syndrome, 4 represented cases of Bardet Biedl syndrome and 2 cases represented the rare Cockayne's syndrome. Of the 11 cases, 6 were males and 5 were females. 6 cases were of AR inheritance, and 5 cases were of sporadic inheritance. Of the 5 cases of Usher's syndrome 2 were Type I Usher's syndrome, 3 were Type III Usher's syndrome, Type I patients had congenital deafness and prepubertal onset of RP. Type II patients had partial deafness and milder forms of RP. Visual acuity was better retained with Type II Usher's syndrome. Two cases with Type II Usher's syndrome had posterior subcapsular cataract. Bardet Biedl syndrome was seen in 4 cases. Of these 4 cases 2 were males and 2 females. All the 4 cases had systemic features of polydactyly, obesity, hypogonadism, mental retardation. 3 patients had legal blindness (in <6/60) before the age of 20 years. Polydactyly, obesity, hypogonadism was present in all 4 cases. Cockayne's syndrome was seen in 2 cases. Both the cases females with AR mode of inheritance. They had the following systemic features. Short stature, bird like

facies, precocious senility and sensitivity to light. Salt and pepper type retinopathy was seen in only one case. Profound loss of vision noted in one case before 15 years of age.

5. Conclusion

RP occurs more in males than in females with ratio 3:2. Incidence was found to be 2 in 5000 cases (1,21,155 O.P. cases) Prevalence of syndromic RP in this case study was 20% The onset is usually in the first and second decades of life. No variation is seen in urban and rural population. Night blindness is the initial symptom and is present in all cases. The incidence of hereditary and sporadic cases is nearly equal. Among the hereditary type's consanguinity plays a role in the transmission of RP. 75% of patients have typical RP and the remaining have atypical features. Age of onset is earlier in Autosomal Recessive and X-Linked Recessive cases and slightly delayed in sporadic cases. Severity is more in males and females. The following ocular associations are seen with RP: Cataract – seen in Autosomal Recessive and sporadic cases. Myopia – seen more commonly in Autosomal Recessive and sporadic cases. Macular dystrophy – seen in all the three modes of transmission Keratoconus and glaucoma are rare. Usher's syndrome, Bardet Biedl syndrome and Cockayne's syndrome are the systemic association seen with RP. Treatment trials with Vitamin A therapy and Superficial Temporal Artery ligation are ineffective in producing clinical results. Commonest cause of loss of central vision is due to involvement of the fovea by Retinitis pigmentosa itself. Periodic vision testing and visual field examination can help to reassure the patient and appreciate progression and hence plan for future disability. Correction of refractive error will greatly improve visual acuity. Low vision aids allow patients to continue to read or work longer than otherwise possible. Supportive genetic counselling, may help the patient appreciate the range & extent of manifestation shown by other family member and the expected rate of progression. Avoidance of consanguineous marriage. If facilities for ERG are available it should be done for all RP cases to detect early loss of photoreceptor function and may provide prognostic clues.

6. Source of Funding

None.

7. Conflict of Interest

None.

References


1. Jay M, Phil M. Nettleship's two pedigrees of retinitis pigmentosa: A historical postscript. *Surv Ophthalmol.* 1983;27(4):264–8.
2. François J, Verriest G. Rétinopathie pigmentaire unilatérale. *Ophthalmologica.* 1952;124(2):65–88.

3. Fishman GA. Retinitis pigmentosa: genetic percentages. *Arch Ophthalmol.* 1978;96(5):822–6.
4. Duke-Elder S. System of ophthalmology. St. Louis: Mosby; 1958.
5. Merin S, Auerbach E. Retinitis pigmentosa. *Surv Ophthalmol.* 1976;20(5):303–46.
6. Weleber RG. The Cuban Experience: False Hope for a Cure for Retinitis Pigmentosa. *Arch Ophthalmol.* 1996;114(5):606.
7. Ammann F, Klein D, Franceschetti A. Genetic and epidemiological investigations on pigmentary degeneration of the retina and allied disorders in Switzerland. *J Neurol Sci.* 1965;2(2):183–96.
8. Botermans CH. Primary pigmentary retinal degeneration and its association with neurological diseases. In: Handbook of clinical neurology. vol. Vol 13; 1972. p. 148–379.
9. Moore AT, Fitzke F, Jay M, Arden GB, Inglehearn CF, Keen TJ, et al. Autosomal dominant retinitis pigmentosa with apparent incomplete penetrance: a clinical, electrophysiological, psychophysical,

and molecular genetic study. *Br J Ophthalmol.* 1993;77(8):473–9.

Author biography

Balaji Gopinath, Professor

Niranjan Karthik Senthil Kumar, Junior Resident
 <https://orcid.org/0000-0001-7030-4569>

Cite this article: Gopinath B, Kumar NKS. A clinico epidemiological study of retinitis pigmentosa and associated syndromes – A prospective observational study. *Indian J Clin Exp Ophthalmol* 2022;8(3):368-373.