

Content available at: <https://www.ipinnovative.com/open-access-journals>

Indian Journal of Clinical and Experimental Ophthalmology

Journal homepage: [www.ijceo.org](http://www.ijceo.org)

## Original Research Article

## Visual outcomes in pediatric traumatic cataract

Dheerendra Singh<sup>1</sup>, Sumaiya Hasan<sup>1,\*</sup>, Neha Singh Jat<sup>1</sup>, Vivek Paul Buddhé<sup>1</sup><sup>1</sup>Dept. of Ophthalmology, ASG Eye Hospital, Bhopal, Madhya Pradesh, India

## ARTICLE INFO

## Article history:

Received 08-05-2021

Accepted 19-06-2021

Available online 03-01-2022

## Keywords:

Capsulorhexis

Pediatric cataract

Trauma

## ABSTRACT

**Purpose:** To study epidemiology, biometry and visual outcomes (with or without posterior capsulorhexis) in cases of pediatric traumatic cataract.

**Materials and Methods:** This was a prospective observational study conducted on 30 children of traumatic cataract belonging to an age group of less than 16 years. All patients were subjected to detailed history and ocular examination. Patients underwent cataract surgery with or without intraocular lens (IOL) implantation. Posterior capsulorhexis with posterior optic capture was done in all patients presenting with primary posterior capsular opacity. All patients were followed up till 6 months and surgical outcomes in terms of Best Corrected Visual Acuity (BCVA), and visual axis opacification (VAO) were observed.

**Result:** Firecracker injury was found to be the most common causal agent, followed by arrow and ball injuries. Males were more commonly injured than females (70%:30%). Open-globe injury was more frequent than closed globe injury (CGI) (53.3%:46.7%). Anterior capsular rupture was the most frequent preoperative complication. Mean axial length was 22.53 which was not significantly different from the fellow eye. 3 patients were left aphakic, 10 patients underwent single piece IOL implantation and 16 patients underwent multipiece IOL implantation. Anterior chamber IOL (ACIOL) was implanted in one case. Intraoperatively 6 patients were found to have posterior capsular plaque and were implanted with multipiece IOL with posterior optic capture. Visual acuity significantly improved in 21 out of 30 eyes from baseline after cataract surgery ( $p < 0.001$ ). 9 patients (30%) had posterior capsular opacification (PCO) on follow up.

**Conclusion:** Posterior capsular opacity in pediatric traumatic cataracts can be effectively managed with posterior capsulorhexis and posterior optic capture.

This is an Open Access (OA) journal, and articles are distributed under the terms of the [Creative Commons Attribution-NonCommercial-ShareAlike 4.0 License](https://creativecommons.org/licenses/by-nc-sa/4.0/), which allows others to remix, tweak, and build upon the work non-commercially, as long as appropriate credit is given and the new creations are licensed under the identical terms.

For reprints contact: [reprint@ipinnovative.com](mailto:reprint@ipinnovative.com)

## 1. Introduction

Ocular trauma is one of the most common causes of visual morbidity which is associated with significant psychological as well as economic burden to not only patients but also to the society.<sup>1–4</sup> In India, ocular injuries account for approximately 20.53% among all injuries which may affect vision.<sup>5</sup> Ocular trauma may be mechanical (open globe injury and closed globe injury) or non-mechanical, both of which may cause traumatic cataract.<sup>6</sup> The mechanism

of traumatic cataract following ocular injury is complex which may be due to rupture of the lens capsule or zonular ligament, the oscillation of lens cortex or disorder of lens metabolism caused by collision.<sup>7</sup>

Traumatic cataract may develop immediately or up to several years following injury. Based upon the mode of injury, shape and location of traumatic cataract may vary.<sup>8</sup>

With the advent of microsurgical techniques and better intraocular lens (IOL) designs, traumatic cataract can be managed effectively to provide better outcomes with fewer complications. However, cataract surgery, specially

\* Corresponding author.

E-mail address: [dr.sumaiya.hasan95@gmail.com](mailto:dr.sumaiya.hasan95@gmail.com) (S. Hasan).

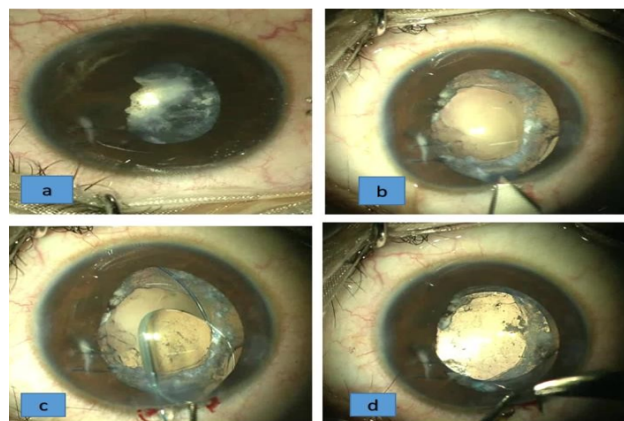
in the pediatric age group is associated with postoperative problems such as fibrinous uveitis, posterior capsular opacification (PCO), posterior synechiae, IOL decentration, pupillary capture, precipitates over IOL surface, and amblyopia.<sup>9</sup>

Visual outcome in such cases may depend upon numerous factors. Kuhn et al. developed the OTS (ocular trauma score) which may help in predicting visual outcome of traumatic eyes.<sup>10</sup> However, studies reporting the outcome of traumatic cataract in pediatric age group are limited and thus, the present study was conducted to assess the epidemiology, biometry and visual outcomes (with or without posterior capsulorhexis) in cases of pediatric traumatic cataract.

## 2. Materials and Methods

The study was conducted after taking approval from the institutional ethics committee. It was a hospital based, prospective, observational study conducted on 30 children diagnosed with traumatic cataract from December 2019 to June 2020. All patients aged < 16 years having unilateral traumatic cataract and their parents giving written informed consent were included in the study. Patients with bilateral cataract, those not willing for surgery or patients lost to follow up were excluded from the study.

Detailed data regarding socio-demographic variables such as age, gender and socioeconomic status was obtained from all the study participants. Data regarding time elapsed since injury, mode, type and nature of injury was obtained and documented in pretested semi structured questionnaire. All patients were subjected to detailed ocular examination including visual acuity and slit lamp examination of affected and fellow eye. The diagnosis and classification of ocular trauma was based on the Birmingham Eye Trauma Terminology (BETT) which is a standardized ocular trauma definition and classification system for mechanical eye injuries.<sup>11</sup> Axial length measurement and corneal topography was done for all patients. IOL power was calculated using the Hoffer Q formula. Wherever required, additional investigations such as B scan ultrasonography, MRI or CT scans were carried out. Cataract extraction was performed along with primary repair, in case of open globe injuries, using phaco assisted lens aspiration and IOL was implanted. Posterior capsulorhexis with posterior optic capture was done in those patients who presented with posterior capsular opacity. Postoperatively, all patients were given topical corticosteroid and antibiotics. The patients were followed up at 1 week, 1 month and 6 months postoperatively, with appropriate amblyopia management and adequate refractive correction. Surgical outcomes in terms of BCVA, and visual axis opacification (VAO) were observed.



**Fig. 1:** **a:** Post traumatic cataract; **b:** Both anterior and posterior rhexis made; **c:** Multipiece injected over anterior capsule; **d:** Posterior capture of optic

### 2.1. Statistical analysis

Data was compiled using MS Excel and analysed using IBM SPSS software version 20. Categorical data was expressed as frequency and percentage and numerical data was expressed as mean and SD. T test was calculated for assessing difference between mean whereas Chi square test was applied for calculating the difference in proportions. P value less than 0.05 was considered statistically significant.

## 3. Results

The mean age of children with traumatic cataract was  $6.28 \pm 3.2$  years and majority of patients with traumatic cataract were males (70% males and 30% females). Cataract was observed in left eyes in 56.7% cases whereas right eye was affected in 43.3% cases.

Most common cause of traumatic cataract was firecracker injury (16.7%) followed by blunt injury by ball (13.3%). Open globe rupture was frequently observed as compared to closed globe injury in 53.3% and 46.7% cases respectively.

Anterior capsule rupture was found to be the most common complication following traumatic cataract (60%), followed by posterior capsular rupture in 16.7% cases, retinal detachment and adherent leucoma in 13.3% cases each. Secondary glaucoma and iridodialysis was the least common complication observed in 3.3% cases each.

Mean axial length in the affected eye was  $22.4 \pm 1.29$  whereas in the fellow eye was  $22.53 \pm 1.17$  which was not statistically significant. However, mean K1 was significantly lower in affected eye ( $41.93 \pm 2.32$  D) as compared to the fellow eye ( $42.6 \pm 2.5$  D) ( $p < 0.05$ ). The study observed no statistically significant difference in mean K2, K average and IOL power between affected and normal eye ( $p > 0.05$ ).

3 patients (10%) in our study were left aphakic, while single piece IOL was implanted in 10 (33.3%) patients

**Table 1:** Distribution according to nature and type of injury

Injury	No. of eyes (n=30)	Percentage
Firecracker	5	16.7
Ball	4	13.3
Arrow	2	6.7
Wire	2	6.7
Stone	2	6.7
Glass	2	6.7
Pencil/Pen	2	6.7
Knife/ Scissor	2	6.7
Cause		
Nail	1	3.3
Hypodermic Needle	1	3.3
Mobile Phone	1	3.3
Dog Scratch	1	3.3
Door Knob	1	3.3
Plastic Bottle	1	3.3
Shoe	1	3.3
Steel Tongue Cleaner	1	3.3
Unknown Object	1	3.3
Type		
Closed globe	14	46.7
Open globe	16	53.3

**Table 2:** Distribution according to complications

Complications	No. of eyes (n=30)	Percentage
Anterior capsule rupture	18	60
Posterior capsule rupture	5	16.7
Secondary glaucoma	1	3.3
Retinal detachment	4	13.3
Adherent leucoma	4	13.3
Iridodialysis	1	3.3
Subluxation	3	10
Posterior plaque	2	6.7
Vitreous hemorrhage	2	6.7
Vitreous in AC	2	6.7
Aniridia	2	6.7
Sphincter tear	2	6.7
Traumatic optic neuropathy	3	10

**Table 3:** Comparison of biometry between affected eye and fellow eye

	Affected eye		Normal eye		P value
	Mean	SD	Mean	SD	
Axial length	22.4	1.29	22.53	1.17	0.134
K1	41.93	2.32	42.60	2.5	0.04
K2	44.2	3.1	43.7	1.97	0.22
K average	43.00	2.477	43.00	2.166	1.0
IOL power	23.73	2.74	22.93	4.71	0.22

and multipiece IOL in 16 (53.3%) patients. ACIOL was implanted in one (3.3%) case. Mean IOL power inserted was  $21.03 \pm 7.5$  D.

**Table 4:** Improvement in visual acuity at final follow up

Visual acuity	At baseline		6 month	
	n	%	n	%
Not following/fixing	5	16.7	2	6.7
PL	7	23.3	2	6.7
HMCF	12	40.0	3	10.0
1/60-3/60	5	16.7	2	6.7
4/60-5/60	1	3.3	8	26.7
6/60-6/18	0	0	5	16.7
Better than 6/18	0	0	8	26.7
P value	0.04			

The visual acuity significantly improved as compared to baseline after cataract surgery ( $p < 0.05$ ).

Intraoperatively 6 (20%) patients were found to have posterior capsular plaque and were implanted with multipiece IOL with posterior optic capture.

9 patients (30% had posterior capsular opacification on follow up.

#### 4. Discussion

The present study was conducted on a total of 30 consecutive pediatric eyes with traumatic cataract to study the causes, biometry and visual outcome post cataract extraction among these patients. Pediatric traumatic cataract is a treatable cause of childhood blindness which accounts for approximately 7.4%–15.3% of pediatric blindness.<sup>12,13</sup> The mean age of children with traumatic cataract in our study was  $6.28 \pm 3.2$  years. Male dominance for traumatic cataract was observed in our study with 70% males and 30% females. Almost equal proportions of right and left eyes were found to be affected. Our study findings were concordant with the findings of Jinagal et al. in which mean age of children with pediatric cataract was  $7.67 \pm 3.30$  years and male dominance was documented. Right as well as left eyes were involved in almost equal proportions in the reference study.<sup>9</sup> Similarly, Shah et al. also documented male predominance for traumatic cataract.<sup>14</sup> Higher incidence of traumatic cataract among males could be attributed to higher involvement of male children in sports as well as outdoor activities.

Most common cause of injury in our study was by firecrackers (16.7%), whereas in 13.3% cases, traumatic cataract was due to injury by ball. Bow and arrow related injuries were observed in 6.7% cases. Shah et al<sup>14</sup> and Jinagal et al<sup>9</sup> documented wooden stick injury and fire cracker injury as the most common cause of traumatic cataract. Injury by sharp metal was the most common cause of traumatic cataract in a study by Xu et al.<sup>15</sup>

Open globe rupture was frequently observed in 53.3% cases in our study as compared to closed globe injury in 46.7%. This could be attributed to penetrating causes contributing to traumatic cataract in our study. These findings were supported by findings of Xu et al, in which out of 117 cases, open globe injuries were observed in 91 cases.<sup>15</sup>

Our study documented anterior capsular rupture as the most common complication in 60% cases followed by posterior capsule rupture in 16.7% cases. However, corneal laceration followed by anterior capsule violation were the most common complications in cases with open globe injury, and traumatic mydriasis in cases with closed-globe injuries in the study by Xu et al.<sup>15</sup>

Though, the difference in axial length, biometry as well as IOL power between affected and normal eyes were statistically insignificant but the mean K1 was significantly lower in affected eye as compared to normal eye, which could be attributed to flattening caused by the injury. Multipiece IOL was used in majority of cases (53.3%), whereas ACIOL was implanted in one (3.3%) case. 3 eyes (10%) were left aphakic. Mean power of implanted intraocular lens was  $21.03 \pm 7.5$  D. Jinagal et al recorded average axial length in affected eye as  $22.26 \pm 2.21$  mm and mean IOL power implanted in these patients was  $22.96 \pm 0.89$  D.<sup>9</sup> In a study by Hilely et al, cataract removal was conducted in 16 cases, out of which, intraocular lens (IOL) was implanted in 14 (87.5%) cases, whereas in 2 eyes, IOL was not implanted.<sup>16</sup>

Though, cataract surgery followed by IOL implantation is the management of choice in cases of pediatric cataract, but post operative inflammation, secondary membrane formation, and amblyopia are potential challenges observed following surgery.<sup>9</sup> Our study documented that visual acuity significantly improved following cataract surgery ( $p < 0.05$ ) at final follow up. 20% cases were found to have posterior capsular plaque intraoperatively and underwent posterior optic capture with multipiece IOL. Though long-term visual outcome was better in significantly high proportion of patients, however 30% eyes developed posterior capsular opacification on follow up. In a similar conclusion, Jinagal et al in their study also obtained satisfactory visual outcome in children with traumatic cataract.<sup>9</sup> Trivedi et al documented higher rate of PCO formation in paediatric eyes with traumatic cataract.<sup>17</sup> However, Benezra et al in their study observed visual axis obstruction in as high as 100% cases in eyes which underwent traumatic cataract surgery without Primary Posterior Capsulotomy (PPC) and anterior vitrectomy.<sup>18</sup> Verma et al reported significantly lower incidence of Visual axis obstruction in patients who underwent PPC during cataract surgery as compared to the group who did not.<sup>19</sup> Thus, posterior capsulotomy is recommended to maintain clear visual axis and avoiding the need of secondary interventions.

## 5. Conclusion

Traumatic cataract in pediatric population is one of the leading causes of treatable blindness affecting higher proportions of males. Such cases can be effectively managed with cataract surgery with IOL implantation. Visual outcome has shown to improve significantly following surgery but rate of PCO is high, which can be effectively managed with posterior capsulorhexis and posterior optic capture.

## 6. Source of Funding

None.

## 7. Conflict of Interest

The authors declare no conflict of interest.

## References

- Qi Y, Zhang FY, Peng GH, Zhu Y, Wan GM, Wang WZ. Characteristics and visual outcomes of patients hospitalized for ocular trauma in central China: 2006–2011. *Int J Ophthalmol*. 2015;8(1):162–8.
- Cao H, Li L, Zhang M. Epidemiology of patients hospitalized for ocular trauma in the Chaoshan region of China. *PLoS one*. 2001;7(10):e48377.
- Wang JD, Xu L, Wang YX, You QS, Zhang JS, Jonas JB. Prevalence and incidence of ocular trauma in North China: the Beijing Eye Study. *Acta Ophthalmol*. 2012;90(1):61–7.
- Maurya RP, Singh VP, Yadav I, Singh MK, Mishra CP, Sen PR, et al. Profile of pediatric ocular trauma at a tertiary eye care center in Northern India. *Indian J Clin Exp Ophthalmol*. 2015;1(2):76–83.
- Bhatia IM, Panda A, Dayal Y. Role of ultrasonography in ocular trauma. *Indian J Ophthalmol*. 1983;31(5):495.
- Khatry SK, Lewis AE, Schein OD, Thapa MD, Pradhan EK, Katz J. The epidemiology of ocular trauma in rural Nepal. *Br J Ophthalmol*. 2004;88(4):456–60.
- Qi Y, Zhang YF, Zhu Y, Wan MG, Du SS, Yue ZZ. Prognostic factors for visual outcome in traumatic cataract patients. *J Ophthalmol*. 2016;2016:1748583. doi:10.1155/2016/1748583.
- Shah MA, Shah SM, Shah SB, Patel CG, Patel UA. Morphology of traumatic cataract: does it play a role in final visual outcome. *BMJ Open*. 2011;1(1):e000060. doi:10.1136/bmjopen-2011-000060.
- Jinagal J, Gupta G, Gupta PC, Yangzes S, Singh R, Gupta R, et al. Visual outcomes of pediatric traumatic cataracts. *Eur J Ophthalmol*. 2019;29(1):23–7.
- Kuhn F, Maisiak R, Mann L, Mester V, Morris R, Witherspoon CD. The ocular trauma score (OTS). *Ophthalmol Clin North Am*. 2002;15(2):163–6.
- Kuhn F, Morris R, Witherspoon CD. Birmingham Eye Trauma Terminology (BETT): terminology and classification of mechanical eye injuries. *Ophthalmol Clin North Am*. 2002;15(2):139–43.
- Gilbert C, Foster A. Childhood blindness in the context of VISION 2020 - The right to sight. *Bull World Health Organ*. 2001;79(3):227–32.
- Rahi JS, Sripathi S, Gilbert CE, Foster A. Childhood blindness in India: Causes in 1318 blind school students in nine states. *Eye (Lond)*. 1995;9(Pt 5):545–50.
- Shah MA, Shah MA, Applewar A, Patel C, Patel K. Ocular trauma score as a predictor of final visual outcomes in traumatic cataract cases in pediatric patients. *J Cataract Refract Surg*. 2012;38(6):959–65.
- Xu YN, Huang YS, Xie LX. Pediatric traumatic cataract and surgery outcomes in eastern China: a hospital-based study. *Int J Ophthalmol*. 2013;6(2):160–4.
- Hilely A, Leiba H, Achiron A, Hecht I, Parness-Yossifon R. Traumatic Cataracts in Children, Long-Term Follow-up in an Israeli Population: A Retrospective Study. *Isr Med Assoc J*. 2019;21(9):599–602.
- Trivedi RH, Wilson ME. Posterior capsular opacification in pediatric eyes with and without traumatic cataract. *J Cataract Refract Surg*. 2015;41(7):1461–4.
- Benezra D, Cohen E, Rose L. Traumatic cataract in children: correction of aphakia by contact lens or intraocular lens. *Am J Ophthalmol*. 1997;123(6):773–82.
- Verma N, Ram J, Sukhija J. Outcome of in-the-bag implanted square edge polymethyl methacrylate intraocular lenses with and without primary posterior capsulotomy in pediatric traumatic cataract. *Indian J Ophthalmol*. 2011;59(5):347–51.

## Author biography

**Dheerendra Singh**, Fellow

**Sumaiya Hasan**, Fellow  <https://orcid.org/0000-0002-7830-2143>

**Neha Singh Jat**, Fellow

**Vivek Paul Buddhé**, Fellow

**Cite this article:** Singh D, Hasan S, Jat NS, Buddhé VP. Visual outcomes in pediatric traumatic cataract. *Indian J Clin Exp Ophthalmol* 2021;7(4):707–711.