

Content available at: <https://www.ipinnovative.com/open-access-journals>

Indian Journal of Clinical and Experimental Ophthalmology

Journal homepage: www.ijceo.org

Original Research Article

Changes in macular thickness post uncomplicated MSICS & phacoemulsification surgery

Kartika Anand^{1,*}, Ashutosh Dokania¹¹Dept. of Ophthalmology, Rohilkhand Medical College and Hospital, Bareilly, Uttar Pradesh, India

ARTICLE INFO

Article history:

Received 05-11-2021

Accepted 10-11-2021

Available online 03-01-2022

Keywords:

No financial disclosure Cataract Surgery

Macular thickness

MSICS

Phacoemulsification

Visual Acuity

ABSTRACT

Aims: To evaluate changes in macular thickness via-a-vis visual acuity post uncomplicated manual small incision cataract surgery (MSICS) & phacoemulsification surgery**Materials and Methods:** Prospective clinical study on 160 patients of uncomplicated immature senile cataract, aged 40-70yrs, patients were randomised into two groups, MSICS & phacoemulsification, by simple 1:1 randomization, who underwent uncomplicated cataract surgery with posterior chamber intraocular lens (PCIOL). Post-operatively, the patients were evaluated for best corrected visual acuity (BCVA) and changes in macular thickness by optical coherence tomography (OCT) at post-op Day 1, 7, 21, 48, and 12 weeks. Paired t-test was used for comparison across follow up.**Results:** At 12 weeks post-operative, mean logMAR BCVA was 0.01±0.02 for MSICS group and 0±0.02 for Phacoemulsification group. Macular thickness was not statistically significant (p=0.342) between MSICS group (219.19±17.88µm) and Phacoemulsification group (215.61±16.21µm), at the end of 12 weeks post-operative. Clinically significant macular oedema was not diagnosed in any of the patients at the follow-ups.**Conclusion:** Both procedures achieved good post-operative Best Corrected visual acuity without significant differences in BCVA between both the groups at the end of 12 weeks.This is an Open Access (OA) journal, and articles are distributed under the terms of the [Creative Commons Attribution-NonCommercial-ShareAlike 4.0 License](https://creativecommons.org/licenses/by-nc-sa/4.0/), which allows others to remix, tweak, and build upon the work non-commercially, as long as appropriate credit is given and the new creations are licensed under the identical terms.For reprints contact: reprint@ipinnovative.com

1. Introduction

One of the leading causes of preventable blindness is cataract. It is a disease that significantly influences the quality of life of patients. The world health organization (WHO) estimates that at least 20 million people worldwide are blind because of cataract, resulting in 51% of blindness globally. Maximum number of cases of blindness caused by cataract are seen in developing countries.¹

Due to the growing population and increasing life span, the number of surgeries being performed globally has to be increased three-fold, to keep-up with the increasing requirement, as improved visual status post-cataract surgery

correlates with reduced morbidity and improved quality of life.²

The first documented method of treating cataract, couching was performed by Sushruta.³ Cataract surgery, since then, has progressed over time, from intracapsular cataract surgery to phacoemulsification with microsurgical techniques. However, in third world countries like ours, higher cost of phacoemulsification techniques and disposable supplies, as well as more advanced surgical training are the major limiting factors.⁴ In such scenarios, manual small incision cataract surgery (MSICS) can be considered as a cost-effective alternative to phacoemulsification.^{5,6}

One of the many causes for poor vision post-cataract surgery is cystoid macular edema (CME), also known

* Corresponding author.

E-mail address: kartika.anand@gmail.com (K. Anand).

as Irvine-Gass syndrome.⁷ However, with the advent of surgeries like MSICS and phacoemulsification, CME incidence has come down.⁸

As the incision size is larger and manipulation of iris is more, the CME incidence is reported to be higher in MSICS. Sub-clinical edema and even Clinical CME after uneventful surgery of cataract has been reported in both MSICS and Phacoemulsification, with greater risk after MSICS. This edema, however, did not affect the post-operative visual outcome in due course of time in majority of cases.^{9,10}

This study aims at comparing post-operative visual acuity as well as macular thickness by optical coherence tomography (OCT), following uneventful MSICS and phacoemulsification.

2. Materials and Methods

Prospective clinical study was done on 160 eyes of 160 patients having uncomplicated immature senile cataract (IMSC), aged 40-70yrs, with 80 patients each randomised into two groups, by simple 1:1 randomization. Group A underwent manual small incision cataract surgery (MSICS) & group B underwent phacoemulsification. The study was conducted from 1st October 2019 to 31st September 2020, at Rohilkhand Medical College and Hospital, Bareilly, Uttar Pradesh, India, and was approved by its review board and ethical committee.

A written and informed consent was taken from all the patients explaining the nature of the study. Exclusion criteria were, any cataract other than immature senile cataract (e.g. mature senile cataract, complicated cataract, post traumatic cataract or subluxated cataract), maximum pupil size <6mm, pre-existing glaucoma, pre-existing media opacity other than cataract, any pre-existing posterior segment pathology, patients with diabetes mellitus, or other diseases which could affect macula.

Relevant history was noted on the study Proforma, including Onset and progression of diminution of vision (DOV), any antecedent history of trauma, recurrent redness, family history of early onset cataract, systemic history, any previous ocular surgery.

A detailed ocular examination was undertaken employing BCVA, corneal curvature radius measurement with an automatic refractometer, detailed anterior segment examination by slit-lamp examination, detailed posterior segment examination using indirect ophthalmoscope, Intraocular pressure (IOP) measurement with a Goldmann Applanation Tonometer, biometry for IOL power, OCT scan to obtain central macular thickness (CMT) using Spectral Domain OCT (SD-OCT).

Image acquisition: patient's pupils were dilated before image acquisition every time using a combination mydriatic eye drop (tropicamide 5% + phenylephrine 0.8%). SD-OCT was used to acquire CMT, using the macular thickness map protocol. These scans are averaged by the OCT software

using an automated computerized algorithm and the result is presented with comparison to the normative database.

Pre-operatively, the eye to be operated was dilated using a combination mydriatic eye drop (Tropicamide 5% + Phenylephrine 0.8%) and additionally eye drops Flurbiprofen 0.03% was instilled for sustenance of dilated pupils. Local anaesthesia via peribulbar route was given through the lower eyelid at lateral 1/3rd and medial 2/3rd junction, adjacent to orbital margin.

All surgeries were done by the same surgeon. For group A, superior rectus bridle suture was taken, peritomy was done from 10-2 o'clock & sclera exposed. After cauterizing any bleeders, frown incision was made on the sclera, followed by sclero-corneal tunnel formation and side-port entry at 10 o'clock. For group B, side port was entry was made at 10 & 1 o'clock position. Trypan blue dye was injected and washed, followed by viscosurgical devices to maintain depth of anterior chamber. Capsulorrhexis was done followed by hydrodissection and hydrodelineation. In MSICS, entry into anterior chamber was made by keratome, nucleus was prolapsed into the anterior chamber & removed, while in group B, Phacoemulsification was done using AMO Sovereign Compact (Whitestar Cold Phaco, USA) and nucleus was removed after emulsifying it. Irrigation and aspiration of cortical matter was done.

In Group A, a polymethyl methacrylate (PMMA) non-foldable IOL was implanted. In Group B, a foldable hydrophilic acrylic IOL was implanted using a lens injector.

Remaining viscoelastic material was removed using Simco's cannula. In the end sub-conjunctival injection Dexamethasone and Gentamycin combination was given in the operated eye in every case. After instilling topical broad-spectrum antibiotic eye drops, eyes were pad-patched.

Post-operatively, patients received antibiotic-steroid combination eye drops, tapered gradually over 4 weeks, as well as, eye drop Flurbiprofen 0.03% thrice a day and eye drop Tropicamide 1% at night for 2 weeks.

Oral antibiotics (Tablet Ciprofloxacin 500mg) twice daily for 5 days along with Tablet Ibuprofen 400mg thrice a day and Tablet Ranitidine 150mg were also given.

Post-operative follow-up was done on day 1 & 7, and at the end of 3rd, 6th and 12th weeks in terms of Visual acuity and CMT. Post-operative analysis was done at 12th week post-op.

The presentation of the Categorical variables was done in the form of number and percentage (%) while, the quantitative data were presented as the mean \pm SD, and median with 25th and 75th percentiles (interquartile range). Comparison of the variables which were quantitative in nature were analysed using Independent t test (for two groups). Paired t test was used for comparison across follow up. The final analysis was done with the use of Statistical Package for Social Sciences (SPSS) software, IBM manufacturer, Chicago, USA, version 23.0. For

statistical significance, p value of less than 0.05 was considered statistically significant.

3. Results

160 eyes of 160 patients having uncomplicated IMSC were enrolled in this study. They were distributed into two groups: Group A included 80 subjects (50%) who underwent MSICS, while group B included 80 subjects (50%), who underwent phacoemulsification surgery.

In the study, age of the patients ranged from 40-70 years in both groups. The mean age in years was 56.65 ± 8.10 in MSICS group, while 55.82 ± 7.50 in phacoemulsification group. The difference in these two groups was not significant statistically for age distribution (p value=0.505) as it is depicted in Figure 1.

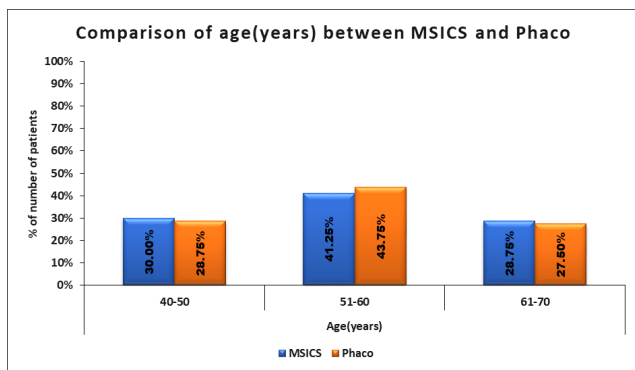


Fig. 1: Comparison of age(years) between MSICS and Phacoemulsification

There were 40 males and 40 females (i.e. 50% males and 50% females) in both the groups. The difference for gender distribution between the two groups was statistically insignificant (p value=1) as depicted in Figure 2.

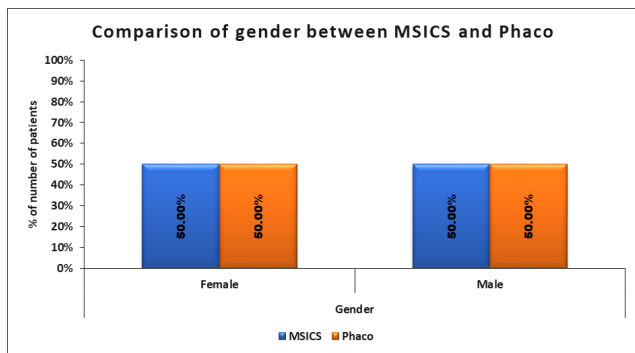


Fig. 2: Comparison of gender between MSICS and Phacoemulsification

Mean logMAR BCVA in MSICS group on pre-operative, post-operative day 1, post-operative day 7, post-operative 3weeks, post-operative 6weeks and post-operative 12 weeks

was 0.94 ± 0.24 , 0.09 ± 0.13 , 0.01 ± 0.03 , 0.01 ± 0.02 , 0.01 ± 0.02 and 0.01 ± 0.02 respectively while in phaco group it was 0.89 ± 0.25 , 0.07 ± 0.08 , 0.01 ± 0.03 , 0 ± 0.02 , 0 ± 0.02 and 0 ± 0.02 respectively. Statistically significant difference was not seen in visual acuity at pre-operative (p value=0.209) and post-operative day 1(p value=0.237), post-operative day 7(p value=0.579) and (p value =0.701) at post-operative 3weeks, 6weeks and 12 weeks between MSICS and phaco group. It is depicted in Figure 3.

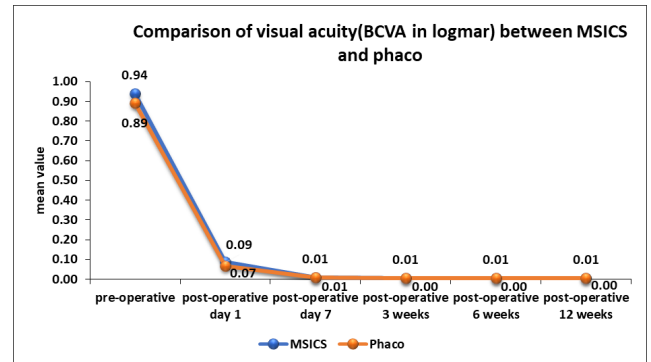


Fig. 3: Comparison of best corrected visual acuity (logMAR) between MSICS and Phacoemulsification

Central macular thickness(μm) at post-operative 3 weeks and post-operative 6weeks in MSICS group was 225.58 ± 16.15 and 229.32 ± 16.74 respectively and in phaco group 220.06 ± 14.34 and 222.62 ± 15.22 respectively which was significantly higher in MSICS group with p value 0.024 at 3weeks post-op and p value=0.009 at 6weeks post-op respectively.

Central macular thickness at pre-operative, post-operative day 7, post-operative 12 weeks in MSICS group was 213.78 ± 19.28 , 219.49 ± 16.89 , 218.19 ± 17.88 respectively and in phaco group was 213.32 ± 15.16 , 218.01 ± 14.16 , 215.61 ± 16.21 respectively. No significant difference was seen in central macular thickness(μm) at pre-operative (p value=0.87), post-operative day 7(p value=0.55), post-operative 12 weeks (p value=0.342) between MSICS and phaco groups. It is depicted in Figures 4 and 5.

4. Discussion

Following a cataract surgery, among complications, central macular oedema specially is a significant cause of decreased vision post-operatively. With the advancements in surgical techniques, presently it is possible to achieve faster surgeries with lesser complication rates, conventional ECCE giving lesser complications than ICCE due to the presence of an intact posterior capsule. These complications have further reduced with the advent of modern techniques such as MSICS and phacoemulsification surgeries.^{9,11}

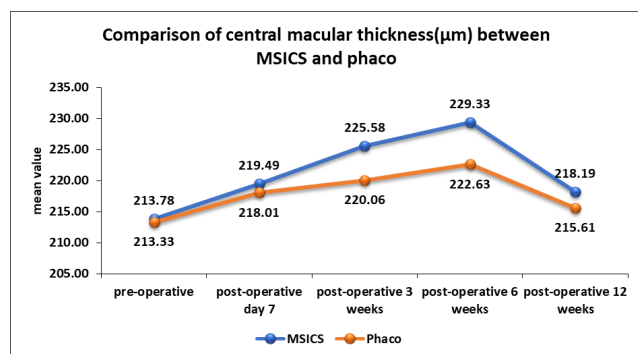


Fig. 4: Comparison of trend of macular thickness (μm) at different time intervals between MSICS and Phacoemulsification

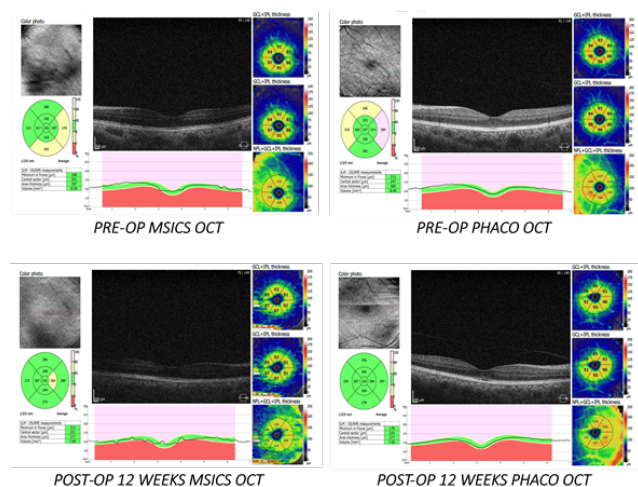


Fig. 5: Pre-op and 12 weeks Post-op OCT of a patient of MSICS and of Phacoemulsification group

Mean age of patients was 56.65 ± 8.10 years & 55.82 ± 7.5 years in MSICS & Phaco group respectively in this study. This was comparable to study by Khanna et al,¹² which included patients with mean age group of 57.4 years & 55.1 years in MSICS & phacoemulsification group. In study done by Venkatesh et al¹³ mean age was 56.6 ± 9.5 in MSICS group while 56 ± 9.3 in phaco group. This age group was considered as there is maximum prevalence of uncomplicated senile immature cataract in this age group of patients and to avoid any bias in parameters as compared to younger age group.

In our study, there were 80 females (50%) and 80 (50%) males with a ratio of 1:1 in each group individually also. The distribution of gender was comparable between both the groups thus showing no gender predilection (p value=1). Other studies showed similar results. Male:Female ratio was 1:1 in MSICS and phaco group respectively in the study by Khanna et al,¹² and 1: 1.3 in study by Venkatesh et al.¹³

The mean BCVA at post-op 12 weeks was 0.01 ± 0.02 & 0 ± 0.02 in group A & B respectively. The difference was

not significant ($p=0.701$). Visual acuity was significantly improved from pre-operative to post-operative 3 weeks with no change from post-operative 3 weeks till post-operative 12 weeks. The results are comparable to the study done by Ruit et al.⁴ They conducted a prospective study comparing the efficacy as well as visual results of the MSICS vs phacoemulsification in Nepal and found that at six months, 98% of the patients had a BCVA of 20/60 or better by six months in both MSICS and phacoemulsification group. Another study by Venkatesh et al¹³ reviewed the records of approximately 600 patients. At 6 weeks, BCVA was 20/60 or better in 99% in the phacoemulsification surgery group and 98.0% in the manual SICS group

The mean CMT (μm) at post-op 12 weeks was 218.19 ± 17.88 & 215.61 ± 16.21 in group A & B respectively. The difference was not significant between the two groups ($p=0.342$). A statistically significant rise in thickness of central macula was noticed postoperatively at 1 week ($p < 0.0001$ for MSICS group, $p < 0.0001$ for phacoemulsification group) and 6 weeks ($p < 0.0001$ for group A and $p < 0.0001$ for group B), in all patients. It returned to near normal values by 3 months post operatively. This increase was mostly sub-clinical. Clinically significant macular oedema was not diagnosed in any of the patients at the follow-ups. Similar observations were made by Ghosh et al⁹ after uncomplicated MSICS & Phaco. Montes et al¹¹ and Biro et al¹⁴ also had similar observations after uncomplicated phacoemulsification. Chaudhary et al¹⁰ found that statistically significant rise in thickness of macula was noticed postoperatively at 1 week ($p = 0.05$ for MSICS group, $p = 0.1$ for phacoemulsification group) and 1 month ($p = 0.001$ for MSICS group and $p \leq 0.05$ for phacoemulsification group), in all patients. It returned to near normal values by 3 months post operatively. This increase was mostly sub clinical.

Despite a higher theoretical risk of increase in postoperative inflammation after MSICS, there wasn't any evidence of CME, neither clinically nor on OCT. Even so, chances of sub-clinical rise in CSMT was higher after MSICS as compared to phacoemulsification which could be attributed to more tissue trauma and iris manipulation associated with MSICS. Trauma during surgery to iris, ciliary body and the lens epithelial cells is known to release phospholipids, and thereby prostaglandins and other inflammatory mediators. These inflammatory mediators diffuse through the vitreous and disrupt the BRB to cause pooling of serum in retina causing macular edema.^{14,15}

Limitations in our study were shorter sample size and lesser period of follow up. Also, this study did not include very dense or mature cataracts, limiting information related to impact of associated variables on CME such as larger incision and more surgical manipulation in MSICS and higher phaco power and duration in Phacoemulsification surgery. A study with larger sample size with longer follow-

up and denser cataracts may be required to compare the parameters.

5. Conclusion

There is a sub-clinical, transient rise in CMT, after surgery in both groups with respect to pre-operative value, and this is significantly higher for the MSICS group than phacoemulsification group in first 6 weeks postoperatively. However, there is not much significant difference in CMT in the two groups on the final follow up at 12 weeks. This has minimal impact on postoperative best corrected visual acuity at 12 weeks post-op. Both procedures individually, achieve good post-operative Best Corrected visual acuity post-operatively, without significant differences in BCVA between the two groups at the end of 12 weeks post-op. Hence, MSICS can be considered as a faster, cheaper alternative to phacoemulsification giving good post-operative BCVA, especially in high volume, developing countries.

6. Source of Funding

None.

7. Conflict of Interest

None.

References

1. The P, Mariotti SP. Global estimates of visual impairment: 2010. *Br J Ophthalmol*. 2012;96(5):614–8.
2. Wang W, Yan W, Fotis K, Prasad NM, Lansingh VC, Taylor HR. Cataract surgical rate and socioeconomic: a global study. *Invest Ophthalmol Vis Sci*. 2016;57(14):5872–81.
3. Roy PN, Mehra KS, Deshpande PJ. Cataract surgery performed before 800 B.C. *Br J Ophthalmol*. 1975;59(3):171.
4. Ruit S, Tabin G, Chang D, Bajracharya L, Kline DC, Richeimer W, et al. A prospective randomized clinical trial of phacoemulsification vs manual suture less small-incision extra-capsular cataract surgery in Nepal. *Am J Ophthalmol*. 2007;143(1):32–8.
5. Gogate PM, Kulkarni SR, Krishnaiah S, Deshpande RD, Joshi SA, Palimkar A, et al. Safety and efficacy of phacoemulsification compared with manual small incision cataract surgery by a randomized controlled clinical trial: six-week results. *Ophthalmology*. 2005;112(5):869–74.
6. Bourne RRA, Minassian DC, Dart JKG, Rosen P, Kaushal S, Wingate N. Effect of cataract surgery on the corneal endothelium: modern phacoemulsification compared with extracapsular cataract surgery. *Ophthalmology*. 2004;111(4):679–85.
7. Fu A, Bui A, Roe R, Ahmed I, Ai E. Cystoid macular edema. In: Yanoff M, Yanoff JS, editors. *Ophthalmol*. China: Elsevier; 2008. p. 954–62.
8. Chan A, Duker JS, Ko TH, Fujimoto JG, Schuman JS. Normal Macular Thickness Measurements in Healthy Eyes Using Stratus Optical Coherence Tomography. *Arch Ophthalmol*. 2006;124(2):193–8.
9. Ghosh S, Roy I, Biswas PN, Maji D, Mondal LK, Mukhopadhyay S, et al. Prospective randomized comparative study of macular thickness following phacoemulsification and manual small incision cataract surgery. *Acta Ophthalmol*. 2010;88(4):102–6.
10. Chaudhary C, Bahadur H, Gupta N. Study of cystoid macular edema by optical coherent tomography following uneventful cataract surgery. *Int Ophthalmol*. 2015;35(5):685–91.
11. Mentis J, Erakgun T, Afrashi F, Kerci G. Incidence of cystoid macular edema after uncomplicated phacoemulsification. *Ophthalmologica*. 2003;217(6):408–12.
12. Khanna RC, Kaza S, Shantha GPS, Sangwan VS. Comparative outcomes of manual small incision cataract surgery and phacoemulsification performed by ophthalmology trainees in a tertiary eye care hospital in India: a retrospective cohort design. *BMJ Open*. 2012;2(5):e001035. doi:10.1159/000073070.
13. Venkatesh R, Tan CS, Sengupta S, Ravindran RD, Krishnan KT, Chang DF, et al. Phacoemulsification versus manual small-incision cataract surgery for white cataract. *J Cataract Refract Surg*. 2010;36(11):1849–54.
14. Miyake K, Ibaraki N. Prostaglandins and cystoid macular edema. *Surv Ophthalmol*. 2002;47(Suppl 1):S203–18.
15. Yavas GF, rk FO, sbeci TK. Preoperative topical indomethacin to prevent pseudophakic cystoid macular oedema. *J Cataract Refract Surg*. 2007;33(5):804–7.

Author biography

Kartika Anand, Junior Resident

Ashutosh Dokania, Professor and HOD

Cite this article: Anand K, Dokania A. Changes in macular thickness post uncomplicated MSICS & phacoemulsification surgery. *Indian J Clin Exp Ophthalmol* 2021;7(4):619-623.