

Content available at: <https://www.ipinnovative.com/open-access-journals>

Indian Journal of Clinical Anatomy and Physiology

Journal homepage: <https://www.ijcap.org/>

Case Report

Unilateral absence of fibularis tertius: A clinically and evolutionary salient variation

Poonam Verma^{1,*}, Girish Abrol²

¹Dept. of Anatomy, Sri Guru Ram Das Institute of Medical Sciences and Research, Amritsar, Punjab, India

²SGRR Medical College, Dehradun, Uttarakhand, India



ARTICLE INFO

Article history:

Received 07-01-2022

Accepted 24-01-2022

Available online 01-03-2022

Keywords:

Embalmed

Formalin

Morphology

ABSTRACT

Introduction: Fibularis tertius muscle has always cherished the distinction of being an entirely human structure and as such it has aided to separate man from the lower animals. The morphology of the fibularis tertius (FT) is extremely inconstant.

Case Presentation: In the present case we report a rare case of unilateral absence of FT in right foot of a formalin embalmed male cadaver.

Conclusion : The absence of FT may mislead the doctors in performing graft and transplant operations. Hence radiological imaging techniques must be executed to approve the presence of the FT before planning any manoeuvre on foot. Thus, presence or absence of the FT may have a clinical and evolutionary significance that is emphasized in our case reports.

This is an Open Access (OA) journal, and articles are distributed under the terms of the [Creative Commons Attribution-NonCommercial-ShareAlike 4.0 License](https://creativecommons.org/licenses/by-nc-sa/4.0/), which allows others to remix, tweak, and build upon the work non-commercially, as long as appropriate credit is given and the new creations are licensed under the identical terms.

For reprints contact: reprint@ipinnovative.com

1. Introduction

Fibularis tertius (FT) is highly variable muscle and may be absent. FT muscle marks the anterolateral entry during using the ankle arthroscopy procedures, used as a flap to cover faults in the foot soft tissue, tendon transfer and resection surgeries.¹ Fibularis tertius (FT) can also be called as the peroneus tertius.² FT muscle is a comparatively small underestimated evolutionary appearing unipennate muscle of anterior compartment of the leg which helps in dorsiflexion and eversion movements of foot. Fibularis tertius was primitively restricted to dorsum of foot as a part of muscle Extensor digitorum brevis, but due to functional insistence of bipedal gait and plantigrade foot, it has migrated upwards in to the leg.³ The musculature of the human lower limb has considerably adapted, because of the special mode of progression. Few muscles even now are in the process of evolution, they are either disintegrating

like the plantaris of back of leg or are appearing like the fibularis tertius of anterior compartment of leg. Variations in the positioning of muscles, as regards of their mode of attachment and degree of subdivision are encountered very often.⁴ The FT may be used for tendon graft surgeries and pull of this muscle may be responsible for instigating strain on the fifth metatarsal bone which is bone of its insertion and account for all stress fractures in any individual. The absence of the FT may obscure a plastic surgeon and foot surgeon for performing graft operations.⁵

2. Case Report

While doing routine dissection for the MBBS students, we observed absence of fibularis tertius on the dorsum of the right foot of a embalmed male cadaver of middle age in the Department of Anatomy, Sri Guru Ram Das medical college, Amritsar. Other limb was also carefully observed and examined to look for the absence of FT muscle. No scar mark or any sign of injury was observed on the right

* Corresponding author.

E-mail address: poonamabrol1@gmail.com (P. Verma).

limb. The other muscles of the anterior compartment were present normally with their normal anatomical characters. The photographs of the dorsum of right foot were taken for genuine documentation of the case report. The absence of the fibularis tertius is a rare anomaly. In many cases, lacking of Fibularis tertius may be asymptomatic and may be incidentally found absent during normal routine dissection of cadavers

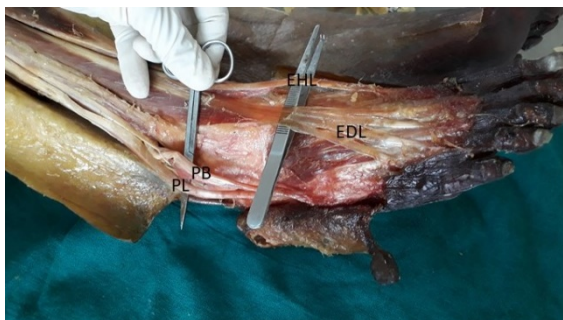


Fig. 1: Absence of Fibularis tertius in right foot (EHL-Extensor hallucis longus, EDL- Extensor digitorum longus, PL- Peroneus longus, PB- Peroneus brevis)

3. Discussion

With the adaptation to upright posture, the foot had to not only hold up the weight but also keep the balance of body, while walking and standing on bumpy surfaces. The FT muscle is absent in many primates with considerable dissimilarities in human beings.³ Fibularis tertius is highly variable in its appearance and muscle bulk, occasionally may be completely absent. It may be attached to the fourth metatarsal instead of fifth.⁶ It may be as bulky as the Extensor Digitorum Longus or even it may be lacking.⁷ Study on Caucasian population was done which concluded its nonappearance in 5-17% of cases. The clinical importance of the Fibularis tertius concerning prevention and treatment of ankle ligament injuries is less.⁸ This muscle may play a special proprioceptive role in detecting abrupt inversion and then contracting to guard the anterior tibiofibular ligament, one of the most commonly injured ligaments of our body.⁹ The insertion of the FT might occupied a major role in the creation of torsional stresses as noticed in Jones fractures and stress fractures.¹⁰ Presence or lacking of the FT have a clinical and evolutionary importance that is why this case report

has been presented. The absence of FT may misdirect the surgeons in performing graft and transplant operations. Thus, radiological imaging procedures must be made to approve the presence or absence of the FT before scheduling any manoeuvre in foot.

4. Source of Funding

None.

5. Conflict of Interest

The authors declare no conflict of interest.

References

1. Salema AH, Kaderb GA, Almallah AA, Husseinb HH, Badiac AA, Behbehani N, et al. Variations of peroneus tertius muscle in five Arab populations: A clinical study. *Transl Res Anat.* 2018;13:1–6.
2. Standring S, Borley NR, Collins P, Crossman AR, Gatzoulis MA, Healy JC, et al. *Gray's Anatomy: The Anatomical Basis of Clinical Practice.* 40th ed. London: Elsevier, Churchill Livingstone; 2008. p. 1418–9.
3. Joshi SD, Joshi SS, Athavale SA. Morphology of peroneus tertius muscle. *Clin Anat.* 2006;19(7):611–4.
4. Bhargava KN, Sanyal KP, Bhargava SN. Lateral musculature of the leg as seen in hundred Indian Cadavers. *Indian J Med Sci.* 1961;15(3):181–5.
5. Das S, Haji SF, Latiff A, Hlaing K, Ghafar AN, Othman F. Absence of the Fibularis tertius muscle: cadaveric study with clinical considerations. *Rom J Morphol Embryol.* 2009;50(3):509–11.
6. Standring S. *Gray's Anatomy: The Anatomical Basis of Clinical Practice.* 39th ed. London: Elsevier Churchill Livingstone; 2005. p. 1497.
7. Parsons SJ. *Morris' Human Anatomy, A complete systematic treatise.* 12th ed. New York: McGraw Hill Book Company; 1966. p. 570–2.
8. Witvrouw E, Borre KV, Willems TM, Huysmans J, Bross E, Declercq D. The significance of Peroneus Tertius muscle in ankle injuries; a prospective study. *Am J Sports Med.* 2006;34(7):1159–63.
9. Moore KL. *Clinical Oriented Anatomy.* 6th ed. India: Wolters Kluwer Pvt. Ltd; 2009. p. 589.
10. Vertullo CJ, Glisson RR, Nunley J. Torsional strains in the proximal fifth metatarsal: implications for Jones and stress fracture management. *Foot Ankle Int.* 2004;25(9):650–6.

Author biography

Poonam Verma, Professor  <https://orcid.org/0000-0003-0570-1765>

Girish Abrol, First Year Student

Cite this article: Verma P, Abrol G. Unilateral absence of fibularis tertius: A clinically and evolutionary salient variation. *Indian J Clin Anat Physiol* 2022;9(1):68-69.