



## Letter to Editor

## Practical considerations in the anaesthetic management of thoracolumbar scoliosis correction surgery in a child with hecht–beals syndrome

Madhanmohan Chandramohan<sup>1</sup>, Tuhin Mistry<sup>1,\*</sup>,  
Jagannathan Balavenkatasubramanian<sup>1</sup>, Vipin Kumar Goel<sup>1</sup>,  
Senthilkumar Balasubramanian<sup>1</sup>

<sup>1</sup>Dept. of Anaesthesiology,, Ganga Medical Centre & Hospitals Pvt. Ltd, Coimbatore, Tamil Nadu, India



## ARTICLE INFO

## Article history:

Received 28-10-2021

Accepted 10-12-2021

Available online 22-04-2022

This is an Open Access (OA) journal, and articles are distributed under the terms of the [Creative Commons Attribution-NonCommercial-ShareAlike 4.0 License](https://creativecommons.org/licenses/by-nc-sa/4.0/), which allows others to remix, tweak, and build upon the work non-commercially, as long as appropriate credit is given and the new creations are licensed under the identical terms.

For reprints contact: [reprint@ipinnovative.com](mailto:reprint@ipinnovative.com)

Dear Editor

Hecht-Beals syndrome (HBS) is a relatively rare (<1 in 10,000 people per year) autosomal dominant connective tissue disorder with arachnodactyly, dolichostenomelia, multiple flexion contractures, kyphoscoliosis, crumpled ears, and pseudocamptodactyly.<sup>1</sup> We report the perioperative management of an HBS child scheduled for scoliosis deformity correction. A consent was obtained from the parents for the publication of this letter.

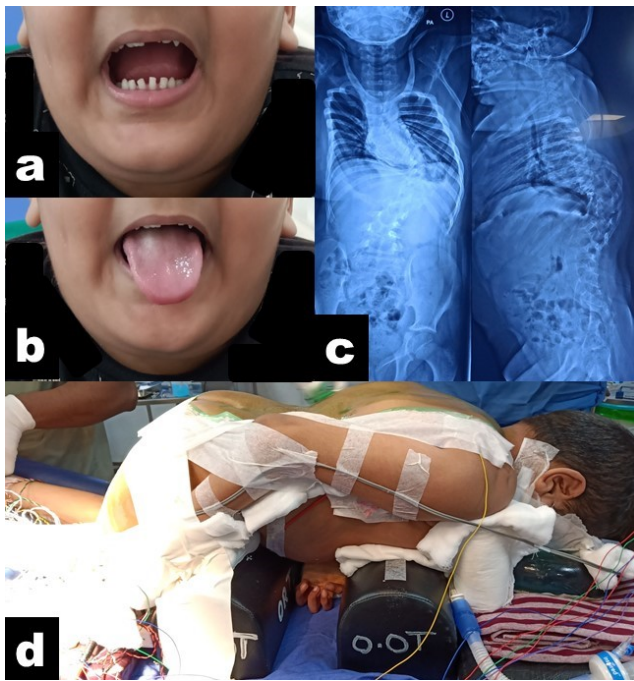
A 6-year-old, 31 kg boy presented with delayed developmental milestones and progressive back deformity. He had undergone multiple surgeries for fixed flexion deformities of limbs, ectopia lentis, and retinal detachment. He had limited mouth opening (inter incisor distance 2 cm), high arched palate, and short neck (Figure 1 a,b). Echocardiography disclosed situs solitus D-loop, bicuspid aortic valve, mild anterior and posterior mitral leaflets prolapse, and trivial mitral regurgitation. Radiological evaluation revealed thoracolumbar scoliosis involving T6 to L4 (central convexity towards the left at T10, Cobb's angle 58°), secondary curvature towards the right at L3, and crowding of ribs (Figure 1 c). The child was scheduled for T4-L4 posterior instrumented stabilization and fusion under general anesthesia (GA), and an informed written high-risk

consent was obtained from parents.

After adequate fasting, the child was shifted to the operating room, and standard monitors were attached. Intravenous (IV) fentanyl 2 µg/kg and glycopyrrolate 0.04 mg/kg were administered. The GA was induced with IV etomidate 0.3 mg/kg and titrated sevoflurane concentration. Videolaryngoscopy (C-MAC<sup>®</sup>, Karl Storz SE & Co. KG, Tuttlingen, Germany) was performed, and a cuffed reinforced endotracheal tube (internal diameter 5.5 mm) was inserted with the aid of gum elastic bougie (Fremantle Score: P2, size 2 Macintosh blade). An arterial cannula (22G) in the left ulnar artery, a triple lumen central venous catheter (7 Fr.) in the right femoral vein, a foley catheter (10 Fr.), nasopharyngeal temperature probe, electrodes for monitoring of bispectral index (BIS), somatosensory and motor evoked potentials (SSEP and MEP) were secured. Sevoflurane was discontinued, and 1% propofol infusion using a target-controlled infusion (TCI) pump (Marsh model, Alaris PK syringe pump, CareFusion, Hampshire, UK) was commenced. The target concentration was titrated between 2.2 to 2.8 µg/ml to maintain the BIS value between 40-50. The patient was turned prone on padded bolsters and silicone gel head ring (Figure 1 d). IV infusion of tranexamic acid (50 mg/hr) and dexmedetomidine (10 µg/hr) was started. Anesthesia was maintained with oxygen:air (1:1), propofol

\* Corresponding author.

E-mail address: [tm.tuhin87@gmail.com](mailto:tm.tuhin87@gmail.com) (T. Mistry).



**Fig. 1:** **a:** Limited mouth opening with maximal effort, **b:** after protrusion of tongue, **c:** Skiagram of the entire spine, **d:** Prone positioning following intubation

TCI, and controlled ventilation. IV paracetamol 15 mg/kg, ketorolac 0.5 mg/kg, magnesium sulfate 50 mg/kg, an hourly bolus of fentanyl 1  $\mu$ g/kg, and lignocaine 1.5 mg/kg were administered as a component of multimodal analgesia (MMA). The surgery lasted for six hours, and the child remained stable haemodynamically. The estimated blood loss was 500 ml, replaced by crystalloid and leucodepleted packed red blood cells. Wound infiltration was administered using 30 ml of 0.2% ropivacaine. Extubation was uneventful, and he was shifted to a high dependency unit. Postoperatively, MMA was maintained with IV paracetamol 15 mg/kg 6<sup>th</sup> hourly, ketorolac 0.5 mg 12<sup>th</sup> hourly, buprenorphine 5 mg transdermal patch, dexmedetomidine infusion, and an intermittent bolus dose of fentanyl. The rest of his postoperative period was uneventful, and he was discharged from the hospital on the eighth postoperative day.

Since its first description, the anaesthetic management of HBS or Dutch–Kentucky syndrome mainly revolves around airway management.<sup>1–4</sup> Preoperative cardiorespiratory assessment is of utmost importance to chalk out the management plan. Peripheral venous access may be difficult due to the presence of multiple contractures. In our patient, the radial artery was tortuous, identified by ultrasound, and resolved by ulnar artery cannulation. In reported cases, inhalation induction was chosen over IV agents to avoid sudden loss of airway patency.<sup>1–4</sup> However, inhalation agents, may irritate the airway. Hence, we used a combination of both to achieve acceptable intubating

conditions. Although fiberoptic intubation is considered the gold standard for managing difficult airway, we could intubate successfully using a C-MAC videolaryngoscope. Nasreen and Khalid also used videolaryngoscope, stylet, and external laryngeal manipulation to intubate a 2-month-old infant with HBS.<sup>2</sup> Careful placement of limbs during prone positioning is essential due to the presence of fixed flexion deformity. We placed the child's left hand in the gap between two bolsters due to the presence of contracture at the elbow (Figure 1 d). BIS monitoring helped us to maintain adequate depth, titrate TCI, and unclog neuromonitoring by avoiding a deep plane of anesthesia. Erector spinae plane block may be considered whenever feasible in pediatric scoliosis surgery.<sup>5</sup> Unfortunately, we had to bank upon opioid-based analgesia as ultrasound visualization of bony landmarks was difficult. HBS patients with thoracic cage deformity are prone to postoperative pulmonary complications, for which preoperative chest physiotherapy with breathing exercises should be started.

To conclude, HBS patients undergoing thoracolumbar scoliosis correction surgery require multidisciplinary team management. A thorough preoperative assessment, vigilant intraoperative monitoring, and adequate postoperative analgesia could result in a successful outcome in our patient.

#### Source of Funding

Nil.

#### Conflicts of Interest

There are no conflicts of interest.


#### Acknowledgment

We thank Prof. (Dr.) S. Rajasekaran, Chairman of the Department of Orthopaedic and Spine surgery, for sharing surgical and radiological information.

#### References


1. Kumar A, Chandran R, Khanna P, Bhalla AP. Successful difficult airway management in a child with Hecht-Beals syndrome. *Indian J Anaesth.* 2012;56(6):591–2.
2. Nasreen F, Khalid A. An infant with Beals- Hecht syndrome: An airway challenge for the anaesthesiologist. *Sri Lankan J Anaesthesiol.* 2020;28(2):150–2.
3. Vazquez-Colon CN, Lee AC. Open wide: Anesthetic management of a child with Hecht-Beals syndrome. *Saudi J Anaesth.* 2021;15(1):53–5.
4. Geva D, Ezri T, Szmuk P, Gelman-Kohan Z, Shklar BZ. Anaesthesia for Hecht Beals syndrome. *Paediatr Anaesth.* 1997;7(2):178–9.
5. Diwan S, Altinpulluk EY, Khurjekar K, Nair A, Dongre H, Turan A, et al. Bilateral erector spinae plane block for scoliosis surgery: Case series. *Rev Esp Anestesiol Reanim (Engl Ed).* 2020;67(3):153–8.


#### Author biography

**Madhanmohan Chandramohan,** Junior Consultant  
 <https://orcid.org/0000-0003-3163-5693>

**Tuhin Mistry**, Junior Consultant  <https://orcid.org/0000-0003-1904-4831>

**Senthilkumar Balasubramanian**, Junior Consultant  <https://orcid.org/0000-0002-2664-2525>

**Jagannathan Balavenkatasubramanian**, Senior Consultant  <https://orcid.org/0000-0003-2578-0376>

**Vipin Kumar Goel**, Junior Consultant  <https://orcid.org/0000-0002-1692-2013>

**Cite this article:** Chandramohan M, Mistry T, Balavenkatasubramanian J, Goel VK, Balasubramanian S. Practical considerations in the anaesthetic management of thoracolumbar scoliosis correction surgery in a child with hecht–beals syndrome. *Indian J Clin Anaesth* 2022;9(2):288-290.