



## Case Report

# Pulmonary embolism following reduction of traumatic anterior hip dislocation- A case report and review of literature

Amrutha Liz Paul<sup>1,\*</sup>, Ram Varaham<sup>1</sup>, Preethi<sup>2</sup>, V M Balasubramani<sup>1</sup>

<sup>1</sup>Dept. of Trauma Critical Care, Ganga Medical Centre & Hospitals Pvt Ltd, Coimbatore, Tamil Nadu, India

<sup>2</sup>Dept. of Anaesthesia, Ganga Medical Centre & Hospitals Pvt. Ltd, Coimbatore, Tamil Nadu, India



### ARTICLE INFO

#### Article history:

Received 17-03-2022

Accepted 05-04-2022

Available online 13-08-2022

#### Keywords:

Anterior hip dislocation

Pulmonary embolism

### ABSTRACT

Anterior hip dislocations are uncommon, but are associated with the risk of occlusion of major vessels of the limb. We report a case of traumatic anterior hip dislocation who had an on-table cardiac arrest following reduction of hip. It was due to pulmonary embolism, and delayed presentation increased the risk for the same. It was an unanticipated event for us and we wish for all the providers to be aware of this occurrence.

This is an Open Access (OA) journal, and articles are distributed under the terms of the [Creative Commons Attribution-NonCommercial-ShareAlike 4.0 License](https://creativecommons.org/licenses/by-nc-sa/4.0/), which allows others to remix, tweak, and build upon the work non-commercially, as long as appropriate credit is given and the new creations are licensed under the identical terms.

For reprints contact: [reprint@ipinnovative.com](mailto:reprint@ipinnovative.com)

## 1. Introduction

Lower limb fractures and surgeries are known high risk factors for the development of deep vein thrombosis and pulmonary embolism.<sup>1,2</sup> The occurrence of the same in hip dislocations is not well known. It is more common with anterior hip dislocation. However, the incidence of anterior hip dislocations itself is rare.<sup>3</sup> Very few case reports are available regarding the same. We report a case of an on-table cardiac arrest, secondary to pulmonary embolism, following reduction of anterior hip dislocation and its management.

## 2. Case Report

A 46-year-old female was transferred to our hospital with an alleged history of skid and fall from a two-wheeler. She developed pain in the left hip and inability to bear weight with the left lower limb following the accident. Initial assessment was done at a nearby hospital, and she was diagnosed with left hip dislocation. She presented to our Resuscitation and Emergency room six hours after the accident.

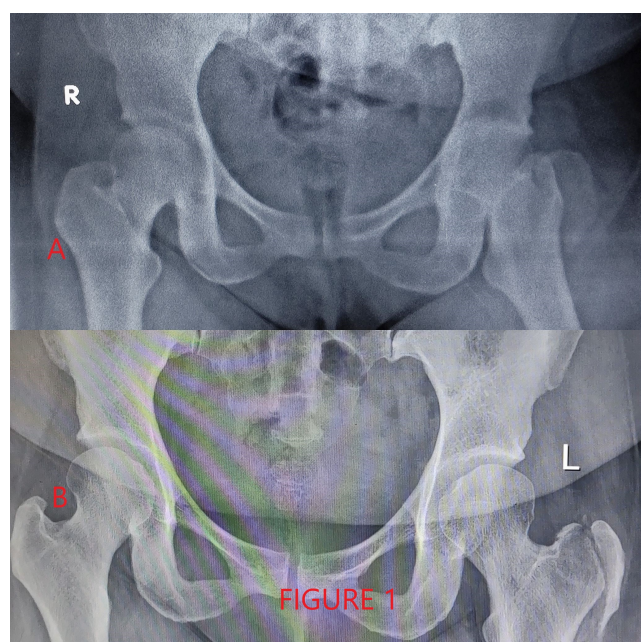
On presentation, she was conscious (GCS-15/15) with stable vitals (heart rate- 88/min, blood pressure- 120/80mmHg, respiratory rate- 20/min, oxygen saturation- 98% on room air). Her past medical history was unremarkable. Local examination revealed an abducted and externally rotated left hip. Active toe movements were present but distal pulses were not palpable. eFAST and Chest X-ray results were negative for acute injuries. Skeletal radiography confirmed left hip anterior dislocation with greater trochanter fracture (Figure 1 A). On admission laboratory parameters were unremarkable.

She was taken up for a closed reduction of hip within 30 minutes of presentation. Spinal anaesthesia was administered at L3-4 level using midline approach in lateral position. 25G Quincke needle was used and 0.5% Bupivacaine heavy 2ml with fentanyl 25ug was administered. Patient was made supine. She had one episode of hypotension after spinal anaesthesia, which was managed with a fluid bolus and 6mg intravenous Ephedrine. After achieving T10 level of anaesthesia, her hip was reduced in the first attempt (Figure 1 B). After 15 minutes of the procedure, the patient complained of giddiness, immediately followed by unconsciousness. This was also

\* Corresponding author.

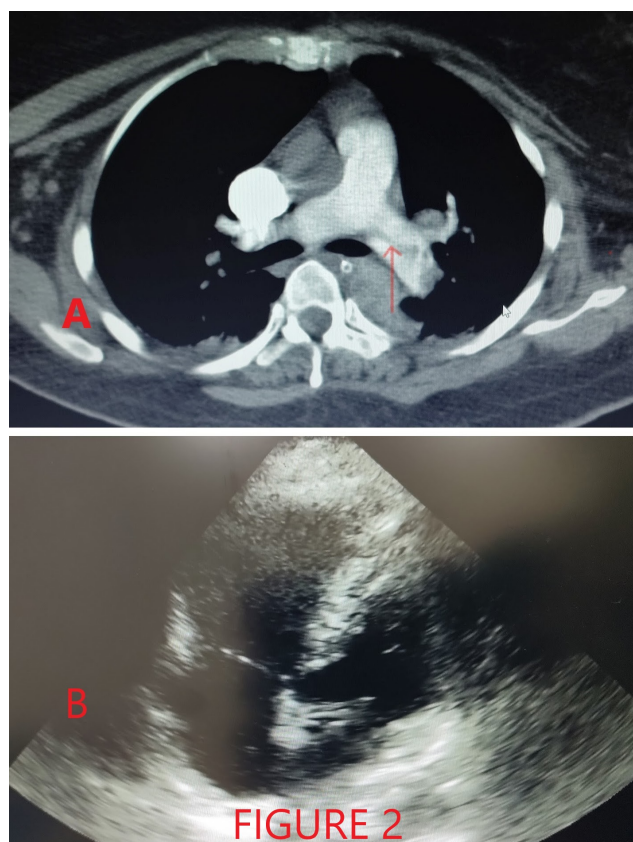
E-mail address: [amruthaliz@gmail.com](mailto:amruthaliz@gmail.com) (A. L. Paul).

associated with hypotension followed by bradycardia and cardiac arrest. Cardiopulmonary resuscitation was initiated as per ACLS protocol and ROSC was achieved after 1 cycle of CPR. She received one dose of intravenous Adrenaline (1mg) (arrest rhythm was PEA). Immediate post ROSC, bedside ECHO showed dilated right ventricle with poor right ventricular contractility. She was intubated and started on intravenous Adrenaline infusion and shifted to ICU for post cardiac arrest care.



**Fig. 1:** **A:** X-ray pelvis showing left hip anterior dislocation. **B:** X-ray pelvis post reduction (greater trochanter fracture can be seen)

All blood investigations were repeated which did not show any significant abnormality. Bedside transthoracic echocardiography (ECHO) revealed dilated right atrium, right ventricle with mild pulmonary artery hypertension and good left ventricular function (Figure 2 B). The ECG showed a right bundle branch block. Femoral vein compression test was negative. She was started on treatment dose of low molecular weight heparin (LMWH) keeping the possibility of pulmonary embolism. After initial stabilization, computed tomography pulmonary angiography (CTPA) was done which revealed bilateral upper and lower lobar, segmental pulmonary arterial thromboembolism with proximal extension in bilateral main pulmonary arteries causing partial luminal occlusion (Figure 2A). She was started on therapeutic doses of subcutaneous LMWH (Enoxaparin) at a dose of 1mg/kg (60mg twice daily), and was continued on other supportive intensive care treatment. During her ICU stay she had episodes of hemoptysis which was managed conservatively. It was probably due to pulmonary infarction.



**Fig. 2:** **A:** CT pulmonary angiogram showing thrombus in the left pulmonary trunk; **B:** Transthoracic echocardiography showing dilated right atrium and ventricle

Her inotropes were weaned and stopped in 48 hours. She was also weaned off mechanical ventilation in three days. No arterial or venous thrombus was detected in lower limb doppler. Serial bedside ECHO done showed reduction in right ventricle size and resolution of pulmonary artery hypertension. She was continued in ICU care for five days and then discharged to the ward. She continued on LMWH for 10 days and then switched to oral Apixaban. Greater trochanter fracture was managed conservatively. She was discharged on oral anticoagulation.

### 3. Discussion

Hip dislocation is an orthopedic emergency and should be performed within a 6-hour period to reduce the risk of avascular necrosis of the femoral head. It should be done as soon as possible if a neurovascular deficit is present. Posterior hip dislocations are common. The incidence of anterior hip dislocation is less than 11%.<sup>3,4</sup> Venous thromboembolism is a rare complication of hip dislocation. In anterior hip dislocations, due to the compression of major vessels there is a higher risk of thrombus formation.<sup>4-7</sup> Delayed reduction of hip leading to venous compression and

stasis, and thereby increasing the risk of DVT, is speculative but plausible.

In the literature there are only few case reports regarding the same. Two cases of venous obstruction following anterior hip dislocation was reported by Hampson et al. but there was coexisting arterial injury.<sup>5</sup> Our patient did not sustain any injury to the vasculature. Edibam et al. has reported a case of fatal paradoxical embolism following an attempt to reduce posterior hip dislocation after 14 hours of injury.<sup>6</sup> This patient had a history of oral contraceptive pill intake which is a risk factor for development of PE. Our patient did not have any predisposing factor for developing DVT.

Amendola et al. reported a case of pulmonary thromboembolism detected preoperatively in a patient with anterior hip dislocation which was neglected and later postoperatively received anticoagulation.<sup>4</sup> We did not do any preoperative venography for our patient. Retrospectively analyzing the absent peripheral pulse should have been considered as a warning sign of major vessel occlusion.

JD Dieterich has reported an interesting case in which a 90-year-old man with traumatic anterior hip dislocation had failed initial attempt of reduction under sedation and underwent a CT hip to rule out intra articular fragments. Compression of vein was noted and on evaluation was detected to have thrombus and preoperatively IVC filter was placed.<sup>8</sup>

The exact etiology of DVT in these cases are not known. A theory of endothelial damage due to high energy trauma, along with venous stasis due to occlusion of vessels by femoral head and trauma induced hypercoagulable state is speculated.<sup>4</sup>

We recommend a high index of caution in patients with anterior hip dislocation and also that providers be aware of this clinical entity. Always anticipate the possibility of pulmonary embolism and prepare accordingly. We also recommend ultrasound and CT contrast venography of leg and pelvic veins in patients with prolonged anterior dislocation and the absence of distal pulse. If any thrombus is detected, consider IVC filter and anticoagulation before hip reduction. This should be weighed against the perceived likelihood of bleeding from other associated injuries. If vein obstruction is seen in CT pelvis and clinical suspicion of pulmonary embolism is present (tachypnea, hypoxia), we strongly suggest a CTPA before reduction.<sup>9</sup>

#### 4. Source of Funding

None.

#### 5. Conflict of Interest

None.

#### References

1. Bělohávek J, Dytrych V, Linhart A. Pulmonary embolism, part I: Epidemiology, risk factors and risk stratification, pathophysiology, clinical presentation, diagnosis and nonthrombotic pulmonary embolism. *Exp Clin Cardiol*. 2013;18(2):129–38.
2. Kamekar DR, John MJ, Desai SC, Dsilva LC, Joglekar SJ. Arrive: A retrospective registry of Indian patients with venous thromboembolism. *Indian J Crit Care Med*. 2016;20(3):150–8.
3. Epstein HC. Traumatic dislocations of the hip. *Clin Orthop Relat Res*. 1973;(92):116–42.
4. Amendola L, Orlandi PE, Tigani D. Neglected pulmonary thromboembolism in a traumatic anterior hip dislocation: A case report. *J Clin Orthop Trauma*. 2019;10(1):197–200.
5. Hampson WG. Venous obstruction by anterior dislocation of the hip-joint. *Injury*. 1972;4(1):69–73.
6. Edibam C, Morgan DJ, Rao SV, Keren A, Deague J. Deep vein thrombosis and fatal paradoxical embolism after delayed reduction of a traumatic hip dislocation. *J Trauma*. 2008;64(4):1133–5.
7. Bonnemaïson MF, Henderson ED. Traumatic anterior dislocation of the hip with acute common femoral occlusion in a child. *J Bone Joint Surg Am*. 1968;50(4):753–6.
8. Dieterich JD, Benitez CL, Cheung ZB, Forsh DA. Anterior hip dislocation complicated by thrombus in the common femoral vein: A case report. *Clin Imaging*. 2021;73:48–52.
9. Khosla R. Diagnosing pulmonary embolism. *Indian J Crit Care Med*. 2006;10(2):105–11.

#### Author biography

**Amrutha Liz Paul**, Registrar  <https://orcid.org/0000-0002-5465-091X>

**Ram Varaham**, Consultant

**Preethi**, Junior Consultant

**V M Balasubramani**, HOD

**Cite this article:** Paul AL, Varaham R, Preethi, Balasubramani VM. Pulmonary embolism following reduction of traumatic anterior hip dislocation- A case report and review of literature. *Indian J Clin Anaesth* 2022;9(3):399-401.