



## Case Report

# Acute inflammatory demyelinating polyneuropathy following COVID-19 vaccination: screening at vaccination, a potential precaution

Michell Gulabani<sup>1</sup>, Richa Chauhan<sup>1,\*</sup>, Nimisha T<sup>1</sup>, Ashok Kumar Saxena<sup>1</sup>

<sup>1</sup>Dept. of Anaesthesia and Critical Care, University College of Medical Sciences/ Guru Teg Bahadur Hospital, Dilshad Garden, Delhi, India



### ARTICLE INFO

#### Article history:

Received 03-04-2022

Accepted 03-05-2022

Available online 13-08-2022

#### Keywords:

COVID-19

Vaccination

Guillain-Barre syndrome

Screening

### ABSTRACT

**Background:** Several vaccines have been developed and employed under emergency use authorization to keep COVID-19 in check. A safe administration of vaccination ruling out any underlying health conditions that may be a contraindication to vaccination is paramount to diminish various adverse effects secondary to vaccination.

**Case:** Presenting the case of a 34-year-old female with pre-existing, incompletely resolved lower respiratory tract infection when inoculated with the first dose of Covishield vaccine, 5 days after which she developed rapidly ascending weakness of lower limbs causing respiratory failure. A provisional diagnosis of Acute Inflammatory Demyelinating Polyradiculoneuropathy, Guillain Barre Syndrome variant was established based on clinical presentation, physical examination, and response to intravenous Immunoglobulin therapy despite which she succumbed to the illness.

**Discussion:** Guillain Barre Syndrome may spike during outbreaks of infectious illnesses that trigger the disease with clinical features of acute onset, rapid course, symmetry in symptoms and signs, in the absence of central nervous system involvement being necessary to support its diagnosis. These were all fulfilled in the present case. The case in point was not screened with a pre-vaccination checklist in noncompliance to the product warning with the COVID vaccine, and the nature of the resulting interaction is subject to further research.

**Conclusion:** Adequately screen and optimize individuals for concurrent illness at inoculation to minimize adverse events. The benefits of COVID-19 vaccination continue to outweigh the potential risks associated.

This is an Open Access (OA) journal, and articles are distributed under the terms of the [Creative Commons Attribution-NonCommercial-ShareAlike 4.0 License](https://creativecommons.org/licenses/by-nc-sa/4.0/), which allows others to remix, tweak, and build upon the work non-commercially, as long as appropriate credit is given and the new creations are licensed under the identical terms.

For reprints contact: [reprint@ipinnovative.com](mailto:reprint@ipinnovative.com)

## 1. Introduction

Immunization is the key step in our fight against COVID-19. Various adverse effects of COVID-19 vaccinations are unfolding as the vaccination drive has picked up the pace. Multiple neurological complications have been reported with COVID-19 infection including Guillain-Barre Syndrome (GBS). Various COVID-19 vaccinations containing SARSCoV2 viral components are also being implicated.<sup>1</sup> A safe administration of vaccination ruling

out any underlying health conditions that may be a contraindication to vaccination is paramount to diminish adverse effects secondary to vaccination. There is a mention of a few cases in the literature of GBS following COVID-19 vaccination with our case being unique as the patient was vaccinated even in the presence of an underlying active pulmonary infection.

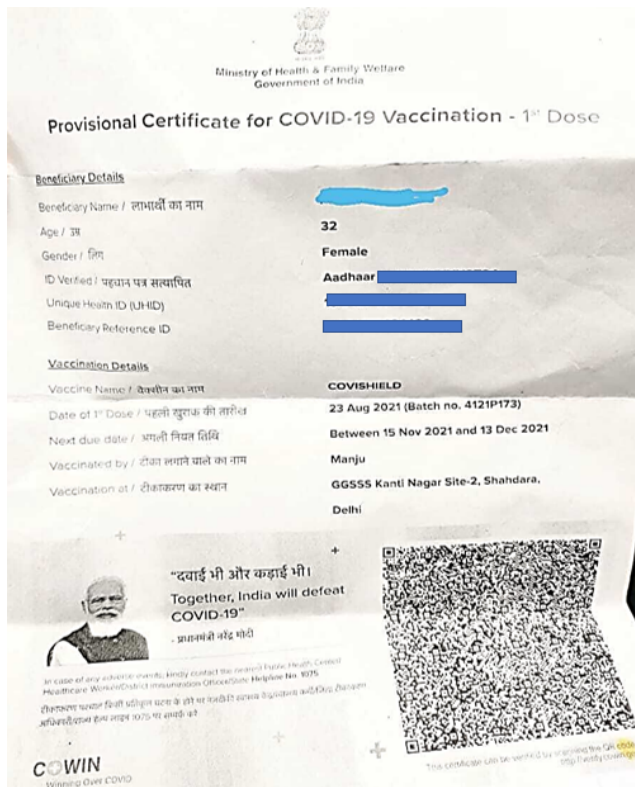
## 2. Case History

Presenting the case of a 34-year-old female with no known comorbidities admitted to our hospital nine days after

\* Corresponding author.

E-mail address: [drrichsilverdust@gmail.com](mailto:drrichsilverdust@gmail.com) (R. Chauhan).

getting vaccinated with the first dose of Covishield vaccine (Figure 1).



**Fig. 1:** 1<sup>st</sup> dose administration of Covishield vaccine

She had symptoms of productive cough for 20 days prior, unevaluated, and incompletely recovered when getting vaccinated. Five days thereafter, she experienced sudden onset of weakness in both lower limbs, rapidly ascending to involve upper limbs and respiratory muscles.

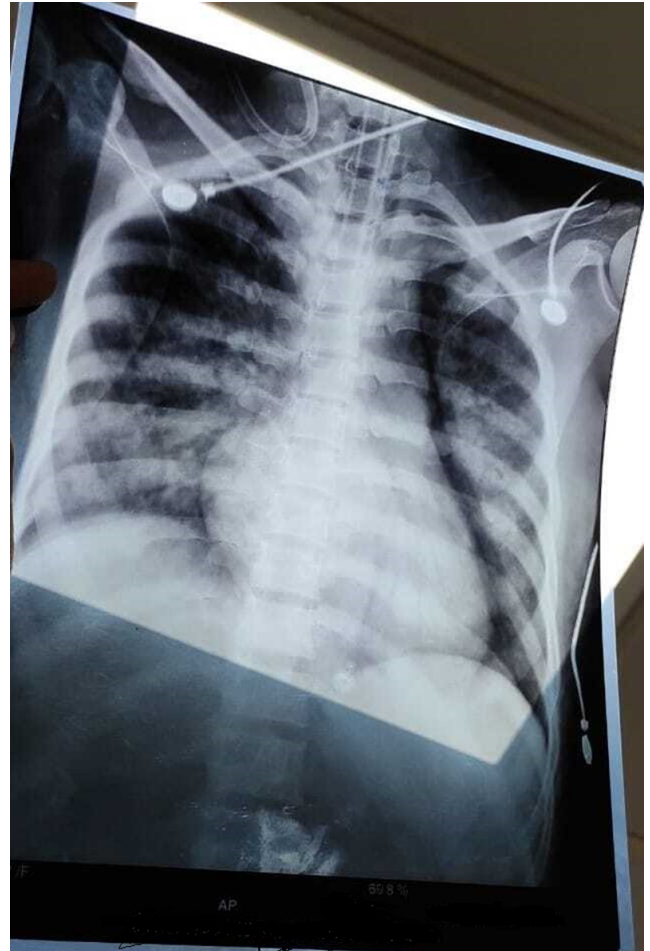
On presentation, she had altered sensorium with GCS 12/15, pupils reactive, blood pressure 110/70 mmHg, pulse rate 110 /min, oxygen saturation 60% on room air, respiratory rate 36/min. The patient was initiated on invasive mechanical ventilatory support, sensorium was corrected thereafter, suggesting its hypoxic/hypercapnic origin. Motor power symmetrically decreased in all 4 limbs, with lower limbs (right 0/5, 2 left 1/5) more than upper limbs(3/5). Deep tendon reflexes are absent in lower limbs, with reduced tone in all 4 limbs. No meningeal signs were present. Bladder and bowel function were normal. Sensory, autonomic nervous systems examination could not be done since the patient was on mechanical ventilation. Bilateral basal coarse crepts were auscultated in the chest.

Routine hematological and biochemistry investigations were within normal limits. C-Reactive Protein (80mg/l), D-dimer(2.18mcg/ml), Serum ferritin (446 ng/ml), Interleukin-6(25 pg/ml) were all raised. COVID-19 RTPCR was negative. Cerebrospinal fluid (CSF) analysis showed

total leucocyte count (TLC) 65/mm<sup>3</sup>, protein 42 mg%, sugar 85mg%, negative for Adenosine deaminase (1.6U/L), culture sterile.

The frequently presenting variant of GBS, AIDP was considered the provisional diagnosis based on clinical presentation, and physical examination.

Bilateral symmetrically diffuse reticular opacities were noted on the chest X-ray (Figure 2).



**Fig. 2:** Antero-posterior chest X-ray showing bilateral diffuse reticular opacities suggestive of ARDS

Immunoglobulin therapy given at a dose of 0.4g/Kg/day intravenously for 5 days on suspicion of GBS, resulting in motor power improvement.

Unfortunately, her respiratory illness culminated in Acute Respiratory Distress Syndrome (ARDS).

Nerve conduction study required the patient to be shifted to another facility, not permitted by her high ventilator dependence (Table 1).

Treatment included steroids, anticoagulants, broad-spectrum antibiotics, and other supportive care. She developed septic shock with multiorgan dysfunction syndrome (MODS) requiring vasopressor support.

Her condition downward spiraled and she succumbed to her illness 20 days after hospital admission.

**Table 1:** Arterial blood gas on protective lung ventilation with settings, PRVC mode, TV= 260 ml, RR= 22, PEEP= 6, FiO<sub>2</sub>= 100.

Parameter	Value	Unit
pH	7.467	
PaCO <sub>2</sub>	44.7	mm Hg
PaO <sub>2</sub>	67.6	Mm Hg
S. Na <sup>+</sup>	145.2	mEq/L
S. k <sup>+</sup>	3.95	mEq/L
S. Cl <sup>+</sup>	108.8	mEq/L
S. HCO <sub>3</sub> <sup>-</sup>	32.6	mEq/L
BE	8.7	mMol/L
A-a DO <sub>2</sub> PO <sub>2</sub> / FiO <sub>2</sub>	578.5 67.6	mm Hg

PaO<sub>2</sub>-FiO<sub>2</sub> ratio is 67.6 indicating severe ARDS. A-a DO<sub>2</sub> is raised to 578.5 mm Hg. Metabolic alkalosis with respiratory compensation seen

### 3. Discussion

There is an ongoing worldwide mass vaccination drive to put a check on the wrath of the COVID-19 virus, with a booster dose introduced for patients at a high risk of the infection.<sup>2</sup> However, the clinical trials on these vaccines were underpowered to detect rare adverse effects. Therefore, the identification of such rare adverse events is taking precedence.<sup>1</sup>

A new addition to the list is GBS, GBS results from an infection causing a neuro-immunological trigger affecting the peripheral nerves and nerve roots. Molecular mimicry as a mechanism of autoimmune disorder is known to play an important role.<sup>3</sup>

The etiopathogenesis of GBS causing nerve inflammation, resulting in pain, numbness, and muscle weakness that may progress to paralysis, is yet not completely understood. Mechanical ventilation is required in 20% of the patients owing to respiratory failure.<sup>4</sup> Hemodynamic instability and cardiac arrhythmias can occur in 20% of the patients due to involvement of the autonomic nervous system.<sup>3</sup>

Outbreaks of infectious illnesses that trigger the disease can in turn result in a GBS outbreak which already has an established association with the influenza virus, interestingly influenza vaccine too.<sup>5</sup> SARS-CoV-2 creates an immune-mediated process.<sup>5</sup> Potential molecular mimicry between GBS and SARS-CoV-2 infection was studied,<sup>6</sup> though the strength of linkage is still unclear. This can potentially trigger GBS possibly by the production of autoantibodies against myelin.

This raises caution regarding the GBS spike in parallel to the ongoing COVID-19 pandemic and mass vaccination.<sup>5</sup>

Several cases have been reported worldwide with Oxford–AstraZeneca COVID-19 vaccine using

adenovirus ChAdOx1 as vector. Adenovirus vector may be another source of autoimmunity. European Medicines Agency (EMA) added a warning in the product information to alert healthcare professionals and people taking the vaccine of this potential risk in view of the seriousness of this condition to facilitate early diagnosis, supportive care, and treatment. It further advises the general public to seek immediate medical attention on suspicion of developing GBS symptoms.<sup>3</sup>

EMA's safety committee, Pharmacovigilance Risk Assessment Committee (PRAC), considered a potential causal relationship between COVID-19 Vaccine Janssen and GBS.<sup>5</sup> PRAC continues to closely monitor the

issue. A total of 833 cases of GBS were reported with Vaxzevria worldwide by 31 July 2021, while 592 million doses of Vaxzevria had been given worldwide by 25 July 2021.<sup>4</sup>

Cases have also been reported with Janssen vaccine using recombinant Ad26 vector, encoding SARS-CoV-2 spike protein.<sup>6</sup>

Also reported with other formulations such as Moderna, Pfizer–BioNTech vaccine which use modRNA encoding SARS-CoV-2 spike protein.<sup>7</sup>

The World Health Organisation's Global Advisory Committee on Vaccine safety also issued warnings and recommendations to increase awareness in this regard. Though, it advocates that the potential benefits of COVID-19 vaccines outweigh the potential risk of GBS.<sup>8</sup>

Cases of GBS post-vaccination with Covishield are being reported in India as well. Maramattom et al<sup>9</sup> has reported 7 GBS cases in Kerala. Suri V et al in Delhi have also reported a case of acute inflammatory demyelinating polyneuropathy after COVID-19 infection and subsequent ChAdOx1nCoV-19 vaccination which is marketed as Covishield vaccine in India.<sup>10</sup>

A retrospective analysis by Jee-Eun Kim et al.<sup>11</sup> in Korea revealed 13 patients with GBS post- COVID-19 vaccination with AstraZeneca vaccine being administered in 8, and Pfizer-BioNTech vaccine in 5 patients.

These cases had a similar presentation barring a pre-existing upper respiratory infection at vaccination in our patient.

In counterweight, a case series by Lunn et al,<sup>12</sup> Shapiro et al<sup>13</sup> concluded the absence of an association in this regard.

Diagnosis of GBS can be made convoluted by variable clinical manifestation and disease progression, a wide differential diagnosis, and the absence of highly sensitive and specific diagnostic biomarkers.

Leonhard SE et al<sup>3</sup> have developed a universally applicable guideline to direct diagnosis and management of GBS, which is based on existing literature and expert consensus. It has a ten-step structure to simplify its clinical use. Features required for diagnosis are progressive bilateral

weakness of upper and lower limbs and absence of tendon reflexes, which were both fulfilled in this patient.

Clinical features of acute onset of disease with the rapid course, symmetry in symptoms and signs, in the absence of CNS involvement are necessary to strongly support the diagnosis.<sup>3</sup> These were all fulfilled for the case in point. Without accurate biomarkers, the clinical features will remain the hallmark for the diagnosis of Guillain-Barré syndrome. The patient typically reached maximum disability within 2 weeks, also relative symmetry of signs and symptoms strongly supports the diagnosis. Also, limb motor power had responded to IV immunoglobulin therapy.

No history of neurological disease or spinal trauma is present. Though her CSF analysis showed raised TLC count, meningeal signs were negative and CSF culture came out sterile.

The demyelinating neurological process could be attributed to the vaccination since it started soon thereafter. Or though less likely, to the respiratory infection when getting vaccinated since the neurological symptoms started more than 3 weeks after the respiratory infection, which is not in concordance with the guideline stating that the mean onset time after an antecedent trigger event is 1-3 weeks.<sup>7</sup>

Additionally, the temporal association with the vaccination could be casual without being causal.

Moreover, Food and Drug Administration has pointed out that unapproved vaccines that may be contaminated, or counterfeit are being released for consumer use and should be protected against.<sup>7</sup>

Complications of GBS can cause severe morbidity and death. Our patient developed hospital-acquired pneumonia which progressed to ARDS with MODS and finally succumbed to it.

A higher incidence of GBS is reported with COVID-19 infection than with COVID-19 vaccination. Therefore, the risk of GBS with SARS-CoV-2 may be higher than that for GBS associated with COVID-19 vaccinations.

People with active SARS-CoV-2 infection should hold over any COVID-19 vaccination at least till the patient has recovered from the acute illness and completed isolation.<sup>14</sup>

A pre-vaccination checklist prior to COVID-19 vaccination is to assist healthcare providers while conducting an informed consent and health assessment of a vaccine recipient.<sup>15</sup> It questions them to rule out any signs and symptoms of an underlying infection, amongst other questions to screen for additional precautions or contraindications to vaccination. Such a checklist specific to India has not been introduced and screening prior to covid vaccination is not carried out.

The case in point was not screened for underlying active infections during vaccination in noncompliance to the product warning with COVID vaccine,<sup>16</sup> and the nature of the resulting interaction is subject to further research.

#### 4. Conclusion

It is advisable to adequately screen and optimize individuals for concurrent illness at inoculation to minimize adverse events. The risk-benefit ratio of COVID-19 vaccination continues to be favourable. Nevertheless, awareness is necessitated amongst healthcare professionals and the public in regard to GBS as a potential risk.

#### 5. Source of Funding

None.

#### 6. Conflict of Interest

None.

#### References

1. Patone M, Handunnetthi L, Saatci D, Pan J, Katikireddi SV, Razvi S, et al. Neurological complications after first dose of COVID-19 vaccines and SARS-CoV-2 infection. *Nature Med.* 2021;27(12):2144–53.
2. Gupta L. Waning immunity and COVID-19 vaccines: What's next? *Indian J Clin Anaesth.* 2021;8(Special Issue):1–2.
3. Leonhard SE, Mandarakas MR, Gondim FA, Bateman K, Ferreira ML, Cornblath DR, et al. Diagnosis and management of Guillain-Barré syndrome in ten steps. *Nature Rev Neurol.* 2019;15(11):671–83.
4. Franchini M, Liumbruno GM, Pezzo M. COVID-19 Vaccine associated Immune Thrombosis and Thrombocytopenia (VITT): diagnostic and therapeutic recommendations for a new syndrome. *Eur J Haematol.* 2021;107(2):173–80.
5. Leung C. Guillain-Barre syndrome should be monitored upon mass vaccination against SARS-CoV-2. *Hum Vaccin Immunother.* 2021;17(9):2957–8.
6. Song H, Fan G, Zhao S, Li H, Huang Q, He D. Forecast of the COVID-19 trend in India: A simple modelling approach. *Math Biosci Eng.* 2021;18(6):9775–86.
7. Information for healthcare professionals on Guillain-Barré Syndrome (GBS) following COVID-19 vaccination - GOV.UK. (n.d.). Available from: <https://www.gov.uk/government/publications/covid-19-vaccination-guillain-barre-syndrome-information-for-healthcare-professionals/information-for-healthcare-professionals-on-guillain-barre-syndrome-gbs-following-covid-19-vaccination>.
8. Statement of the WHO Global Advisory Committee on Vaccine Safety (GACVS) COVID-19 subcommittee on reports of Guillain-Barré Syndrome (GBS) following adenovirus vector COVID-19 vaccines. Available from: <https://www.who.int/news/item/26-07-2021-statement-of-the-who-gacvs-covid-19-subcommittee-on-gbs>.
9. Maramattom BV, Krishnan P, Paul R, Padmanabhan S, Nampoothiri CV, Syed AA, et al. Guillain-Barré Syndrome following ChAdOx1-S/nCoV-19 Vaccine. *Ann Neurol.* 2021;90(2):312–4.
10. Suri V, Pandey S, Singh J, Jena A. Acute-onset chronic inflammatory demyelinating polyneuropathy after COVID-19 infection and subsequent ChAdOx1 nCoV-19 vaccination. *BMJ Case Rep.* 2021;14(10):e245816.
11. Kim JE, Min YG, Shin JY, Kwon YN, Bae JS, Sung JJ, et al. Guillain-Barré Syndrome and Variants Following COVID-19 Vaccination: Report of 13 Cases. *Front Neurol.* 2022;12:820723. doi:10.3389/fneur.2021.820723.
12. Lunn MP, Cornblath DR, Jacobs BC, Querol L, Doorn PAV, Hughes RA, et al. COVID-19 vaccine and Guillain-Barré syndrome: let's not leap to associations. *Brain.* 2021;144(2):357–60.
13. David SS, Potasman I, Rahamim-Cohen D. Rate of recurrent guillain-barré syndrome after mRNA COVID-19 vaccine BNT162b2. *JAMA Neurol.* 2021;78(11):1409–11.

14. Use of COVID-19 Vaccines in the United States. CDC. Available from: <https://www.cdc.gov/vaccines/covid-19/clinical-considerations/covid-19-vaccines-us.html>.
15. Prevacination Checklist for COVID-19 Vaccines. CDC; 2022. Available from: <https://www.cdc.gov/vaccines/covid-19/downloads/pre-vaccination-guidelines.pdf>.
16. COVID-19 Vaccine AstraZeneca. Product Information as approved by the CHMP on 29 January 2021, pending endorsement by the European Commission; 2021. Available from: [https://www.ema.europa.eu/en/documents/product-information/covid-19-vaccine-astrazeneca-product-information-approved-chmp-29-january-2021-pending-endorsement\\_en.pdf](https://www.ema.europa.eu/en/documents/product-information/covid-19-vaccine-astrazeneca-product-information-approved-chmp-29-january-2021-pending-endorsement_en.pdf).

**Richa Chauhan**, Assistant Professor  <https://orcid.org/0000-0002-0007-7396>

**Nimisha T**, PG Student

**Ashok Kumar Saxena**, Director Professor

**Cite this article:** Gulabani M, Chauhan R, Nimisha T, Saxena AK. Acute inflammatory demyelinating polyneuropathy following COVID-19 vaccination: screening at vaccination, a potential precaution. *Indian J Clin Anaesth* 2022;9(3):389-393.

## Author biography

**Michell Gulabani**, Assistant Professor