

Content available at: <https://www.ipinnovative.com/open-access-journals>

Indian Journal of Clinical Anaesthesia

Journal homepage: www.ijca.in

Case Report

Airway management of huge thyroid swelling having tracheal deviation: Challenges faced

Vijay Harischandra Patil^{1,*}, Kadappa Shivappa Huddar¹, Wasudeo S Barsagade¹, Anusha Uchila Rao¹¹Dept. of Anaesthesiology, Government Medical College and Hospital, Nagpur, Maharashtra, India

ARTICLE INFO

Article history:

Received 08-07-2022

Accepted 07-09-2022

Available online 15-11-2022

Keywords:

Thyroid swelling

Tracheal deviation

Difficult airway

Awake fiberoptic intubation

ABSTRACT

Introduction: Airway management in huge goiters present with challenges among anesthesiologists worldwide. Usually thyroid swelling presents with retrosternal extension, tracheal compression poses certain airway challenges. In our case there was no retrosternal extension or tracheal compression but tracheal deviation was present which make airway management difficult.

Case Report: 55yr old male pt, weight 60 kg, moderately built, came with chief complaints of gradually increasing swelling in front of neck since 3 years. He was k/c/o systemic hypertension on regular treatment taking tab. amlodipine 5mg OD. He was having no change in voice, no other systemic illness. He was evaluated for left sided huge goitre having neck swelling of size 14 cm × 15 cm × 10 cm. The mass was extending from lower jaw to below sternal notch, get below the swelling was possible. Xray neck AP and lateral view revealed tracheal deviation to right by the mass, this patient was posted for the hemithyroidectomy considering difficult airway plan of anaesthesia was awake fiberoptic intubation (under topical anaesthesia and sedation). In this case because of tracheal deviation to right the glottic structures were distorted, view to vocal cords was obscured by left arytenoid making the airway management difficult.

Discussion: In general the difficulty of tracheal intubation in cases with thyroid disease is affected by compression or deviation of the trachea, the position and hardness of the tumour. Generally recommended techniques for securing airway in such patients are 1. Awake fiberoptic intubation 2. Awake direct laryngoscopy aided intubation 3. Inhalational induction.

Conclusion: Awake fiberoptic intubation using local anaesthesia - sedation technique is a suitable option in selected group of patients having possibility of airway obstruction.

This is an Open Access (OA) journal, and articles are distributed under the terms of the [Creative Commons Attribution-NonCommercial-ShareAlike 4.0 License](https://creativecommons.org/licenses/by-nc-sa/4.0/), which allows others to remix, tweak, and build upon the work non-commercially, as long as appropriate credit is given and the new creations are licensed under the identical terms.

For reprints contact: reprint@ipinnovative.com

1. Introduction

Thyroidectomy is one of the commonest endocrine surgical procedure being carried out throughout the world.^{1,2} The major problems in thyroid surgeries for anaesthesiologists are potential difficult airway, especially in cases of retrosternal goitre, and an enlarged thyroid gland compressing over the trachea for a prolonged duration.^{3,4} But many times tracheal deviation due to thyroid mass may

also cause airway management difficult which is not being reported in literature. Available techniques for securing airway in such patients include awake fiberoptic intubation, awake direct laryngoscopy -aided intubation, and induction with inhalational agents. Hence, present article is an attempt to review challenges faced while airway management in a case of huge thyroid swelling having tracheal deviation.

* Corresponding author.

E-mail address: vjdhoran@gmail.com (V. H. Patil).

2. Case Report

55 year old male patient, weight 60 kg, came with chief complaints of gradually increasing swelling in front of neck since 3 years. He was k/c/o systemic hypertension on regular treatment taking tab. amlodipine 5mg OD. He was having no change in voice, no other systemic illness. He came for preoperative evaluation for left sided huge goitre to be posted for hemithyroidectomy. The mass was extending from lower jaw to below sternal notch, get below the swelling was possible. General examination reveal patient conscious, oriented, moderately built, BMI – 23kg/m³, pulse rate – 72/min, regular, good volume, blood pressure - 130/80mm Hg in right arm supine position, there was no pallor, cyanosis, clubbing or icterus. Systemic examination was found to be within normal limits. Neck examination reveal large cystic thyroid swelling arising from left lobe of size 14 cm × 15 cm × 10 cm, moves with deglutition, pushing trachea to extreme right side (Figure 1).

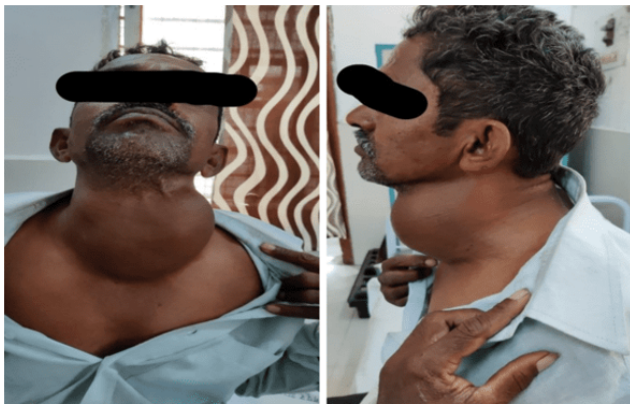

Fig. 1:

Airway examination was done for assessment of neck movements in all planes, any protruding incisors, protruding or retrognathic mandible and Mallampati grading, airway examination findings were normal except tracheal deviation to right noted on inspection and palpation. Complete blood count, kidney function tests, liver function tests, serum electrolytes, thyroid function test and rest other blood investigations were normal. ECG, chest X-ray, 2D echocardiography findings were normal. X-ray neck AP and lateral view revealed extreme tracheal deviation to right by the thyroid mass (Figure 2). CT scan of the chest & neck reveal, a well-defined cystic mass having size 14 cm × 15 cm × 10 cm arising from the arising from the left lobe of thyroid (Figure 3).

Indirect laryngoscopy was reported to be having distortion of glottic structure, left arytenoids obscuring view of vocal cord visualisation. This patient was posted for the hemithyroidectomy, in this case because of tracheal deviation to right the glottic structures were distorted and view to vocal cords was obscured by left arytenoid making

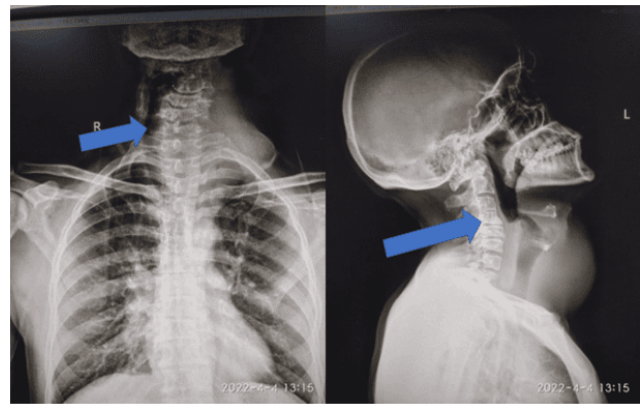


Fig. 2:

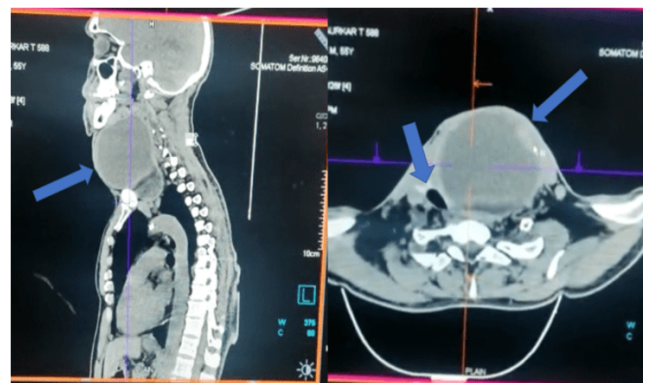


Fig. 3:

the airway management difficult. Hence after considering difficult airway our plan of anaesthesia was awake fiberoptic intubation under topical anaesthesia and sedation. Difficult airway management cart with C-Mac videolaryngoscope and jet ventilation was kept ready. Patient was kept fasting for 6 hours for solids and 2 hours for water before OT. Anti-hypertensive medication was continued till morning of surgery, tab. Pantoprazole 40 mg was given with a small sip of water on night before and morning of surgery. No preoperative sedation was prescribed to the patient in preoperative room. After checking all prerequisites like baseline investigations, written informed consent and NBM status the patient shifted to the OT. Standard monitors like ECG, pulse oximeter, and NIBP were attached and the baseline vitals were recorded. Wide bore 18 G IV cannulae secured in both upper limb. Inj. glycopyrrolate 0.2 mg intramuscular was administered. Xylometazoline was instilled in both the nostrils for vasoconstriction of nasal passage to facilitate passage of fiberoptic bronchoscope without mucosal injury. The patient's airway was anesthetized by application of lignocaine 2% jelly in the nostrils, 4 ml of lignocaine 4% nebulization, and lignocaine spray (10%). Oxygen was administered via nasal

prongs at a rate of 5 L/min, patient was administered 1 mg midazolam and 60 mcg fentanyl IV to allay anxiety and for mild sedation. Fiberoptic bronchoscope was loaded with a 6.5 mm flexometallic endotracheal tube. After explaining to the patient, the bronchoscope was inserted through one of the nostrils and advanced towards laryngeal inlet. Patient was instructed to take deep breaths to facilitate identification of the airway. FOB could not be negotiated easily through the vocal cords because of distortion glottic structures and extreme angulation of glottic opening. After facing difficulty rotation and manipulation by certain degree we could pass FOB, but further passage of endotracheal tube was difficult (Figure 4). Different maneuvers tried to negotiate endotracheal tube like gentle push, rotation, guided by videolaryngoscopic vision with magill's forceps, but all attempts to pass the endotracheal tube beyond vocal cords failed. Finally fiberoptic bronchoscope was loaded with a 6.0 mm flexometallic endotracheal tube, again same difficulty was faced due to extreme angulation but after little manipulation and rotation we could pass the endotracheal tube under videolaryngoscopic vision with magill's forceps (Figure 5). Once endotracheal tube was passed beyond the vocal cords confirmation of bilateral air entry was done by auscultation and ETCO₂ followed by fixation of endotracheal tube with tape.

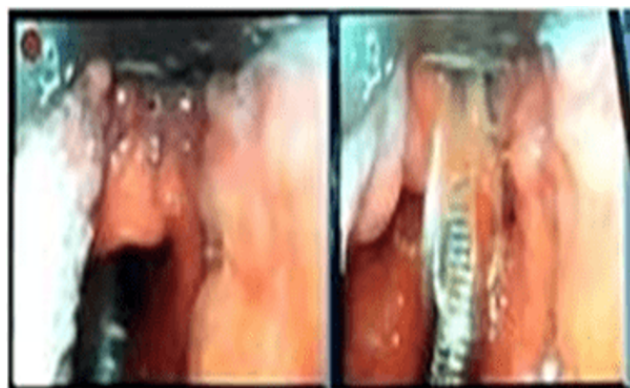


Fig. 4:

Inj. Propofol 100 mg IV slowly given manual ventilation confirmed and inj. Vecuronium 6mg IV stat given. For maintenance of anaesthesia O₂:N₂O used in 50:50 combination, inj. Vecuronium as muscle relaxant and sevoflurane as inhalational agent. The patient remained hemodynamically stable throughout the procedure, thyroid mass removed successfully (Figure 6 a). At the end of the procedure, leak test was done, keeping everything ready for reintubation reversal was given and patient extubated. After extubation, patient shifted to recovery room for observation. Postoperative course of the patient was smooth on 7th postoperative day patient was discharged to home (Figure 6 b).

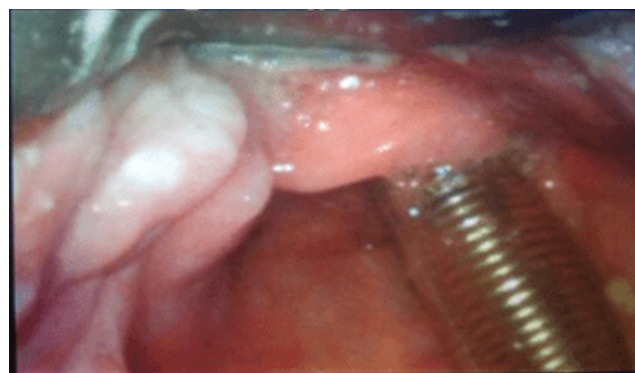

Fig. 5:

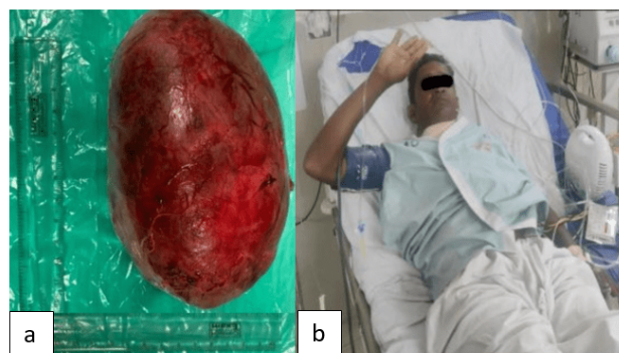

Fig. 6:

3. Discussion

Difficulty in intubation may be caused by an enlarged thyroid gland producing tracheal deviation, compression, or both.⁵ Cook et al. also supports this view and suggests that patient factors, physician expertise, and availability of resources may alter or modify airway management techniques. Malhotra and Sodhi have reported a strategy for airway management of thyroid patients, the strategy included the following options: Inhalation induction with sevoflurane, awake FOI, tracheotomy or ventilation through a rigid bronchoscope. Due to the airway problems encountered with thyroid disease, thyroidectomy under local anaesthesia was advocated by some anaesthesiologists, however, a patient with huge thyroid causing compromised airway is a major limiting factor for this technique too. Use of cardiopulmonary bypass for maintaining tissue oxygenation has also been described in cases of difficult airway with huge, compressive thyroid masses where airway maintenance was difficult. In our case after considering difficult airway our plan of anaesthesia was awake fiberoptic intubation under topical anaesthesia and sedation. With difficulty we could intubate patient using fiberoptic bronchoscope, intraoperative course was uneventful, while postoperatively patient extubated and shifted to recovery room. Patient was discharged home on

7th postoperative day.

4. Conclusion

Amongst the various options available awake fiberoptic intubation using local anaesthesia-sedation technique is a suitable option in selected group of patients having tracheal deviation due to large thyroid swelling.

5. Source of Funding

None.


6. Conflict of Interest

None.

References

1. Dionigi G, Dionigi R, Bartalena L, Tanda ML, Piantanida E, Castano P, et al. Current indications for thyroidectomy. *Minerva Chir.* 2007;62(5):359–72.
2. Agarwal G, Aggarwal V. Is total thyroidectomy the surgical procedure of choice for benign multinodular goiter? An evidence-based review. *World J Surg.* 2008;32(7):1313–24.
3. White ML, Doherty GM, Gauger PG. Evidence-based surgical management of substernal goiter. *World J Surg.* 2008;32(7):1285–300.
4. Bouaggad A, Nejmi SE, Boudarka MA, Abbassi O. Prediction of difficult tracheal intubation in thyroid surgery. *Anesth Analg.* 2004;99(2):603–6.
5. Spanknebel K, Chabor JA, Digiorgi M, Cheung K, Lee S, Allendorf J, et al. Thyroidectomy using local anesthesia: A report of 1,025 cases over 16 years. *J Am Coll Surg.* 2005;201(3):375–85.

Author biography

Vijay Harischandra Patil, Assistant Professor  <https://orcid.org/0000-0002-6198-2912>

Kadappa Shivappa Huddar, Junior Resident

Wasudeo S Barsagade, Professor

Anusha Uchila Rao, Junior Resident

Cite this article: Patil VH, Huddar KS, Barsagade WS, Rao AU. Airway management of huge thyroid swelling having tracheal deviation: Challenges faced. *Indian J Clin Anaesth* 2022;9(4):514-517.