

Content available at: <https://www.ipinnovative.com/open-access-journals>

Indian Journal of Clinical Anaesthesia

Journal homepage: www.ijca.in**Case Report****Succinylcholine induced Masseter spasm in a young male with frontal sinus abscess**Shilpa Jagdish Loya^{1,*}, Ashik Sreekumar¹, Sanhita Kulkarni¹¹MGM Medical College, Aurangabad, Maharashtra, India**ARTICLE INFO***Article history:*

Received 17-05-2022

Accepted 22-08-2022

Available online 15-11-2022

Keywords:

Anesthesia

Restricted mouth opening

Succinylcholine

Masseter spasm

Difficult intubation

FESS

ABSTRACT

We report a case of frontal sinus abscess posted for FESS, a chronic ghutka chewer with MPC IV and restricted mouth opening. Following induction with propofol and succinylcholine we noticed lockjaw when intubation was attempted, he was ventilated and anesthesia was deepened using propofol and dexmedetomidine, after a few minutes the masseter spasm had improved and miller's blade was used for endo tracheal intubation & the procedure was uneventful.

This is an Open Access (OA) journal, and articles are distributed under the terms of the [Creative Commons Attribution-NonCommercial-ShareAlike 4.0 License](https://creativecommons.org/licenses/by-nc-sa/4.0/), which allows others to remix, tweak, and build upon the work non-commercially, as long as appropriate credit is given and the new creations are licensed under the identical terms.

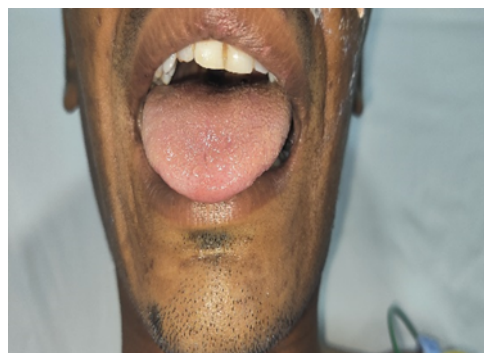For reprints contact: reprint@ipinnovative.com**1. Introduction**

Succinylcholine is one of the most frequently used depolarizing muscle relaxants for endotracheal intubation. It is favoured due to its rapid onset and short duration of action. Masseter muscle rigidity (MMR) is a rare adverse effect associated with the use of succinylcholine also called masseter muscle spasm or 'jaws of steel'. MMR is an early indicator of malignant hyperthermia (MH) according to various studies. The incidence of MMR in adults is unknown while it is found to be much more common in children (less than 1%).¹

2. Case Presentation

24/M diagnosed with frontal sinus abscess posted for FESS, he is a chronic Gutka chewer with MPC IV and 2 fingers mouth opening. 20 G iv was secured on both hands & patient was preoxygenated with 100% O₂ for 5 mins. Premedication was given with inj glycopyrrolate 0.2 mg + inj midazolam + 1.5 mg +inj fentanyl 100 mcg. Induced

with inj Propofol 120 mg iv + inj Loxicard 2cc and the patient was given bag mask ventilation with 100% o₂. Inj succinylcholine 100 mg IV was given after ventilation was continued for 60 seconds and laryngoscopy was attempted but was abandoned as the patient went into masseter spasm.

**Fig. 1:** Photo of patient showing restricted mouth opening.

Inj propofol 40 mg was given to relieve the masseter spasm but there was no mouth opening. After discussing with senior faculty tracheostomy consent was taken &

* Corresponding author.

E-mail address: jagdishshilpa@gmail.com (S. J. Loya).

tracheostomy set was kept ready. Trans tracheal injection with 2cc of 4% lignocaine was also given in preparation for the same. The plane of anesthesia was deepened with a bolus dose of inj, dexmedetomidine 30 mcg over 10 minutes + inj propofol 100 mg IV. The patient was ventilated with 100% O₂, now millers blade was used for laryngoscopy as the spasm had improved & mouth opening was better, 7.0 cuffed ET tube was introduced and bilateral air entry was checked by auscultation and confirmed by using ETCO₂ monitoring.

The patient was vitally stable throughout the procedure, the plane of anesthesia was maintained on O₂ and air 50:50 + ini dexmedetomidine 6mcg per hour + isoflurane. Analgesia was achieved with injection paracetamol 1 gm iv + inj tramadol 100 mg iv. Intermittent temperature monitoring was done and was found to be normal throughout the surgery. ETCO₂ was maintained between 25-30 mm of Hg and the MAP was maintained between 60-65 mm of Hg. The overall blood loss was around 150 ml and urine output was 300 ml.

Before extubation Inj Ondansetron 4 mg + tracheostomy+ preparation for reintubation was kept ready. Suctioning was done and reversal was given after good respiratory efforts was observed and the patient was extubated after tone, power, reflexes and eye movements were back to normal.

3. Discussion

Masseter muscle rigidity (MMR) seen with the use of succinylcholine is rare in adults but is much more common in children. MMR has been described as 'Jaws of steel' because the jaw muscles go into spasm. Masseter muscle rigidity can be an early manifestation of MH or it can occur independently. The most dreaded complication is malignant hyperthermia (MH) as it can be fatal if not managed in time.²

Succinylcholine can cause a transient increase in muscle tone preceding the muscle paralysis. In genetically susceptible individuals this increased muscle tone especially in the jaw muscles can persist, which might lead to difficulty in mouth opening, making laryngoscopy and endotracheal intubation particularly challenging.³ This condition must be identified promptly as a failure of intubation which might cause significant morbidity and mortality if not managed appropriately. Initially endotracheal intubation can be attempted, failure of which must be followed up with other alternatives like nasotracheal intubation, LMA or retrograde endotracheal intubation. Surgical management involves cricothyroidotomy or tracheostomy which can be considered only as a last resort^{4,5} but in our patient, laryngoscopy was not possible so bag-mask ventilation was started to buy time. After about 5 more minutes laryngoscopy was re attempted and with the use of millers blade we were able to intubate the patient with a 7.0 cuffed E T tube prior to deepening the

plane of anesthesia with bolus dose of dexmedetomidine and Propofol.

Earlier reports were in favour of deferring the surgery if MMR develops but there have been a few cases where the surgery was continued using IV agents like sodium thiopental, propofol and non-depolarizing muscle relaxants with careful monitoring.⁶ Propofol is particularly useful in these situations and is the drug of choice. Propofol has multiple benefits as it can be used for the maintenance of anesthesia, it aides to relieve the MMR, and also prevents MH by acting as an anti trigger agent.⁷

After the procedure, the patient requires ICU admission for close monitoring for signs of MH (high body temperature and severe muscle rigidity); abnormalities should be identified and corrected promptly. The patient should be monitored for parameters like arterial blood gases (ABGs), oxygen saturation, end-tidal CO₂ (etCO₂), and serum K⁺ levels.^{7,8} Succinylcholine can cause a marginal increase in serum potassium. Our patient's vital parameters including etCO₂, ABG, temperature and urinalysis were all within normal limits, but a moderate increase in serum potassium was noted which confirmed the diagnosis of isolated MMR. In short, this article aims to highlight the challenges that are faced when a patient posted for surgery under general anesthesia presents with MMR and how the condition can be managed effectively during the intraoperative and postoperative period. These patients should be counselled regarding their specific condition and to be wary of these triggering drugs in the future. And the condition must be mentioned clearly in the discharge summary in order to prevent future adverse events. Muscle biopsy with caffeine testing must also be done to rule out MH.²

4. Conclusion

This case report shows MMR as an isolated event that can lead to failed laryngoscopy and endotracheal intubation. Securing of airway is of paramount importance in this case and so is vital monitoring in both intraoperative and postoperative period, especially serial temperature monitoring which aids in the diagnosis of MH. MMR should be anticipated in patients with restricted mouth opening and adequate preparation for difficult intubation and tracheostomy must be kept ready. Proper counselling and education should be given to the patient to prevent any adverse events in the future.

5. Source of Funding

None.


6. Conflict of Interest

None.

References

1. Sharma M, Sharma S, Kalra P, Kulshreshtha A. Succinylcholine induced masseter muscle rigidity: an isolated event. *Anaesth Pain Intensive Care*. 2013;17(2):174–8.
2. Sheikh MM, Riaz A, Umair HM, Waqar M, Muneeb A. Succinylcholine-Induced Masseter Muscle Rigidity Successfully Managed With Propofol and Laryngeal Mask Airway: A Case Report and Brief Review. *Cureus*. 2002;12(7):e9376.
3. Bauer SJ, Orio K, Adams BD. Succinylcholine induced masseter spasm during rapid sequence intubation may require a surgical airway: case report. *Emerg Med J*. 2005;22(6):456–8.
4. Law JA, Broemling N, Cooper RM, Drolet P, Duggan LV, Griesdale DE, et al. The difficult airway with recommendations for management—part 1—difficult tracheal intubation encountered in an unconscious/induced patient. *Can J Anaesth*. 2013;60(11):1089–118.
5. Onyeka TCU. Masseter muscle rigidity: Atypical malignant hyperthermia presentation or isolated event? *Saudi J Anaesth*. 2010;4(3):205–6.
6. Ummenhofer WC, Kindler C, Tschalär G, Hampl KF, Drewe J, Urwyler A. Propofol reduces succinylcholine induced increase of masseter muscle tone. *Can J Anaesth*. 1998;45(5 Pt 1):417–23.
7. Rosenberg H, Pollock N, Schiemann A, Bulger T, Stowell K. Malignant hyperthermia: a review. *Orphanet J Rare Dis*. 2015;10:93. doi:10.1186/s13023-015-0310-1.
8. Fitzpatrick LR. Masseter muscle rigidity, elevated creatine kinase, and rhabdomyolysis following succinylcholine administration: a case report. *AANA J*. 2008;76(5):349–54.

Author biography

Shilpa Jagdish Loya, Consultant Anesthesiologist
 <https://orcid.org/0000-0003-3678-3193>

Ashik Sreekumar, Resident

Sanhita Kulkarni, Professor and HOD

Cite this article: Loya SJ, Sreekumar A, Kulkarni S. Succinylcholine induced Masseter spasm in a young male with frontal sinus abscess. *Indian J Clin Anaesth* 2022;9(4):508-510.