

Central Macular Thickness in Diabetic Retinopathy- A Comparative Study.

Farhat Abrar¹, Priye Suman Rastogi², Munavvar Ansari³

^{1,2}Assistant Professor, Department of Ophthalmology, Teerthanker Mahaveer Medical College and Research Centre, Moradabad.

³Senior Resident, Department of Ophthalmology, Teerthanker Mahaveer Medical College and Research Centre, Moradabad.

Received: December 2016

Accepted: January 2017

Copyright: © the author(s), publisher. Annals of International Medical and Dental Research (AIMDR) is an Official Publication of "Society for Health Care & Research Development". It is an open-access article distributed under the terms of the Creative Commons Attribution Non-Commercial License, which permits unrestricted non-commercial use, distribution, and reproduction in any medium, provided the original work is properly cited.

ABSTRACT

Background: Macular oedema is one of the important signs in patients with diabetic retinopathy which progresses to complete blindness. Therefore, early diagnosis of the disease can prevent the progression of disease. **Methods:** This comparative study was conducted on 200 eyes of 100 diabetics and non-diabetics each. Subjects were divided into five groups according to the International Clinical Diabetic Retinopathy Disease Severity Scale. In each stage, macula was assessed for the presence or absence of Clinically Significant Macular Oedema (CSME) by using Optical Coherence Tomography (OCT) method. **Results:** The maximum percent of patients are present in the age group of 50-60 years. The maximum and minimum percent of patients in both the genders are diagnosed in the stage 3 and stage 4 retinopathy respectively. The mean Central Macular Thickness (CMT) in the study group was 291.0 ± 63.0 microns and the mean CMT in the control group was 216.5 ± 11.7 microns. Central macular thickness was seen to increase progressively with increasing stages of diabetic retinopathy. A statistically significant difference in mean CMT of controls when compared with each of the diabetic subgroups independently was observed. **Conclusion:** Macular thickening increased with increasing stages of diabetic retinopathy without evidence of any clinically significant macular oedema. It can be used as a good indicator to monitor such diabetic individuals.

Keywords: Central macular thickness, Diabetes, Retinopathy.

INTRODUCTION

Diabetic retinopathy is one of the important causes of blindness in adults. Macular oedema is one of the important sign in patients with diabetic retinopathy which progresses to complete blindness. Therefore, early diagnosis of the disease can prevent the progression of disease.^[1] The metabolic control and initiation of medical treatment can prevent the complications of disease and also plays an important role in postponement of potential visual compromise. The incidence of macular oedema is high and present in about 10% of diabetics. As compared to type 1, retinopathy occurs more frequently in type 2 diabetes mellitus.

Name & Address of Corresponding Author

Dr. Farhat Abrar
Assistant Professor,
Department of Ophthalmology,
Teerthanker Mahaveer Medical College and Research
Centre, Moradabad.

The main factors which control visual acuity are central foveal involvement, peri-foveal capillary blood flow velocity, severity of peri-foveal capillary occlusion and retinal thickness at the central fovea. A new non-invasive imaging modality Optical

Coherence Tomography (OCT) has been used in the diagnosis and treatment of a variety of macular diseases.^[2] This technique shows strong correlation between central foveal thickness and visual acuity. OCT is used to quantitatively measure macular thickness for diagnosis and management of macular oedema and also to detect subclinical macular thickening in Diabetic Retinopathy.^[3]

Despite its extensive clinical use, there is only limited literature on the distribution and associations of OCT measured retinal thickness regularly in white ethnic groups. Normative statistics in general populations is necessary to allow pathological changes to be related, recognized and categorized. Prior studies on macular thickness dimensions in persons with diabetes obtained using OCT and other instruments such as the retinal thickness analyser have stated variable findings.^[4] Some studies^[1,5,6] informed significantly thinner peri-central macular thickness in patients with stage 1 Diabetic Retinopathy. The hypothesis behind this is that in earlier stage neuronal loss causes significant thinning in macular region. In contrast to this, some studies found that the macula in subjects with diabetes without Diabetic Retinopathy was thicker (by more than 40 μm) than that in non-diabetic controls. The Singapore Indian Eye Study of Indian population residing in Singapore, it was found that macular

thickness did not differ significantly between diabetics and non-diabetics.^[6]

Central macula is the most sensitive retinal area accountable for variations in visual acuity. In diabetics, collapse of inner blood retinal barrier leads to outpourings, seepage and gathering of lipid exudates within the retinal layers leading to macular oedema. This is considered as the foremost cause of diminished vision in diabetic retinopathy. Thus, valuation of central macular thickness is important.^[7-9]

Due to lacunae in the literature in Indian population, the study was conducted to assess the changes in central macular thickness in diabetics with different stages of retinopathy and in non-diabetic controls.

MATERIALS AND METHODS

This comparative study was conducted in the Department of Ophthalmology in Teerthanker Mahaveer Medical College & Research Centre. It was conducted on 200 eyes of 100 diabetics and non-diabetics each. Patients with non-fasting plasma glucose ≥ 200 mg/dL were identified as suffering from diabetes mellitus. Subjects were divided into five groups according to the International Clinical Diabetic Retinopathy Disease Severity Scale.^[10]

1. Diabetics with no apparent Retinopathy (Stage 1)
2. Diabetics with Mild Nonproliferative Diabetic Retinopathy (Stage 2)
3. Diabetics with Moderate Nonproliferative Diabetic Retinopathy (Stage 3)
4. Diabetics with Severe Nonproliferative Diabetic Retinopathy (Stage 4)
5. Diabetics with Proliferative Diabetic Retinopathy (Stage 5)

In each stage, macula was assessed for the presence or absence of Clinically Significant Macular Oedema (CSME). Subjects with any coexisting macular pathology or history of retinal laser or intraocular surgery were excluded. The subjects were informed about the study. Demographic data was recorded for each subject as per protocol. All cases underwent complete ophthalmological examination including best corrected visual acuity, anterior segment examination and posterior segment examination was performed using a +90 dioptre lens. OCT scanning was performed using Zeiss Cirrus HD – OCT 500. Macular thickness measurements were obtained after pupil dilatation using tropicamide 1% and phenylephrine hydrochloride 2.5%. The OCT software generated a topographical map of the macula as defined by the Early Treatment of Diabetic Retinopathy Study (ETDRS). Foveal or central macular thickness is defined as the average thickness in the central 1 mm diameter. The fovea was measured thrice and average was calculated. The result of glycosylated haemoglobin (HbA1C)

test done in last 3 months was recorded for the study group. If not done, then non-fasting venous blood sample was investigated at the hospital laboratory for biochemical testing of HbA1C.

Statistical analysis: Statistical analysis was done using the chi-square test, Student's t-test and one-way analysis of variance (ANOVA). The correlation between central macular thickness and best corrected visual acuity was determined by Pearson's correlation coefficients. P value < 0.05 is considered as statistically significant.

RESULTS

The maximum percent of patients are present in the age group of 50-60 years. The patients are mainly diagnosed at stage 1 retinopathy with maximum of 38% in the age group of 50-60 years followed by 28% in 40-50 years [Table 1].

The maximum and minimum percent of patients in both the genders are diagnosed in the stage 3 and stage 5 retinopathy respectively. In stage 2 and 4 the percent of female patients are less as compared to males [Figure 1].

Table 1: Demographic analysis (Age in years) of the subjects.

Diabetic	Stage 1	Stage 2	Stage 3	Stage 4	Stage 5
20-30	-	2	1	-	-
30-40	6	7	10	-	-
40-50	9	16	28	1	-
50-60	12	22	38	9	2
60-70	32	18	11	11	5

The mean Central Macular Thickness (CMT) in the study group was 391.0 ± 63.0 microns and the mean CMT in the control group was 216.5 ± 11.7 microns. A statistically significant difference was observed in the mean central macular thickness between the two groups ($p < 0.05$) using unpaired Student's t-test. On comparing CMT among the various stages of retinopathy, subjects in the stage 5 group showed maximum CMT (513.5 ± 29.9 μm) while minimum CMT was seen in stage 1 retinopathy group (251.3 ± 20.8 μm).

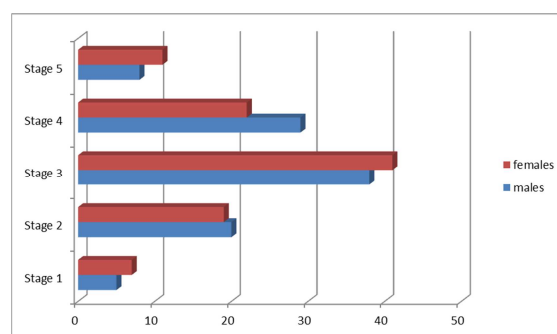


Figure 1: Demographic analysis (Gender) of the subjects.

Table 2: Central macular thickness in different stages of retinopathy.

Groups	Stage 1	Stage 2	Stage 3	Stage 4	Stage 5
CMT (microns) Mean±SD	251.3 ±20.8	257.1±1 9.5	289.5±3 9.4	298.7±1 1.9	313.5±2 9.9

Central macular thickness was seen to increase progressively with increasing stages of diabetic

retinopathy. It was observed that there was a statistically significant difference of CMT between these groups (p value <0.05) as depicted in Table 2. To look for the probability of difference in CMT in each subgroup when compared independently with other subgroups, a statistically significant difference in mean CMT of controls when compared with each of the diabetic subgroups independently was observed as shown in Table 3 (p<0.05).

Table 3: Probability of group differences (CMT).

GROUPS	Control	Stage 1	Stage 2	Stage 3	Stage 4	Stage 5
Control	-	-	<0.05	<0.05	<0.05	<0.05
Stage 1	-	-	<0.05	<0.05	<0.05	<0.05
Stage 2	-	-	-	<0.05	<0.05	<0.05
Stage 3	-	-	-	-	-	<0.05
Stage 4	-	-	-	-	-	<0.05
Stage 5	-	-	-	-	-	-

DISCUSSION

The leakage and collection of lipid exudates within the retinal layers leads to macular oedema. This is a major cause of decreased vision in Diabetic Retinopathy. Hence, assessment of thickness of central macula is important. OCT is used to quantitatively measure macular thickness for diagnosis and management of macular oedema and also to detect subclinical macular thickening in Diabetic Retinopathy.^[11,12]

In our study we found that the mean CMT in diabetics was more than that in controls and the difference was statistically significant (p<0.05). Also, CMT is directly proportional to increasing stage of the disease. These results are similar to those observed in previous studies done by various researchers. The increase in macular thickness in diabetics as compared to nondiabetic controls can be illuminated by looking at the pathophysiology of Diabetic Retinopathy. Alterations in glucose metabolism lead to changes in the capillary walls of retinal vessels. This leads to breakdown of blood retinal barrier causing haemorrhages and seepage of exudates, which in turn present as detectable retinal thickening in OCT.^[13-15]

In contrast to our study, few researchers^[16-19] reported early macular thickening in diabetic eyes, however, the difference was not statistically significant. In certain patients they observed significantly higher macular thickness in diabetics without clinical retinopathy when compared with controls.

In a study conducted by Oshitari et al^[20] in Japan in 2009, it was seen that central macula in early stages of DR was significantly thinner than controls. This was explained by the neuronal abnormalities due to diabetes including retinal ganglion cell death and axonal degeneration. These neuronal alterations were hypothesised to precede the vascular

abnormalities in diabetic subjects with early diabetes and thus were responsible for thinner macula in diabetic patients.

On comparing mean CMT in different DR subgroups, it was found to be progressively increasing with increasing stage of DR. The mean CMT values in different subgroups of our subjects are comparable with previous studies.^[17,21] This increased macular thickness with progressively increasing retinopathy can be explained by alterations in vascular permeability of peri-foveal and macular capillaries in diabetics eyes. In our study, there was a statistically significant difference in mean CMT when comparing no DR with mild NPDR and mild NPDR with moderate NPDR. But, no significant difference in mean CMT between moderate NPDR and severe NPDR was observed. This could be because of small number of cases in severe NPDR subgroup.^[22]

Our study showed statistically significant difference in mean CMT in stage 5 group as compared with other groups as shown in previous studies. This difference can be because of leaking microaneurysms or diffusion from capillary incompetent areas lead to the collection of intraretinal fluid in the macular area.^[23]

Thus, our study suggests that changes in macular thickness can be detected by OCT despite normal findings in slit lamp biomicroscopy. These patients are candidates for more frequent and more detailed follow up as they are likely to develop CSME.

CONCLUSION

Macular thickening increased with increasing stages of diabetic retinopathy without evidence of any clinically significant macular oedema. It can be used as a good indicator to monitor such diabetic individuals. Besides this, vision-threatening macular oedema can be detected earlier.

REFERENCES

1. Congdon N, O'Colmain B, Klaver CC, et al. Causes and prevalence of visual impairment among adults in the United States. *Arch Ophthalmol* 2004;122(4):477-485.
2. Klein R, Klein BE, Moss SE, et al. The Wisconsin epidemiologic study of diabetic retinopathy. XV. The long term incidence of macular edema. *Ophthalmology* 1995;102(1):7-16.
3. Gardner TW, Larsen M, Girach A, et al. Diabetic macular edema and visual loss: relationship to location, severity and duration. *Acta Ophthalmol* 2009;87(7):709-713.
4. Browning DJ, McOwen MD, Bowen RM, et al. Comparison of the clinical diagnosis of diabetic macular edema with diagnosis by optical coherence tomography. *Ophthalmology* 2004;111(4):712-715.
5. Wild S, Roglic G, Green A, et al. Global prevalence of diabetes: estimates for the year 2000 and projections for 2030. *Diabetes Care* 2004;27(5):1047-1053.
6. Biallostowski C, van Velthoven ME, Michelis RP, et al. Decreased optical coherence tomography-measured pericentral retinal thickness in patients with diabetes mellitus type 1 with minimal diabetic retinopathy. *Br J Ophthalmol* 2007;91(9):1135-1138.
7. Lattanzio R, Brancato R, Pierro L, et al. Macular thickness measured by optical coherence tomography (OCT) in diabetic patients. *Eur J Ophthalmol* 2002;12(6):482-487.
8. Kashani A, Zimmer-Galler IE, Shah SM, et al. Retinal thickness analysis by race, gender, and age using stratus OCT. *Am J Ophthalmol* 2010;149(3):496-502.
9. Sng CC, Cheung CY, Man RE, et al. Influence of diabetes on macular thickness measured using optical coherence tomography: the Singapore Indian eye study. *Eye* 2012;26(5):690-698.
10. Supplement 1. American diabetes association: clinical practice recommendations 2000. *Diabetes Care* 2000;23(Suppl 1):S1-116.
11. Klein R, Klein BE, Moss SE, et al. The Wisconsin epidemiologic study of diabetic retinopathy: XVII. The 14-year incidence and progression of diabetic retinopathy and associated risk factors in type 1 diabetes. *Ophthalmology* 1998;105(10):1801-1815.
12. Yang CS, Cheng CY, Lee FL, et al. Quantitative assessment of retinal thickness in diabetic patients with and without clinically significant macular edema using optical coherence tomography. *Acta Ophthalmol* 2001;79(3):266-270.
13. Schaudig UH, Glaefke C, Scholz F, et al. Optical coherence tomography for retinal thickness measurement in diabetic patients without clinically significant macular edema. *Ophthalmic Surg Lasers* 2000;31(3):182-186.
14. Brown JC, Solomon SD, Bressler SB, et al. Detection of diabetic foveal edema: contact lens biomicroscopy compared with optical coherence tomography. *Arch Ophthalmol* 2004;122(3):330-335.
15. Sanchez-Tocino H, Alvarez-Vidal A, Maldonado MJ, et al. Retinal thickness study with optical coherence tomography in patients with diabetes. *Invest Ophthalmol Vis Sci* 2002;43(5):1588-1594.
16. Kanski JJ, Bowling B, Nischal KK, et al. Retinal vascular disease. In: *Clinical ophthalmology: a systematic approach*. 7th edn. London: Elsevier Saunders 2011:534-543.
17. Massin P, Erginay A, Haouchine B, et al. Retinal thickness in healthy and diabetic subjects measured using optical coherence tomography mapping software. *Eur J Ophthalmol* 2002;12(2):102-108.
18. Sander B, Larsen M, Engler C, et al. Early changes in diabetic retinopathy: capillary loss and blood-retina barrier permeability in relation to metabolic control. *Acta Ophthalmol* 1994;72(5):553-559.
19. Yeung L, Sun CC, Ku WC, et al. Associations between chronic glycosylated haemoglobin (HbA1c) level and macular volume in diabetes patients without macular edema. *Acta Ophthalmol* 2010;88(7):753-758.
20. Oshitari T, Hanawa K, Adachi-Usami E. Changes of macular and RNFL thickness measured by stratus OCT in patients with early stage diabetes. *Eye* 2009;23(4):884-889.
21. Nussenblatt RB, Kauffman SC, Palestine AG, et al. Macular thickening and visual acuity. Measurement in patients with cystoid macular edema. *Ophthalmology* 1987;94(9):1134-1139.
22. Chou TH, Wu PC, Kuo JZ, et al. Relationship of diabetic macular edema with glycosylated haemoglobin. *Eye* 2009;23(6):1360-1363.
23. Nussenblatt RB, Kauffman SC, Palestine AG, et al. Macular thickening and visual acuity. Measurement in patients with cystoid macular edema. *Ophthalmology* 1987;94(9):1134-1139.

How to cite this article: Abrar F, Rastogi PS, Ansari M. Central Macular Thickness in Diabetic Retinopathy- A Comparative Study. *Ann. Int. Med. Den. Res.* 2017; 3(2):OT01-OT04.

Source of Support: Nil, **Conflict of Interest:** None declared