

Content available at: <https://www.ipinnovative.com/open-access-journals>

Indian Journal of Orthopaedics Surgery

Journal homepage: <https://www.ijos.co.in/>

Original Research Article

A modified retrograde drilling technique of osteochondral lesions of the talus: A technical note

Dheeraj Makkar^{1,*}, Hak Jun Kim², Yeo Eui Dong², Myong-Hoi Hwang²¹NC Medical College and Hospital, Panipat, Haryana, India²Guro Hospital, KUMC, Seoul, South Korea

ARTICLE INFO

Article history:

Received 09-12-2021

Accepted 12-01-2022

Available online 24-03-2022

Keywords:

Osteochondral lesions

ACL jig

Talus

Retrograde drilling

ABSTRACT

Background: Osteochondral lesions of the talus typically present as cartilage denudation after trauma or as cystic lesions in the bone with intact cartilage. Osteochondral fractures require an anterograde approach for treatment. Retrograde drilling and packing with a bone graft can treat lesions with intact cartilage. Because subchondral lesions involve the posterior aspect of the talar dome, these lesions can be difficult to localize with an image intensifier.

Description of Technique: We describe a method in which ankle arthroscopy is used to visualize a subchondral lesion, along with an ACL jig to target the lesion precisely.

Materials and Methods: We performed retrograde drilling in two patients: a 29-year-old man and a 34-year-old man. Each patient presented with a subchondral cystic lesion in the posteromedial aspect of the talus. We treated both patients by modifying the standard technique for retrograde drilling. Patients were evaluated before and after surgery using the AOFAS score and X-rays of the ankle joint.

Results: The X-rays taken at the 3-month follow-up showed a well-maintained contour of the talar dome with complete incorporation of the bone graft. The AOFAS scores for both patients were greater than 90, excellent per the Saxena and Eakin criteria.

Conclusions: This method decreases radiation exposure, invasiveness, and surgical time of the procedure.

This is an Open Access (OA) journal, and articles are distributed under the terms of the [Creative Commons Attribution-NonCommercial-ShareAlike 4.0 License](https://creativecommons.org/licenses/by-nc-sa/4.0/), which allows others to remix, tweak, and build upon the work non-commercially, as long as appropriate credit is given and the new creations are licensed under the identical terms.

For reprints contact: reprint@ipinnovative.com

1. Introduction

Osteochondral lesions of the talus are lesions of the articular cartilage and subchondral bone. These lesions may primarily result from trauma, ischemia, and genetic predisposition.^{1,2} Osteochondral lesions of the talus can occur up to 90% of the time after an injury that fractures the ankle.³

Clinically, the patient complains of discomfort on the medial or lateral side of the ankle, depending on the location of the lesion, and persistent swelling three to six weeks after the event. If a piece of cartilage remains loose in the joint after avulsion, the patient may also experience recurrent

episodes of synovitis and locking during ankle movement.

Conservative treatment, marrow stimulation, and cartilage or tissue transplantation are all ways to address osteochondral lesions. One of the treatments of osteochondral lesions involves breaking the sclerotic bone with an anterograde or retrograde drilling approach to permit revascularization of the defect. Because the anterograde approach violates the continuity of the articular cartilage of the talus, it increases the risk for osteoarthritis.⁴

We can access the lesion from beneath the subchondral bone via the retrograde approach helps to preserve the native cartilage overlying the lesion. In the standard technique for retrograde drilling, arthroscopy is performed first to visualize and define the lesion, followed by

* Corresponding author.

E-mail address: makkardheeraj@gmail.com (D. Makkar).

fluoroscopic imaging to localize and treat the lesion. Unfortunately, the standard technique is technically challenging, particularly when treating lesions in the posteromedial and posterolateral regions of the talus.⁵

We describe a simple method to precisely target a subchondral cyst with an overlying intact cartilage layer on the talus dome using an ACL jig (Arthrex ACL tibial jig) for accurate localization and retrograde drilling. This method makes it possible to treat the lesion arthroscopically, avoiding fluoroscopy and excessive radiation exposure.

1.1. Technique

We conducted ankle arthroscopy in the plantar-flexed position. A specially designed traction device maintained the foot in plantar-flexion and provided optimum distraction due to traction (10 kg) (Figure 1). The traction device eliminated the need for an assistant to hold the foot or the operating surgeon to tie a belt around the patient's waist to distract the joint. We performed diagnostic arthroscopy with a 4-mm, 30-degree arthroscope inserted through the standard anterolateral and anteromedial portals and addressed the loose bodies or frayed tissues appropriately. The cyst in the underlying bone was identified by a softening of the overlying cartilage, evident when gently probing the surface of the talar dome (Figure 2).

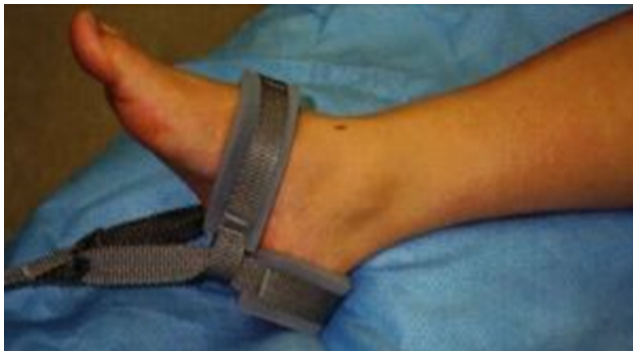

Fig. 1: Traction device holds the foot in plantar flexion and provides a distraction

1.2. Localization

For both patients, the ACL jig was introduced through an accessory portal on the anteromedial aspect; the ACL jig can also be inserted through the anterolateral side, depending upon the site of the lesion (Figure 3). We used an end-to-end ACL jig and blunted the tip to avoid damaging the cartilage during the procedure. The anterolateral portal served as the viewing portal. A scoop was used to facilitate the placement of the ACL jig on the lesion, preventing even minimal damage to the articular cartilage. The blunted tip of the ACL jig was rested in the scoop, positioned precisely on the lesion (Figure 4).

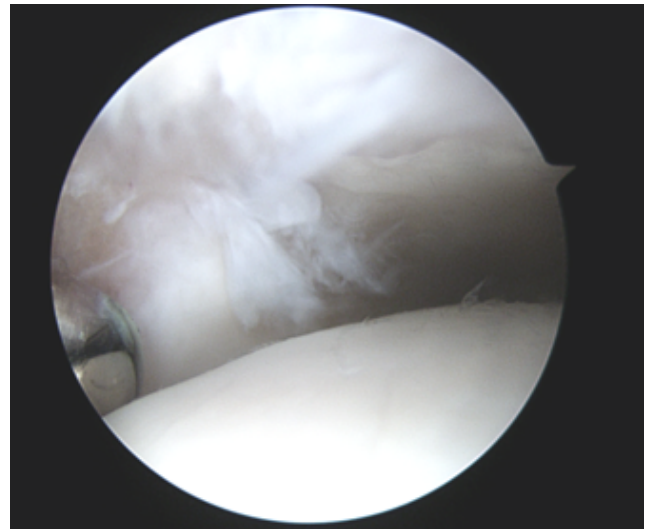


Fig. 2: Softening of the cartilage with fibrillation

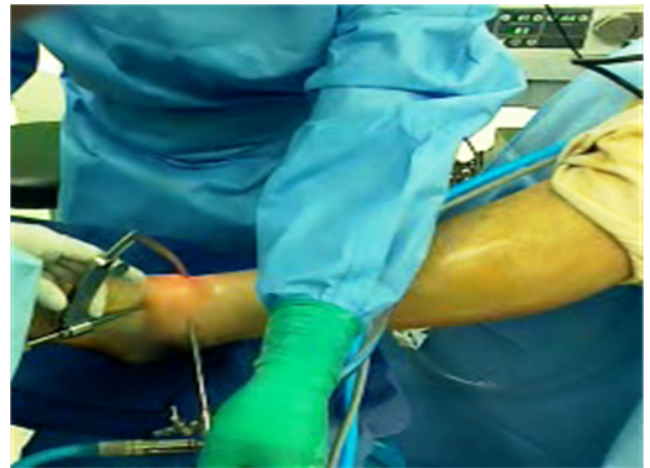


Fig. 3: ACL jig introduced arthroscope in anterolateral portal

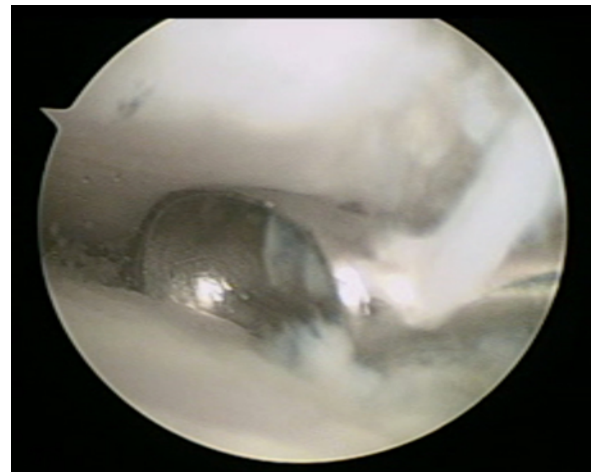


Fig. 4: Scoop positioned on the softened cartilage

1.3. Drilling

The ACL jig was secured at a 60-degree angle to ensure the aiming pin was oriented vertically to avoid the talus's articular cartilage. The targeting pin was bored into the subchondral cyst, and the abrupt reduction of resistance established the drilling stop encountered while drilling through the bone. The scope was positioned in the ankle joint throughout the drilling process to visualize the lesion, analogous to tibial tunnel preparation in ACL reconstruction. The image intensifier confirmed the pin position in both the AP and lateral views (Figure 5). The pin was precisely positioned in the center of the cyst for both patients. Reaming of the subchondral cyst was done with a 4.5-mm cannulated screw drill bit using the aiming pin as the guide pin. The 4.5-mm cannulated screw reamer was left in place and served as the conduit to pack the lesion with an autogenous cancellous bone graft from the iliac crest.

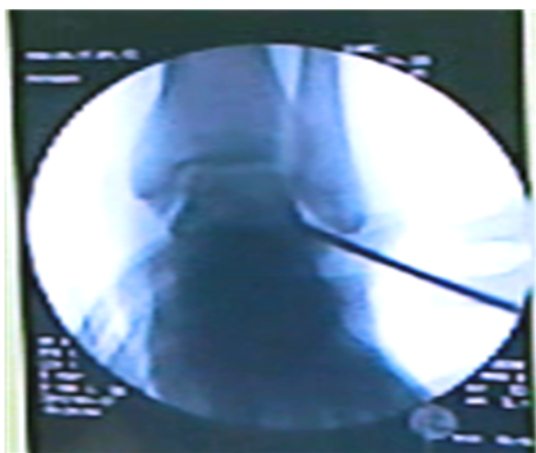

Fig. 5: Pin position checked under image intensifier

2. Materials and Methods

We performed retrograde drilling in two patients: a 29-year-old man and a 34-year-old man. Each patient presented with a posteromedial subchondral cystic lesion in the talus. Both patients underwent retrograde drilling using our modified approach.

Patients were evaluated before and after surgery using the AOFAS score. The clinical results at final follow-up were classified according to the criteria of Saxena and Eakin (excellent, 90-100; good, 80-89; fair, 70-79; poor, <70).⁶

The pre-operative evaluation included weight-bearing radiographs (AP, lateral and mortise view) followed by MRI to determine the size of the lesion and the thickness of the cartilage overlying the subchondral cyst. The ellipse formula was used to determine the size of the lesion (length in the coronal plane x length in the sagittal plane x 0.79). The patients were selected for retrograde drilling because the lesion size was less than 1.5 cm². The radiographic

assessment involved a comparison of the weight-bearing AP and lateral views of the operated side before and after surgery.

3. Results

The patients were instructed to use a non-weight-bearing walking cast for four weeks and were allowed full weight-bearing after that.⁷ The X-rays taken at the 3-month follow-up showed a well-maintained contour of the talar dome with complete incorporation of the bone graft. The AOFAS scores for both patients were greater than 90, excellent per the Saxena and Eakin criteria.

4. Discussion

Arthroscopic retrograde drilling is the recommended treatment for subchondral lesions of the talus, but failure rates can be as high as 20% due to inaccurate targeting of the lesion.⁵ Filling the defect with a bone graft can also be challenging due to inadequate localization under the image intensifier. Even if the surgeon has targeted the lesion, the surgeon may overlook it during drilling. Due to the small size of the talus, frequent drilling might result in significant damage. Navigation and MRI-based systems help locate the lesion during arthroscopy.⁵ While navigation technologies allow for precise lesion localization, they are expensive and complex to operate. Secondly, these systems are developing in nature regarding foot and ankle surgery.

The standard technique for retrograde drilling uses an image intensifier as an adjunct to arthroscopic visualization for drilling and packing the defect with a bone graft. Our modification uses ankle arthroscopy to visualize a subchondral lesion and an ACL jig to precisely target the lesion.

This modified technique has the following advantages. It reduces the use of the image intensifier; radiation exposure to the patient decreases the surgical time and invasiveness of the procedure. The technique is simple, cost-effective, and requires no specialized training or equipment other than an ACL jig, guide pins, and cannulated screw drill bits.

Our technique has some limitations. It necessitates a great degree of precision, has a limited application range, and is limited to lesions with intact cartilage. Thus, the technique cannot be generalized to all types of osteochondral lesions. This approach only applies to lesions less than 1.5cm² in size; more extensive regions require an open procedure or tissue transplantation.⁵ Another disadvantage is that if the ACL jig is too sharp, it may damage the articular cartilage of the talus.

5. Conclusion

Our adaptation of the traditional retrograde drilling approach uses an end-to-end ACL jig with a blunted placement tip. It is a relatively affordable method of

accurately addressing a subchondral cystic lesion of the talus. Significantly, this procedure minimizes radiation exposure and operation time, which benefits both the patient and the physician.

6. Ethical Statement

We explained the study to all participants and got their informed consent from them. Any improvisation of the previously existing technique with approved equipment has been permitted by KUGH IRB (Korea University Guro Hospital Institutional Review Board).

7. Conflict of Interest

All the authors emphatically state there is no conflict of interest between the authors and no funds or grants were received for the work.

References

- Zanon G, Vico GD, Marullo M. Osteochondritis dissecans of the talus. *Joints*. 2014;2(3):115–23.
- Steinhagen J, Niggemeyer O, Bruns J. Etiology and pathogenesis of osteochondritis dissecans of the talus. *Orthop*. 2001;30(1):20–7.
- Martijn HA, Lambers KTA, Dahmen J, Stufkens SAS, Kerkhoffs G. High incidence of (osteo)chondral lesions in ankle fractures. *Knee Surg Sports Traumatol Arthrosc*. 2021;29(5):1523–34.
- Murawski CD, Kennedy JG. Operative Treatment of Osteochondral Lesions of the Talus. *J Bone Joint Surg Am*. 2013;95(11):1045–54.
- Rungprai C, Tennant JN, Gentry RD, Phisitkul P. Management of Osteochondral Lesions of the Talar Dome. *Open Orthop J*. 2017;11:743–61.
- Saxena A, Eakin C. Articular Talar Injuries in Athletes: Results of Microfracture and Autogenous Bone Graft. *Am J Sports Med*. 2007;35(10):1680–7.
- Kumai T, Takakura Y, Higashiyama I, Tamai S. Arthroscopic drilling for the treatment of osteochondral lesions of the talus. *J Bone Joint Surg Am*. 1999;81(9):1229–35.

Author biography

Dheeraj Makkar, AP Orthopaedics  <https://orcid.org/0000-0002-8498-7935>

Hak Jun Kim, HOD (Foot and Ankle Unit)

Yeo Eui Dong, Clinical Fellow

Myong-Hoi Hwang, Clinical Fellow

Cite this article: Makkar D, Kim HJ, Dong YE, Hwang MH. A modified retrograde drilling technique of osteochondral lesions of the talus: A technical note. *Indian J Orthop Surg* 2022;8(1):58-61.