



## Case Report

# Non-ketotic hyperglycemia presenting as acute hemiparkinsonism

Nagabushan Hesarur<sup>1</sup>, Saji K John<sup>1</sup>, Thomas Mathew<sup>1,\*</sup>

<sup>1</sup>Dept. of Neurology, St. Johns Medical College Hospital, Bengaluru, Karnataka, India



### ARTICLE INFO

#### Article history:

Received 29-07-2021

Accepted 08-09-2021

Available online 25-09-2021

#### Keywords:

Hyperglycemia

Parkinsonism

Putaminal hyperintensity

### ABSTRACT

Non-ketotic hyperglycaemia is commonly associated with hyperkinetic movement disorders like chorea. Here we report a case of non-ketotic hyperglycaemia, in a 70 year old man with longstanding diabetes presenting as acute onset hemi-parkinsonism. Hypokinetic movement disorders are only rarely reported in non-ketotic hyperglycaemia.

This is an Open Access (OA) journal, and articles are distributed under the terms of the [Creative Commons Attribution-NonCommercial-ShareAlike 4.0 License](https://creativecommons.org/licenses/by-nc-sa/4.0/), which allows others to remix, tweak, and build upon the work non-commercially, as long as appropriate credit is given and the new creations are licensed under the identical terms.

For reprints contact: [reprint@ipinnovative.com](mailto:reprint@ipinnovative.com)

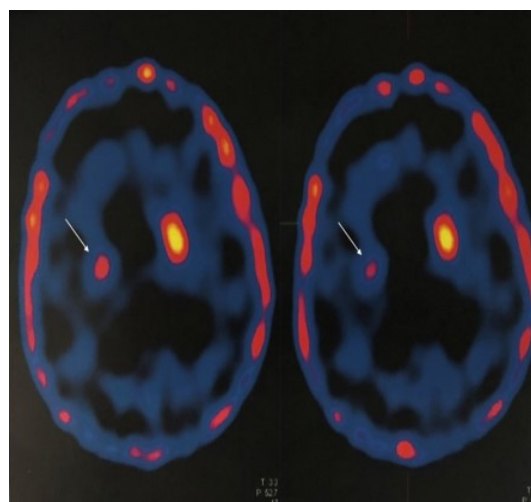
## 1. Introduction

Acute Parkinsonism occurs due to a variety of non-degenerative causes, which on most occasions are reversible. Most common aetiologies include drugs, structural lesions like strokes, toxin exposure and infections like toxoplasma.<sup>1</sup> Here we report a case of acute hemiparkinsonism caused by hyperglycemia in a diabetic patient.

## 2. Case Report

A 70-year-old man, a known diabetic for 30 years presented with acute onset of walking difficulty and slowness of movements of left upper and lower limb. He was suspected to have stroke but the MRI Brain did not reveal any features of acute stroke. He was diagnosed as Parkinson's disease based on the PET scan finding of hypometabolism involving right putamen (Figure 1). He was started on Syndopa 125 mg (Levodopa 100 mg + carbidopa 25mg) thrice a day for his parkinsonism, but there was no benefit with the medication. He had come for a second opinion after one month of his disease onset. On reviewing the history, the extrapyramidal symptoms were acute in onset. The

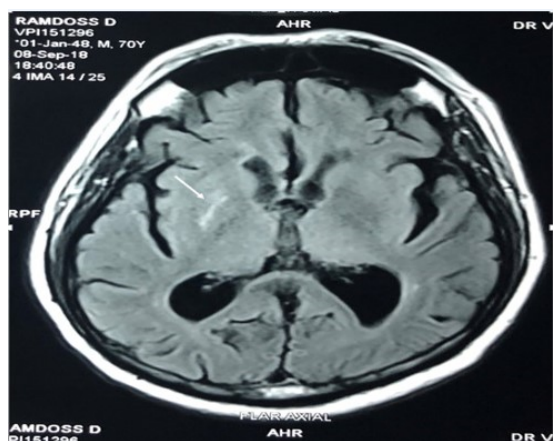
symptoms started over hours, reached a nadir at 24 hours and improved slightly over one month. His neurological examination revealed mask facies, rigidity, bradykinesia and reduced arm swing on the left side but there was no tremor.



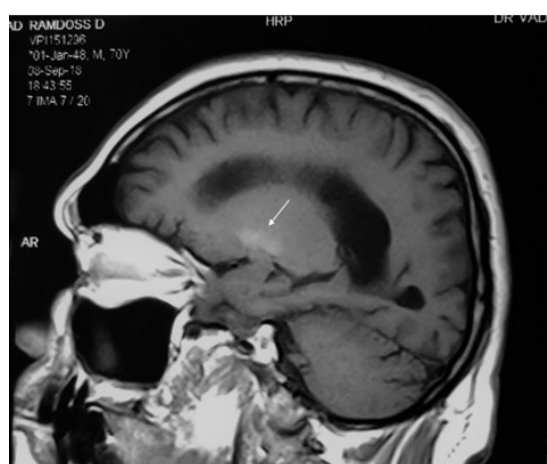
**Fig. 1:** DOPA PET scan showing hypometabolism in right putamen

\* Corresponding author.

E-mail address: [chakkuthom@hotmail.com](mailto:chakkuthom@hotmail.com) (T. Mathew).



**Fig. 2:** MRI Brain FLAIR sequence showing hyperintensity in the right putamen (white arrow)



**Fig. 3:** MRI Brain T1w sagittal sequence showing hyperintensity in right basal ganglia

His blood sugar level at the time of onset of symptoms was 400mg/dl with an HbA1c of 11%. His urine ketones were negative. His MRI Brain revealed right putaminal hyperintensity on FLAIR (Figure 2) and T1W images (Figure 3) with no diffusion restriction. A diagnosis of hemiparkinsonism due to non ketotic hyperglycemia was made. He was advised intensive glycaemic control and Syndopa was withdrawn. His parkinsonian symptoms improved slowly over months and at 12 months follow up his left sided bradykinesia and rigidity had improved significantly.

### 3. Discussion

Hyperglycemia causing hyperkinetic movement disorders like hemiballismus and hemichorea is a well-recognized entity.<sup>2</sup> However, hypokinetic movement disorders like acute hemiparkinsonism secondary to hyperglycemia is rarely seen and reported. The lack of awareness of this entity

led to a mistaken diagnosis of Parkinson's disease in our patient. The findings of PET scan showing hypometabolism in the putamen also misled the physician. Physicians should be aware that a PET scan reveals only a hypofunction of the basal ganglia and does not point to the exact etiology. The etiological diagnosis must be reached based on detailed history including the type of onset, drug exposure, investigations including blood glucose, calcium, MRI Brain and in some cases genetic studies. Hsu et al reported a case of hyperglycemia having clumsiness and unsteadiness without any involuntary movements and characteristic signal changes in basal ganglia on MRI.<sup>3</sup> The exact pathogenesis of hyperglycemia-induced basal ganglia injury is not known. Although glucose is the sole energy source for the brain, its utilization at the cellular level remains elusive. Increased glucose metabolism is seen in substantia nigra pars reticulata and globus pallidus externa of Parkinson's disease patients.<sup>4</sup> Metabolic derangement, vascular insufficiency, hyperviscosity, and vasogenic edema may play a role in basal ganglia cell injury.<sup>3</sup> In these patients, proper functioning of the basal ganglia cells may be compromised by chronic ischemia due to microangiopathic changes without the development of an infarct.<sup>5</sup> When a stage of the metabolic crisis is reached, either because there is a further compromise of circulation or glucose dysmetabolism, the clinical syndrome begins. Basal ganglia injury causes reactive astrocytosis and manganese deposition producing the typical signal changes on MRI.<sup>6</sup>

Acute hemiparkinsonism is a rare entity and prompt identification of the cause and early initiation of treatment may result in a good prognosis. Before initiating the long-term antiparkinsonian medications, one should look for reversible causes. Amongst them, hyperglycemia appears to be an unrecognised cause and all patients presenting with acute hemiparkinsonism should also be evaluated for hyperglycemia. The prompt treatment of hyperglycemia may help in improving the parkinsonian features.

### 4. Conflict of Interest

The authors declare that there are no conflicts of interest in this paper.

### 5. Source of Funding

None.

### References


1. Fernandez HH, Friedman JH. Acute Parkinsonism. Current Clinical Neurology: Movement Disorder Emergencies: Diagnosis and Treatment. Humana Press, Totowa, NJ; 2013. doi:10.1007/978-1-60761-835-5\_2.
2. Roy AK, Raghunandan N, Sarma, Mathew T. A case series of hemichorea due to nonketotic hyperglycemia with MRI brain finding. *J Neurol Neurophysiol.* 2013;(S11). doi:10.4172/2155-9562.S11-006.

3. Hsu JL, Wang HC, Hsu WC. Hyperglycemia induced unilateral basal ganglion lesions with and without hemichorea A PET Study. *J Neurol.* 2004;251(12):1486–90. doi:10.1007/s00415-004-0571-4.
4. Yamada K. Glucose metabolism in the basal ganglia. *Brain Nerve.* 2009;61(4):381–8.
5. Ziegler D, Langen KJ, Herzog H, Kuwert T, Muhlen H, Feinendegen LE, et al. Cerebral glucose metabolism in type 1 diabetic patients. *Diabet Med.* 1994;11(2):205–9. doi:10.1111/j.1464-5491.1994.tb02021.x.
6. Fujioka M, Taoka T, Matsuo Y, Mishima K, Ogoshi K, Kondo Y, et al. Magnetic resonance imaging shows delayed ischemic striatal neurodegeneration. *Ann Neurol.* 2003;54(6):732–47. doi:10.1002/ana.10751.

### Author biography

**Nagabushan Hesarur**, Senior Resident

**Saji K John**, Research Coordinator

**Thomas Mathew**, Professor and Head  <https://orcid.org/0000-0002-3941-8020>

**Cite this article:** Hesarur N, John SK, Mathew T. Non-ketotic hyperglycemia presenting as acute hemiparkinsonism. *IP Indian J Neurosci* 2021;7(32):254-256.