

Content available at: <https://www.ipinnovative.com/open-access-journals>

IP Indian Journal of Anatomy and Surgery of Head, Neck and Brain

Journal homepage: <https://www.ijashnb.org/>

Letter to Editor

Chipmunk facies' in treated post-covid rhino-orbito-cerebral mucormycosis cases

Abhimanyu Kadapathri^{1,*}, Vaibhav Shandilya², Karampreet Singh³

¹Dept. of ENT and Head and Neck Onco-Surgery, Ruban Hospital, Patna, Bihar, India

²Dept. of Maxillofacial Surgery, Patna Medical College and Hospital, Patna, Bihar, India

³Dept. of Plastic Surgery, Ruban Hospital, Patna, Bihar, India



ARTICLE INFO

Article history:

Received 17-08-2021

Accepted 29-09-2021

Available online 22-10-2021

This is an Open Access (OA) journal, and articles are distributed under the terms of the [Creative Commons Attribution-NonCommercial-ShareAlike 4.0 License](https://creativecommons.org/licenses/by-nc-sa/4.0/), which allows others to remix, tweak, and build upon the work non-commercially, as long as appropriate credit is given and the new creations are licensed under the identical terms.

For reprints contact: reprint@ipinnovative.com

Mucormycosis as a sequelae of clinical event post COVID-19 infection caused by a filamentous fungus (class: Zygomycetes and order: Mucorales) has been termed Covid-associated mucormycosis (CAM). India in particular has seen a recent surge in cases associated with high morbidity and mortality. Since the onset of the COVID 19 pandemic there have been multiple reports across country of very high incidence of mucormycosis among patients with COVID 19 especially in those who are diabetic and those who have received steroids. (1) Published literature showed various observations linked to mucormycosis such as long term systemic steroid usage, long term hypoxia, uncontrolled diabetes, longer ICU stay etc.¹⁻⁴ The sudden surge in mucormycosis patients during the worst hit phase by COVID-19 2nd phase in India lead to extreme difficulty in prioritising treatment for these patients. SARS-CoV2 variant (B.1.1.7 & B.6.117) was the most prevalent one during second phase.⁵ In-silico studies have shown stable interaction between RBD domain of spike protein (C480-488,) and GRP 78 predicting its role in endocytosis^{6,7} coat protein CoH3 of mucor favours similar pathway of entry through GRP78 into nasal and paranasal sinus mucosa. Over expression of GRP78 in these patients may be related to dexamethasone induced, endoplasmic reticulum stress induced or due to increased iron and high glucose,⁷⁻⁹ there

is further need for studies in GRP 78 expression context.

Procurement and administration of liposomal amphotericin B has become extremely difficult. Although we tried to stick to management guidelines suggested by European Confederation of Medical Mycology,¹⁰ we as well as many Indian centres couldn't stick to it as we were facing logistics issues. Our centre has successfully managed 35 cases of mucormycosis. We would like to report the structural complications in nasal pyramid post endoscopic denker's procedure in mucormycosis survivors. Out of 35 treated cases 25 survived and completed 45 day followup. We had endoscopically addressed 22 of those survivors modified denker's approach. Nasal structure related complications were found in 2 of these patients, 1 patient has partial stenosis + alar notching while other had alar notching only. These patients were planned for aesthetic surgery after completing their course of posaconazole.

During the denker's approach, these patients required additional drilling of fronto-nasal process of maxilla to improve access to anterior and lateral most extent of maxillary sinus. Functional problem associated with this complication is the obliteration and loss of pliability of the nasal valve. Anatomically the internal nasal valve area borders are the septum, pyriform aperture floor, and head of the inferior turbinate and the caudal border of the upper lateral cartilage. The pyriform aperture region of the nasal valve has been found to have the smallest cross sectional

* Corresponding author.

E-mail address: abhimanyukadapathri@gmail.com (A. Kadapathri).

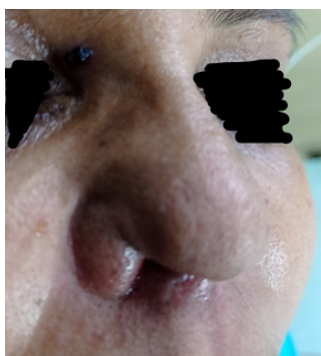

Fig. 1:

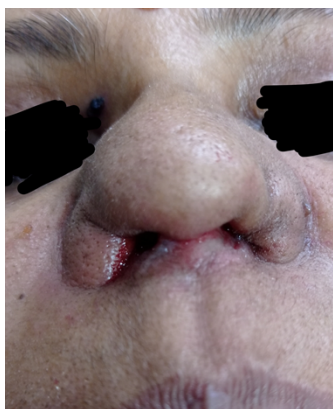

Fig. 2:

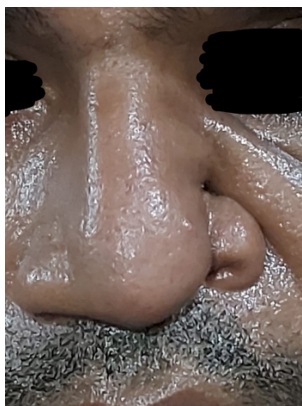


Fig. 3:

area of the whole nasal valve and $2/3^{rd}$ of nasal resistance is also in that area.¹¹

We would like to report these cases to make an understanding in the rhinology community that many of mucormycosis survivors would need cosmetic treatments in the coming months. On the verge of a third wave lurking

around the corner, close followup of previously treated patients and preparedness for future flock of mucormycoses is of utmost importance.

Conflict of Interest

The authors declare that there are no conflicts of interest in this paper.

References

1. Singh AK, Singh R, Joshi SR, Misra A. Mucormycosis in COVID-19: A systematic review of cases reported worldwide and in India. *Diabetes Metab Syndr Clin Res Rev.* 2021;15(4):102146.
2. Revannavar SM, Supriya P, Samaga L, Vineeth K. COVID-19 triggering mucormycosis in a susceptible patient: A new phenomenon in the developing world? *BMJ Case Rep.* 2021;14(4):e241663. doi:10.1136/bcr-2021-241663.
3. Ravani SA, Agrawal GA. Rise of the phoenix: mucormycosis in COVID-19 times. *Indian J Ophthalmol.* 2021;69(6):1563–8. doi:10.4103/ijo.IJO_310_21.
4. Hernández J, Buckley CJ. Mucormycosis. Treasure Island (FL). StatPearls Publishing; 2021.
5. Vaidyanathan G. Coronavirus variants are spreading in india - what scientists know so far (News in Focus). *Nature.* 2021;593(7859):321–2. doi:10.1038/d41586-021-01274-7.
6. Graham MS, Sudre CH, May A. Changes in symptomatology, reinfection, and transmissibility associated with the SARS-CoV-2 variant B.1.1.7: an ecological study. *Lancet Public Heal.* 2021;6(5):335–45. doi:10.1016/S2468-2667(21)00055-4.
7. Elfiky AA, Ibrahim IM, Elgohary AE. Host-cell recognition through GRP78 is enhanced in the new variants of SARS-CoV-2. *Res Sq.* 2021;85(5):186–230. doi:10.1016/j.jinf.2021.01.015.
8. Banerjee AK, Begum F, Srivastava AK. Overexpression of GRP78 receptor and its chemical biology in cancer and autoimmune diseases: high risk for COVID 19? ; 2020.
9. Sabirli R, Koseler A, Goren T. High GRP78 levels in Covid-19 infection: a case-control study. *Life Sci.* 2021;(265):118781. doi:10.1016/j.lfs.2020.118781.
10. Cornely OA, Alastruey-Izquierdo A, Arenz D, Chen S, Dannaoui E, Hochhegger B, et al. Global guideline for the diagnosis and management of mucormycosis: an initiative of the European Confederation of Medical Mycology in cooperation with the Mycoses Study Group Education and Research Consortium. *Lancet Infect Dis.* 2019;19(12):405–21.
11. Smith W, Lowe D, Leong P. Resection of pyriform aperture: a useful adjunct in nasal surgery. *J Laryngol Otol.* 2009;123(1):123–8.

Author biography

Abhimanyu Kadapathri, Consultant

Vaibhav Shandilya, Consultant

Karampreet Singh, Consultant

Cite this article: Kadapathri A, Shandilya V, Singh K. Chipmunk facies' in treated post-covid rhino-orbito-cerebral mucormycosis cases. *IP Indian J Anat Surg Head, Neck Brain* 2021;7(3):67-68.