

Content available at: <https://www.ipinnovative.com/open-access-journals>

IP International Journal of Ocular Oncology and Oculoplasty

Journal homepage: <https://ijooo.org/>

## Case Report

# Orbital lymphangioma: A rare case report

Raisa Tandon<sup>1,\*</sup>, Deepanjan Ghosh<sup>1</sup>, Suchita Singh<sup>1</sup>, Anjani Agarwalla<sup>1</sup>

<sup>1</sup>Dept. of Ophthalmology, Assam Medical College and Hospital, Dibrugarh, Assam, India



### ARTICLE INFO

#### Article history:

Received 19-07-2021

Accepted 25-08-2021

Available online 25-10-2021

#### Keywords:

Proptosis

Extraocular Muscles

Orbital

Lymphangioma

Bleomycin

### ABSTRACT

A 16 year old female resident of Arunachal Pradesh presented with the complaints of forward bulging of left eye for 1 year and diminution of vision since 4 months with V/A 6/6 in right eye and 4/60 in left eye. On examination, abaxial proptosis of around 15mm with inferior dystopia was present in left eye with restriction of extraocular movements in all directions. Fundus examination revealed clear media with blurring of disc margin alongdioptr. CT Scan upto the orbital apex causing displacement of extraocular muscles and optic nerve that was found to be lymphangioma of orbit. She recievedintralesionalBleomycin alongin vision and regression of the tumor.

This is an Open Access (OA) journal, and articles are distributed under the terms of the [Creative Commons Attribution-NonCommercial-ShareAlike 4.0 License](#), which allows others to remix, tweak, and build upon the work non-commercially, as long as appropriate credit is given and the new creations are licensed under the identical terms.

For reprints contact: [reprint@ipinnovative.com](mailto:reprint@ipinnovative.com)

## 1. Introduction

Lymphangioma is a rare congenital vascular malformation of the head and neck region isolated from the systemic circulation<sup>1</sup> with a benign etiology, and represents approximately 1–3% of all orbital tumors.<sup>2</sup>They have a lymphocytic composition, and might increase in size with episodes of viral infection, that cause progressive proptosis.<sup>2–4</sup> These hamartomas are most commonly present in the pediatric population with afemale preponderance.

The management of this lymphangioma is controversial and depends on the clinical presentation. The treatment options include partial surgical resection of the major cyst, needle aspiration, surgical debulking, systemic steroids, sildenafil, intralesional injection of the sclerosing agents, and local radiotherapy.<sup>5–7</sup>

A 16 year old female resident of Arunachal Pradesh presented with the complaints of forward protrusionof left eye for 1 year and diminution of vision since 4 months with V/A 6/6 R/E, 4/60, L/E, that were insidious in onset and

gradually progressive in nature, not associated with pain. There is history of trauma to the left eye by friend's foot 12 months back.

On examination, abaxial proptosis of around 15mm with inferior dystopia was present in left eye with restriction of extraocular movments in all directions. However soft cystic palpable periorbital cystic changes were present superolaterally. BCVA was 6/12 with +5.00DS. Lagophthalmos of around 0.5mm was present along/with mild congestion of conjunctiva. Superficial punctate keratopathy was present in inferior part of cornea from around 5 to 7 clock position. Pupils were sluggishly reactive. Intraocular pressure was within normal limits.

Fundus examination revealed clear media with blurring of disc margin along with disc elevation of around 1DD, cup disc ratio being 0.3, tortuous blood vessels and macular striations. USG B- Scan showed a homogenous opacity of around 14\*14mm size posterior to globe pressing it anteriorly with no retinal detachment.

CT Scan Orbit revealed an intraconal retrobulbar non enhancing fusiform hyperdense lobulated lesion with cystic areas reaching upto the orbital apex causing displacement

\* Corresponding author.

E-mail address: [drraisatandon@gmail.com](mailto:drraisatandon@gmail.com) (R. Tandon).

of extraocular muscles and optic nerve that was found to be lymphangioma of orbit. The patient was referred to a higher centre for treatment. However due to her exams and unavoidable covid circumstances patient didn't go for the treatment and was lost to follow up.

After 7 months of follow up and repeated counselling she was sent for treatment where she had received intralesional (0.5mg/kg where 1unit=1mg, here rarely exceeding 10 units) along

Till now she has received 3 intralesional injections of Bleomycin at an interval of 3 weeks which showed considerable amount of ocular improvement in vision to 6/36 in left eye and regression of the tumor upto 5mm. She is still on regular follow up.

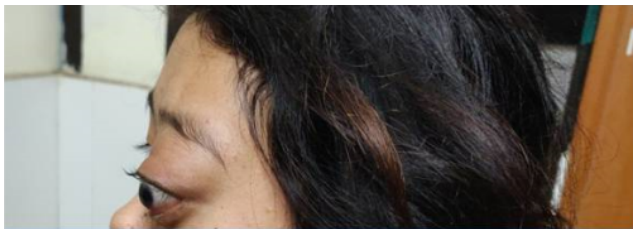


Fig. 1:

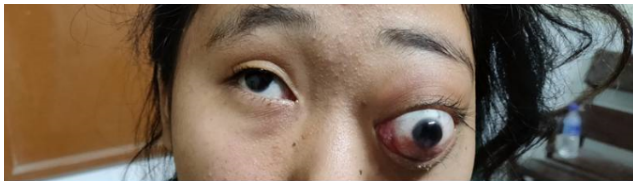


Fig. 2:

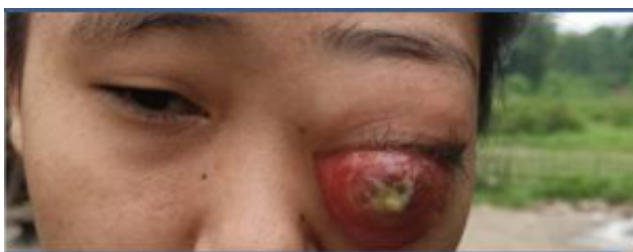


Fig. 3:

## 2. Discussion

It has been observed that some patients with orbital lymphangioma may develop proptosis, either slowly as the mass invades the orbit or suddenly during the hemorrhage of a lesion.<sup>8</sup> In childhood, the diagnosis is often made when proptosis occurs either after bleeding as a result of some minor trauma or upper respiratory infection, and may even

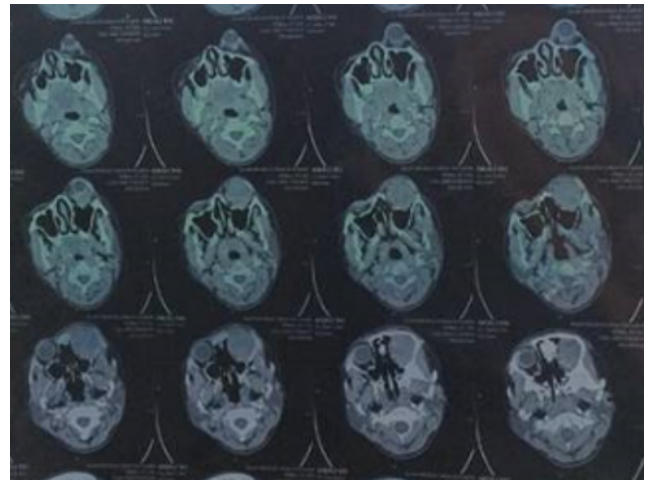


Fig. 4:

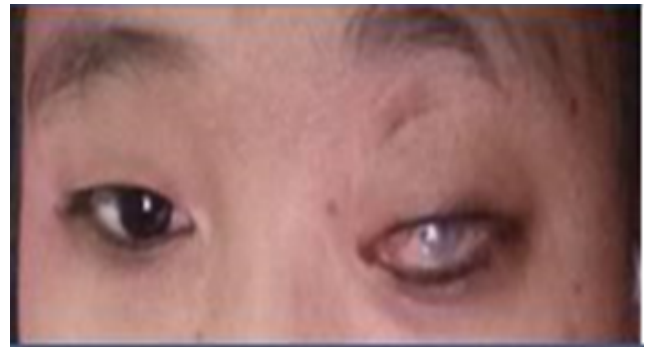

Fig. 5:

sometimes occur spontaneously. In this case the patient had a history of trauma by friend's foot one year back after which forward bulging of eye commenced.

Lymphangiomas can also infiltrate diffusely into surrounding vital structures such as the optic nerve and this feature, along with the associated hemorrhage, presents many surgical challenges and renders management of orbital lymphangiomas very difficult. Various methods have been used to treat orbital lymphangioma, including systemic corticosteroids, injection of a sclerosant, and surgical excision, but currently, there are no definitive curative treatments.<sup>9</sup>

Orbital lymphangioma that is not threatening to vision can be medically treated with oral corticosteroids has been suggested that aspiration of blood, intralesional injection of a sclerosant, and appropriate drainage to maintain continuous negative pressure are only necessary for patients that have threatened vision.

Bleomycin is a sclerosing agent. In 1966, Umezawa<sup>10</sup> first isolated bleomycin as an anti-tumour, anti-viral and anti-bacterial agent. This was first isolated from the soil fungus *Streptomyces verticillus*. The main biochemical

action of bleomycin is inhibition of DNA synthesis. It has also a sclerosing effect on the vascular endothelium, which has been described in treating vascular anomalies. Additionally, in cases of orbital lymphangioma that are associated with organized hematoma, partial resection can be considered as a choice to debulk the mass.

### 3. Acknowledgement

I would like to thank God, my family and friends and my respected teachers and seniors, my lovely juniors for their constant support and guidance.

### 4. Conflict of Interest

The authors declare that there are no conflicts of interest in this paper.

### 5. Source of Funding

None.

### References

1. Wright JE, Sullivan TJ, Garner A, Wulc AE, Moseley IF. Orbital venous anomalies. *Ophthalmology*. 1997;104(6):905–13.
2. Guinto G, Guinto-Nishimura Y. Orbital lymphangiomas. *World Neurosurg*. 2014;81(5-6):708–9.
3. Seregard S, Sahlin S. Panorama of orbital space-occupying lesions. The 24-year experience of a referral centre. *Acta Ophthalmol Scand*. 1999;77(1):91–8.
4. Roman A, Bianchini L, Battistel B, Neto MF, Schwingel D. Orbital Lymphangioma: Case Report and Management Paradigms. *Arq Bras de Neurocirurgia: Braz Neurosurg*. 2017;36(2):136–40.
5. Swetman GL, Berk DR, Vasawala SS, Feinstein JA, Lane AT, Bruckner AL, et al. Sildenafil for severe lymphatic malformations. *N Engl J Med*. 2012;366(4):384–6.
6. Sekhar LN, Tariq F. Orbital lymphangiomas: surgical treatment and clinical outcome. *World Neurosurg*. 2014;81(5-6):710–11.
7. Nassiri N, Rootman J, Rootman DB, Goldberg RA. Orbital lymphaticovenous malformations: current and future treatments. *Survey Ophthalmol*. 2015;60(5):383–405.
8. Russin JJ, Rangel-Castilla L, Kalani MYS, Spetzler RF. Surgical management, outcomes, and recurrence rate of orbital lymphangiomas. *J Clin Neurosci*. 2015;22(5):877–82.
9. Boulos PR, Harissi-Dagher M, Kavalec C, Hardy I, Codère F. Intralesional injection of Tisseel fibrin glue for resection of lymphangiomas and other thin-walled orbital cysts. *Ophthalmic Plast Reconstr Surg*. 2005;21(3):171–6.
10. Umezawa H. Recent study on biochemistry and action of Bleomycin. New York (NY): Academic Press; 1978. p. 15–20.

### Author biography

**Raisa Tandon**, Senior Resident

**Deepanjan Ghosh**, Registrar

**Suchita Singh**, Post Graduate Student

**Anjani Agarwalla**, Post Graduate Student

**Cite this article:** Tandon R, Ghosh D, Singh S, Agarwalla A. Orbital lymphangioma: A rare case report. *IP Int J Ocul Oncol Oculoplasty* 2021;7(3):309-311.